



## Collaborative Review – Penile Cancer

# Lymphadenectomy in the Surgical Management of Penile Cancer

Chris Protzel<sup>a,\*</sup>, Antonio Alcaraz<sup>b</sup>, Simon Horenblas<sup>c</sup>, Giorgio Pizzocaro<sup>d</sup>,  
Alexandre Zlotta<sup>e</sup>, Oliver W. Hakenberg<sup>a</sup>

<sup>a</sup>Department of Urology, University of Rostock, Rostock, Germany

<sup>b</sup>Department of Urology, University of Barcelona, Barcelona, Spain

<sup>c</sup>Department of Urology, Netherlands Cancer Institute – Antoni van Leeuwenhoek Hospital, Amsterdam, The Netherlands

<sup>d</sup>Department of Urology, Alma Universitas Mediolani, Milan, Italy

<sup>e</sup>Division of Urology, Department of Surgical Oncology, University of Toronto, Toronto, Canada

### Article info

#### Article history:

Accepted February 13, 2009

Published online ahead of  
print on February 23, 2009

#### Keywords:

Penile carcinoma  
Lymphadenectomy  
Lymph node metastases  
Recurrence

**EU \* ACME**

[www.eu-acme.org/](http://www.eu-acme.org/)  
[europeanurology](http://europeanurology.com)

Please visit

[www.eu-acme.org/  
europeanurology](http://www.eu-acme.org/europeanurology) to read and  
answer questions on-line.  
The EU-ACME credits will  
then be attributed  
automatically.

### Abstract

**Context:** Uncertainty remains about the extent and indications for inguinal lymphadenectomy in penile cancer, a procedure known for relatively high morbidity. Several attempts have been made to develop strategies which can improve the diagnostic quality and reduce the morbidity of the management of inguinal lymph nodes in penile cancer.

**Objective:** To analyse the existing published data on the surgical management of inguinal nodes in penile cancer regarding morbidity and survival.

**Evidence acquisition:** A Medline search was performed of the English-language literature (1966–September 2008) using the MeSH terms *penile carcinoma*, *lymph node dissection*, *lymphadenectomy*, and *complications*.

**Evidence synthesis:** Lymph node metastases are frequent in penile cancer, even in early pT1G2 stages. Since the results of systemic treatment of advanced penile cancer are disappointing, complete dissection of all involved lymph nodes is highly recommended. The extent of lymph node dissection should be adapted to clinical stage, as this corresponds to metastatic spread. For low-risk patients (pT1s, pT1a, and pT1G1) without palpable lymph nodes and with good compliance, a surveillance strategy may be chosen. For all other patients without palpable lymph nodes (including intermediate risk pT1G2 disease), a modified bilateral lymphadenectomy is recommended. An alternative to this is a dynamic sentinel lymph node biopsy in specialised centres. All patients with histologically proven lymph node metastases should undergo radical inguinal lymphadenectomy. Pelvic lymph node dissection should be done in all patients with more than two metastatic inguinal lymph nodes. In case of fixed inguinal lymph nodes, neoadjuvant chemotherapy is recommended, followed by node resection.

**Conclusions:** Lymphadenectomy is an integral part of the management of penile cancer, since early dissection of involved lymph nodes improves survival.

© 2009 Published by Elsevier B.V. on behalf of European Association of Urology.

\* Corresponding author. Department of Urology, Ernst-Heydemann-Str.  
6, D-18055 Rostock, Germany.

E-mail address: [chris.protzel@med.uni-rostock.de](mailto:chris.protzel@med.uni-rostock.de) (C. Protzel).

## 1. Introduction

Penile carcinoma is rare in Europe and North America, with an incidence of 0.1–0.9 new cases per 100 000 males per year [1]. For this reason and because only a minority of cases are systematically evaluated and published, only very limited data are available to help us assess the value of the available staging procedures, the primary surgical management, and the chemotherapy of metastatic and systemic disease. Most of the available data derive from single-centre retrospective series with low numbers of patients.

Yet metastatic penile carcinoma has an extremely poor prognosis, since reported results of systemic therapy have been disappointing [2], even if they are improving [3]. Therefore, every attempt must be made to treat patients at an early stage. Since curative treatment for patients with localised disease and those with limited, locoregional lymphatic spread is primarily surgical, this treatment, by necessity, is mutilating [4]. Furthermore, regional lymphadenectomy is prone to complications [5]. Therefore, various attempts have been made in recent years to reduce the morbidity related to primary surgical treatment by penis-preserving treatment modalities that are applicable in early stages and by limiting the morbidity of surgical lymph node dissection by either reducing the extent of lymphadenectomy or by selecting only patients for lymphadenectomy who are most likely to benefit from it.

The indications for limited or extensive lymphadenectomy and their respective benefits remain a matter of controversy. In penile cancer, lymph node metastases are the main known variable affecting patient survival [4]. Clinically, lymph node spread is often not detectable, and in patients with limited lymph node disease (ie, with one or two inguinal nodes affected), surgery alone achieves cure in around 75% of cases [4]. Thus, it may be argued that lymphadenectomy should be undertaken in all patients with penile cancer [4,6]. This argument, however, represents overtreatment with potential treatment-related morbidity in a sizeable proportion of patients with clinically node-negative status [7,8]. This controversy is the heart of the matter, and there are good arguments made by both supporters and critics of lymphadenectomy in penile carcinoma. The aim of this review is to examine the current scientific basis of this controversy.

## 2. Evidence acquisition

A Medline search was performed of the English language literature (January 1966–September 2008)

using the MeSH terms *penile carcinoma*, *lymph node dissection*, *lymphadenectomy*, and *complications*. Bibliographies of relevant articles, guidelines, and urologic textbooks also were used to identify relevant publications. These references were used as the basis for this review. Items were classified according to relevance and originality. All publications reporting original data concerning the technique, morbidity, complications, and functional and oncologic outcomes of inguinal lymphadenectomy in penile cancer were included ( $n = 77$ ). These publications and their data were used for the compilation of the information presented in the tables of this paper and as a basis for interactive completion of this collaborative review by all coauthors. The main focus of the review was to assess the published evidence on different modes of surgical inguinal lymph node staging regarding treatment efficacy and morbidity. For this purpose, only studies with exact information on the surgical technique were included ( $n = 22$ ). Additional references on inguinal surgical anatomy and inguinal metastatic lymph node diagnosis also were included.

Generally, the level of evidence was low for all of the studies published, as most were retrospective series (level 4). There were no randomised prospective studies at all. Only one study reached evidence level 3 (prospective comparative study of early vs delayed inguinal lymphadenectomy [9]). Fifteen studies reported a prospective design.

Due to the low evidence level, we did not attempt to weigh the evidence. Weighing the evidence might have introduced several sources of bias. It is tempting, for example, to consider larger series of comparable evidence levels to be more important than smaller series, but the larger series of this rare disease often span a considerable time period of many years. This factor in itself may represent a significant source of bias, as standards often change with time. Additionally, the lack of randomised trials in the field of penile cancer clearly is due to its relative rarity.

## 3. Evidence synthesis

### 3.1. Lymphatic spread in penile cancer

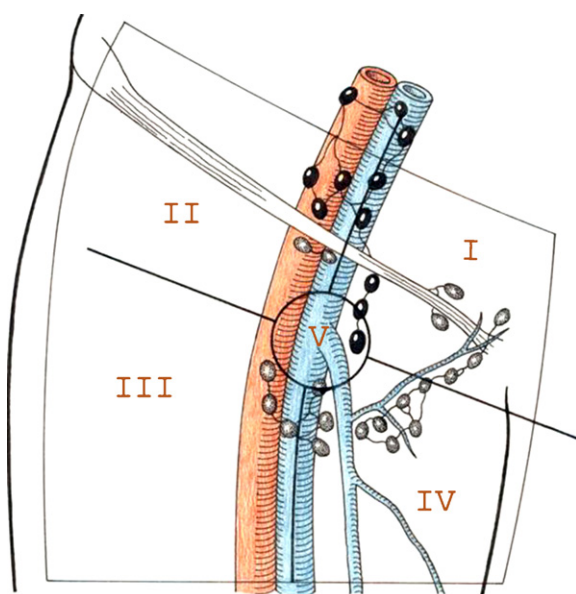
The regional lymph nodes of the penis, which, anatomically, are traditionally divided into the superficial and the deep groups, are located in the inguinal region. The superficial nodes are located under the subcutaneous fascia and above the fascia lata, with up to 25 nodes situated on the muscles of the upper thigh in Scarpa's triangle. The anatomically

**Table 1 – Frequency of lymph node metastases (percent) in penile cancer by grade and stage, as reported in the literature**

Reference	Patients, n	Ta, T1	T2	T3	T4	G1	G2	G3
Ornellas et al [6]	350	18	46	64	50	–	–	–
Horenblas et al [78]	102	14		52		29	46	82
Narayana et al [79]	117	10		56		–	–	–
Solsona et al [80]	66	4	64			19	65	85
Lopes et al [17]	145	50	55	53	29	47.5	64	67
Ficarra et al [9]	175	11	20		64	9		29
Naumann et al [18]	20	50	–	–	–	–	50	–

largest and most constantly found inguinal lymph node is Cloquet's (or Rosenmüller's) node, located at the medial side of the femoral vein, marking the transition between inguinal and pelvic regions. The deep nodes lie in the region of the fossa ovalis where the greater saphenous vein drains into the femoral vein through an opening in the fascia lata. Superficial and deep inguinal nodes are considered to be the first draining nodes of the penis; from there, lymphatic drainage is to the so-called *second-line* regional nodes, which are those in the pelvis around the iliac vessels and in the obturator fossa.

Traditionally, the inguinal region is divided into four sections by a horizontal and a vertical line drawn through the fossa ovalis. According to Daseler et al [10], the superficial group is divided into five anatomical subgroups with the central zone being located at the confluence of the greater saphenous vein and the femoral vein. The four other zones are described as lateral superior, lateral inferior, medial superior, and medial inferior (Fig. 1). In penile cancer,



**Fig. 1 – Lymph drainage regions of the inguino-femoral region according to Daseler et al [10]. The region is divided into five zones: one central zone (V), superior (I) and inferior (IV) medial zones, and superior (II) and inferior (III) lateral zones.**

most metastatically involved nodes are found in the upper and medial sections of the traditional four-section template (ie, the medial superior group of Daseler). Matters are complicated by the fact that penile lymphatic drainage in patients with penile cancer is to both inguinal sides in up to 81% of cases [11–13]. Recently, using single photon emission computed tomography–computed tomography (SPECT-CT) imaging, lymphatic drainage was examined in 50 clinically node-negative penile cancer patients, and sentinel (first-drainage) nodes were identified only in the superior and central zones of the inguinal region [14].

The lymphatic spread observed in penile cancer is thought to follow specific rules [15]. This concept is based on several assumptions. The first assumption is that penile cancer, like other squamous cell carcinomas, has a tendency for locoregional growth and that extensive lymphatic spread always precedes haematogenous spread [15]. The second assumption is that metastatic cells of penile cancer migrate only according to the anatomic lymphatic drainage described above and that skip lesions do not occur [14]. The third assumption is that in penile cancer, regional lymphatic spread does not signify systemic disease, as retroperitoneal and pulmonary metastases are very rare [16]. While clinical observations seem to support this concept, it should be remembered that the underlying theories are assumptions. It is also assumed that crossover of lymphatic spread in penile cancer from one pelvic side to the other does not occur, since it has not been reported.

### 3.2. Incidence of lymph node metastases in penile cancer

Several studies have reported that in penile cancer, lymphatic spread is related to tumour grade, local disease stage, and the type of local tumour present [8,15,17]. The reported rates of lymph node disease detected for stage and grade are given in Table 1. Clearly, there is a strong correlation of lymph node metastasis with the increase of clinical grade (0–29% in grade 1 vs 33–50% in grade 3). Similarly, there is a strong increase in the rate of lymph node

metastases with increasing local stage, with 50–100% node-positive cases in pT3/pT4 cases and 50–70% in pT2 disease. For pT1 disease, very variable rates of node-positive disease have been reported, depending on the staging approach used (Table 1). Unfortunately, there is little clear information about the incidence of lymph node metastases in pT1G2 penile cancer (intermediate risk). Naumann et al [18] reported an incidence of 50% in 20 patients (the largest series of pT1G2 cases reported), and two other studies report an incidence of 44% [29,35].

### 3.3. The prognostic significance of inguinal lymph node disease

The presence and the extent of inguinal lymph node metastasis are the most important factors for the prognosis of the patient with penile cancer. Regional lymphatic spread of penile cancer generally signifies a worse prognosis, whereby pelvic nodal involvement is more menacing than inguinal node involvement. In patients with positive inguinal nodes, prognostic factors for pelvic nodal involvement are the number of inguinal nodes involved (odds ratio [OR] for two or more nodes: 12) and the tumour grade of the involved inguinal nodes (OR: 6) [21]. Extracapsular growth in metastatic nodes, bilateral inguinal node metastases, and pelvic node disease are independent prognostic factors for disease-specific survival [21]. Cancer-specific 3-yr survival in inguinal node-negative and pN1 patients is almost 100% and is reduced to 73% in pN2 node-positive patients [22]. To improve the prognostic value of the TNM classification, Leijte and Horenblas have proposed a new definition of the N-category, taking into account *fixed lymph nodes* as a separate entity [23].

### 3.4. Prognostic parameters for lymph node metastases

#### 3.4.1. Clinical parameters

Since the freely available histopathologic parameters of the primary tumour (pT stage, grade, depth of invasion, and histologic subtype) have shown contradictory results regarding the prognosis of lymph node spread, especially concerning pT stage and grade [24,25], other prognostic parameters available from the primary tumour tissue have been taken into consideration. Thus, lymphovascular and vascular invasion in the tumour were reported to predict lymph node metastases [9,25]. The reliability of this prediction, however, has not been confirmed and was contradicted for lymphovascular invasion by another study [26].

In the era of the widespread use of nomograms, a risk scoring system and a nomogram attempting to

predict lymphatic disease in penile cancer have been proposed. The risk scoring system developed by Solsona et al [27] was modified for the current European Association of Urology (EAU) guidelines [28]. In this score, the intermediate risk group remains under discussion [18]. Ficarra et al developed a nomogram for lymph node involvement in penile cancer [19] which must also be critically discussed, since, according to this nomogram, the risk of metastases for intermediately differentiated and superficially spreading tumours is higher than that for poorly differentiated and vertically growing tumours [29]. Unlike prostate cancer, no large databases with several thousands of patients are available in penile cancer; therefore, the very nature of the disease makes it difficult to devise reliable nomograms.

#### 3.4.2. Molecular parameters

Molecular tissue markers predicting the individual risk of nodal involvement in penile cancer would help to manage patients with clinically benign inguinal node status. A variety of markers have been extensively studied [30–32]. Human papilloma virus (HPV) DNA status has shown conflicting results in several studies [33,34]. For Ki-67, a correlation with local tumour grade and stage has been found but conflicting results regarding node positivity have been reported [20,35,36]. Reduced KAI1/CD82 expression has so far been reported by one study to be predictive of lymph node involvement [32]. Several studies have implicated p53 status as a prognostic factor (better survival and less likelihood of node-positive disease with p53-negative tumours) [37–39]. Serum squamous cell carcinoma antigen levels have failed to show any prognostic significance in penile cancer.

Presently in penile cancer, no tissue parameter is sufficiently validated as a prognostic marker for lymph node involvement (or survival) to be used as a basis for clinical management decisions. In the future, the examination of a panel of several molecular markers (ie, p53 plus KAI1) should be studied in larger series, as this might prove more reliable in predicting individual lymphatic spread.

### 3.5. Diagnosis of lymph node disease

The dilemma is that lymph node disease in penile cancer is clinically diagnosed only in cases with marked lymphatic spread. Minimal lymphatic spread and micrometastatic disease evades clinical diagnosis but remains crucial for the prognosis of each case. Up to 25% of patients with nonpalpable lymph nodes harbour micrometastases [25,29,40].

Patients with palpable inguinal nodes also present uncertainties in that as much as 30–50% of them will not have metastatic disease but inflammatory lymph node swelling secondary to penile cancer. Other patients will have inflammatory swelling of inguinal lymph nodes secondary to intercurrent inflammation of the lower limbs such as pedal fungal disease. This may be particularly true for patients with locally advanced penile cancer, who are often in a state of general physical neglect.

Imaging studies are of no value in the diagnosis of inguinal lymph node metastases. Although metastatic lymph nodes can show typical radiologic signs, common imaging techniques such as computed tomography (CT) scan or conventional magnetic resonance imaging (MRI) are unable to detect micrometastases [41,42]. Nanoparticle-enhanced MRI and positron emission tomography–CT (PET/CT) have been reported with results considered promising by the respective authors [43–45]. Thus, Tabatabaei et al reported a study with nanoparticle-enhanced MRI [43] with 13 malignant lymph nodes out of a total of 113 lymph nodes, of which only 3 of 13 malignant nodes were MRI-positive by conventional MRI criteria of enlarged size. The reported sensitivity of nanoparticle-enhanced MRI detection was 100% (specificity: 97%) with a positive predictive value of 81.2%. This study, however, is small and is not representative for primary staging, since most of the patients were examined for suspected lymph node recurrence several years after the treatment of the primary tumour. No further data are available for this technique. Scher et al used  $^{18}\text{F}$ -FDG PET/CT and detected 15 of 16 positive lymph nodes in five patients (sensitivity: 80%; specificity: 100%) [44]. In a recent update of the study, PET/CT identified 18 of 21 histologically positive lymph nodes (sensitivity: 75%) [45]. Much larger studies are required to assess such techniques properly.

The most widely studied technique is that of ultrasound-guided fine-needle aspiration cytology [46,47]. Saisorn et al [46] reported sensitivity of 93% and specificity of 91% for palpable lymph nodes. In cases of nonpalpable lymph nodes, only 9 of 23 lymph node metastases (sensitivity: 39%; specificity: 100%) were detected by ultrasound-guided fine-needle aspiration cytology in another study [47]. Clearly, this technique is unreliable in this setting.

### 3.6. Management strategies

#### 3.6.1. Surveillance

In the past, patients with low-stage tumours and clinically unaffected inguinal nodes often have undergone surveillance strategies (ie, follow-up

examinations with exploration of the inguinal region when palpable nodes develop during follow-up). Indeed, the current EAU guidelines still strongly recommend this approach in patients with superficial and well-differentiated tumours: pTis, pTa, pT1G1, and pT1G2 with superficial growth and without vascular invasion [28].

Recent series have clearly demonstrated that survival in patients with pT2/pT3 penile cancer is better with immediate surgical lymph node staging (and subsequent lymphadenectomy, if positive nodes are found). Thus, Lont et al reported a 91% 3-yr disease-specific survival in patients with pT2/pT3 disease managed with dynamic sentinel node staging compared with 79% in a historical series managed by surveillance [48]. The same group reported for pT2/pT3 patients with nodal metastases a 35% disease-specific 3-yr survival for those undergoing late lymphadenectomy after surveillance compared with 84% in patients who underwent early lymphadenectomy and were found to have nodal microscopic disease [26] (level of evidence: 3). Similarly, in the largest retrospective series reported so far (700 patients from two centres), Leijte et al reported a markedly higher risk of recurrence in patients undergoing surveillance management [49]. Clearly, early appropriate surgical staging and management of regional nodes is of vital importance in penile cancer. Thus, surveillance cannot be recommended as a routine practice anymore.

#### 3.6.2. Surgical lymph node staging

The direct histologic examination of inguinal lymph nodes remains the most reliable method of assessing their involvement by metastases. Several approaches exist and vary in extent of lymph node sampling.

**3.6.2.1. Radical inguinal lymphadenectomy.** Radical dissection of the inguinal region is performed from the superior margin of the external ring to the anterior superior iliac spine, laterally from the anterior superior iliac spine extending 20 cm inferiorly, and medially to a line drawn from the pubic tubercle 15 cm downwards (Fig. 2). The long saphenous vein is divided, the anterior aspects of the femoral vessels are dissected, and later the femoral vessels are covered by the sartorius muscle [50]. Thus, the superficial lymph nodes in all five anatomic zones described by Daseler [10] (Fig. 1) and the deep inguinal nodes are dissected.

Significant morbidity has been described. Wound infection, skin necrosis, wound dehiscence, lymphoedema, and lymphocele can occur [4,51] (Table 4).

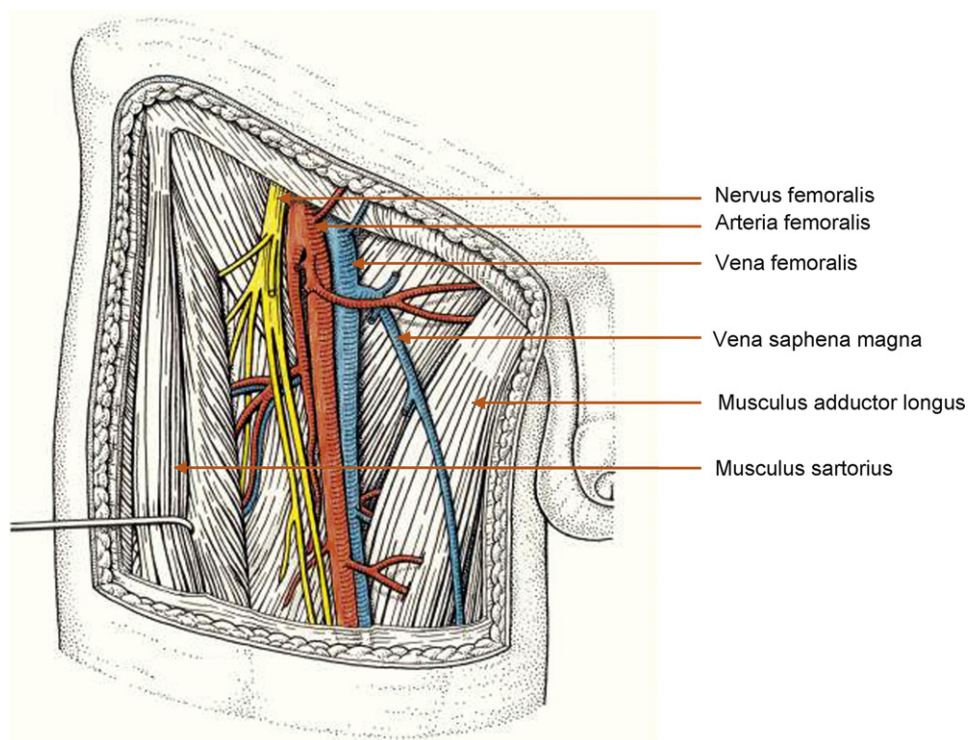


Fig. 2 – Surgical anatomy of the inguofemoral region.

Optimal skin handling and careful dissection of skin flaps is one of the most important aspects in prevention of complications. Skin rotation flaps and myocutaneous flaps are described for primary wound closure for advanced cases [52].

3.6.2.2. *Modified inguinal lymphadenectomy.* Catalona proposed a modified lymphadenectomy to reduce the morbidity and to preserve the therapeutic benefit [53]. The main points are a shorter skin incision and limitation of the dissection (exclusion of the area lateral to the femoral artery and caudal to the fossa ovalis), preservation of the saphenous vein, and no transposition of the sartorius muscle [50,53].

The morbidity of this procedure is reduced compared with radical lymphadenectomy [51,54] (Table 5). The incidence of skin-flap necrosis (2.5%), lymphoedema (3.4%), and deep venous thrombosis (DVT; none) in a group of patients with modified

lymphadenectomy was remarkably decreased in comparison with a historical control group of radical lymphadenectomy (skin necrosis: 8.6%; lymphoedema: 22.4%; DVT: 12%) [54]. For the patients with modified lymphadenectomy, the rate of early complications was 6.8% and the rate of late complications was 3.4% (vs 41.1% and 43.1%, respectively, for the control group with radical lymphadenectomy) [54].

Reducing the field of dissection increases the possibility of false-negative cases. Only a few studies which looked at this aspect of modified inguinal lymphadenectomy with small patient numbers have been reported (Table 2). The high false-negative rate described by Lopes et al [55] has to be discussed in relation to the recent findings concerning lymphatic drainage to the lateral superior zone, which is not dissected in this approach [14]. Current knowledge of lymphatic drainage would suggest that a contemporary modified lymphade-

Table 2 – Oncologic results of modified inguinal lymphadenectomy: false-negative rates and number of recurrences, as reported in the literature

	Patients, n	N+ not detected, n/n patients	False-negative rate, %	Clinical recurrence, n
Parra [81]	12	0/5	0	0
Lopes et al [55]	13	2/2	100	2 (retrocruial)
Colberg et al [82]	9	0/3	0	0
Coblentz and Theodorescu [83]	11	0/5	0	0
D'Ancona et al [84]	18	2/10	20	2 (1 extraregional)

**Table 3 – Oncologic results of dynamic sentinel node biopsy in penile cancer: false-negative rates and recurrences, as reported in the literature**

	Patients, n	N+ not detected, n/n patients	False-negative rate, %	Clinical recurrence, n
Horenblas et al [12]	55	1/12	8	1
Wawroschek et al [85]	3	0/0	0	0
Tanis et al [59]	88	5/23	22	5
Kroon et al [60]	123	6/34	18	6
Perdona et al [72]	22	3/11	18	NR
Spiess et al [86]	31	2/8	25	NR
Leijte et al [29]	92	5/26 groins	18	5
Leitje et al [77]	58	1/21 groins	5	1
Gonzaga-Silva et al [87]	27	3/4	75	3
Hernandez-Toris et al [88]	9	1/2	50	NR
Hadway et al [89]	75	1/19	5	NR

NR = not reported.

nectomy should dissect the central and superior zones of the inguinal region.

**3.6.2.3. Sentinel node biopsy.** The procedure of sentinel lymph node dissection in penile carcinoma was initially described by Cabanas after a study of lymphangiograms and anatomic dissections [11]. Cabanas' concept of static sentinel lymph node, however, was abandoned due to high false-negative rates [56].

The technique of dynamic sentinel node biopsy (DSNB) was developed for penile cancer following concepts developed in breast cancer and melanoma [12,57,58]. It is based on the identification of the lymph node in the individual patient which is the first drainage node (ie, the sentinel node). The concept assumes that there is a stepwise and orderly progression of lymphatic metastatic spread from the primarily involved node (the sentinel node) to secondary lymph nodes. More than one sentinel node can be involved. For identification of the sentinel node, technetium-99m nanocolloid is injected around the penile tumour intradermally 1 d before surgery. Additionally, shortly before the operation, 1 ml of patent blue dye is injected intradermally. Lymphoscintigraphy will identify the approximate location of the sentinel node, and

the area is marked on the skin. With dissection, the sentinel lymph nodes are detected intraoperatively by lymphoscintigraphic imaging with a gamma-ray detection probe and patent blue dye staining. They are then isolated and removed. In case of positive findings on either frozen section or definitive histology, a formal inguinal lymphadenectomy is performed.

The technique has been extensively studied by only a few specialised centres. The group from the Netherlands Cancer Institute has repeatedly updated and published their results. They initially reported a high false-negative rate of 17–22% [13,59,60] but developed modifications of the technique and, subsequently, were able to report a markedly reduced false-negative rate of 4.8% [29]. The same group also stresses the effect of a learning curve to achieve reliable results with DSNB. This technique was advocated only for centres that perform at least 20 procedures per year [61].

**3.6.2.4. Video endoscopic lymphadenectomy.** This recently described technique is derived from laparoscopic surgery and has been evaluated only in small pilot studies [62–64]. It seems to carry a lower risk of skin complications but a higher risk of lymphocele formation (23%) compared with an open approach;

**Table 4 – Reported morbidities of radical inguinal lymphadenectomy**

	n	Skin, %	Infection, %	DVT, %	Seroma, (%)	Edema, %	Lymphocele, %	Total patients with complications, %	
								Major	Minor
Ravi [52]	234	61	18	–	5	–	–	–	–
Bevan-Thomas et al [51]	28	14.2	14.2	0	10.7	14.2	3.6	21	54
Nelson et al [71]	22	7.5	7.5	–	–	–	2.5	5	45
Bouchot et al [54]	58	8.6	6.9	12.1	13.8	22.4	5.2	31	–
Perdona et al [72]	48	8.3	8.3	8.3	12.5	20.8	4.2	37.5	47.5

DVT = deep venous thrombosis.

**Table 5 – Reported morbidity of modified inguinal lymphadenectomy**

	n	Skin, %	Infection, %	DVT, %	Seroma, %	Edema, %	Lymphocele, %	Total patients with complications, %	
								Major	Minor
Bevan-Thomas et al [51]	66	4.5	6.1	0	12.1	3.0	0	14	33
Jacobellis [90]	10	0	0	0	–	20	30	–	–
Bouchot et al [54]	118	2.5	0.8	0	–	3.4	0	0	6.8
D'Ancona et al [84]	26	–	–	–	26.3	–	–	0	36.8
Milathianakis et al [91]	7	–	14.2	–	–	–	–	0	14.2

DVT = deep venous thrombosis.

**Table 6 – Reported morbidity of dynamic sentinel node biopsy**

	n	Skin, %	Infection, %	DVT, %	Seroma, %	Edema, %	Lymphocele, %	Total patients with complications, %	
								Major	Minor
Perdona et al [72]	22	0	4.5	0	–	–	–	0	13.6
Hadway et al [89]	75	–	2.6	0	1.3	1.3	–	1.3	6.6
Leijte et al [29]	92	2.2	8.7	0	–	1.1	4.3	0	17.4
Leijte et al [77]	58	0	6.9	0	–	1.7	1.7	0	10.3
Heyns and Theron [92]	23	13	13	–	–	–	21.7	–	39

DVT = deep venous thrombosis.

the reported overall complication rate was 23% [63]. An assessment of this technique for its reliability is not yet possible.

### 3.7. The role of pelvic lymphadenectomy

Cabanas [11] and Leijte et al [14] did not detect direct lymphatic drainage to pelvic lymph nodes from penile cancer. Thus, in cases of uninvolved inguinal nodes, pelvic lymphadenectomy is not warranted. Predictors for potential involvement of pelvic nodes in patients with involved inguinal nodes are the number of positive inguinal lymph nodes and extracapsular extent of metastatic disease in involved nodes [21]. Thus, pelvic lymphadenectomy may be necessary as a secondary procedure and can be performed extraperitoneally by a midline suprapubic incision. Since the rate of positive pelvic nodes has been reported to be 23% in cases with more than two positive inguinal nodes and 56% for more than three inguinal nodes involved [6,16,65], pelvic lymphadenectomy is recommended if two or more inguinal nodes are involved and/or if extracapsular extent in inguinal nodes is seen. If very aggressive histologic subtypes of penile cancer are present (ie, basaloid subtype) or if strong expression of p53 is found, a pelvic lymph node dissection should be considered if any inguinal node is involved [66].

There is no clear evidence as to whether in cases with unilateral extensive inguinal lymph node disease (two or more nodes involved) the ensuing

pelvic lymphadenectomy should be bilateral or should be restricted to the ipsilateral side only. A single midline incision is appropriate for unilateral and for bilateral dissection. Whether or not pelvic lymphadenectomy should be done during the same procedure with inguinal lymphadenectomy remains unclear and must be left to clinical judgement; there are no data on this at all. It may be surmised that potential morbidity will increase with an extension of the procedure; however, this must be weighed against the risk of several procedures and anaesthetic manipulations.

### 3.8. Morbidity of lymphadenectomy

Surgical morbidity is a significant problem after radical inguinal lymphadenectomy (Tables 3 and 4). Wound infection, skin necrosis, wound dehiscence, and lymphocele have been reported in a high proportion of cases [4,51,67,68]. This has led to modified approaches and the development of new techniques.

It is questionable, however, whether the morbidity reported for radical inguinal lymphadenectomy is as high today as has been reported by historical series [52,69]. Improved intra- and postoperative management with better knowledge of the potential complications may contribute to a reduction of morbidity. Certainly, the technique of modified inguinal lymphadenectomy has resulted in a markedly decreased rate of complications (Table 5; in a



recent series, 6.8% early and 3.4% late complications [54]). In the study by Bouchot et al, only 8 of 118 patients suffered any complications and those were minor [54]. However, the oncological results of this series have not been reported.

Undoubtedly, inguinal lymphadenectomy remains a procedure that is prone to local complications and should be performed with care and diligent tissue handling. The prophylactic application of antibiotics is recommended [4,70]. There is a clear need for vacuum drains, but there are no clear rules for the duration of drainage [4,70]. Elastic stockings and/or pneumatic stockings should be used to reduce the chance of marked lower-limb lymphoedema. Whether early ambulation and post-operative anticoagulation are useful or detrimental is controversial and depends on the school of thought of the respective authors [4,71]. A recent review of management techniques for minimising complications with lymphadenectomy was given by Spiess et al [5].

DSNB is a procedure with low invasiveness (Table 6). Reported complications rates of around 14-15% [13,72] compare favourably with those of

radical inguinal lymphadenectomy in historical series. In their most recent series, Leijte et al report a complication rate of only 5.7% [29]. Perdoni et al compared early complications (mostly seroma) in 40% and late complications (mostly lymphoedema) in 47% of patients following radical inguinal lymphadenectomy in a historical control series with 14% early complications in DSNB in a more recent series [72]. The potential advantage of reduced morbidity with DSNB seems less pronounced in comparison with modified inguinal lymphadenectomy (Tables 5 and 6). A prospective controlled comparison between DSNB and modified or radical inguinal lymphadenectomy has never been done.

3.9. Clinical approach to different patient groups according to current guidelines

Three clinical groups must be distinguished: those with clinically normal inguinal nodes, those with palpably enlarged nodes, and those with enlarged and fixed nodes (Fig. 3). Patients with enlarged and fixed nodes will always have metastatic disease, whereas patients with just enlarged nodes will

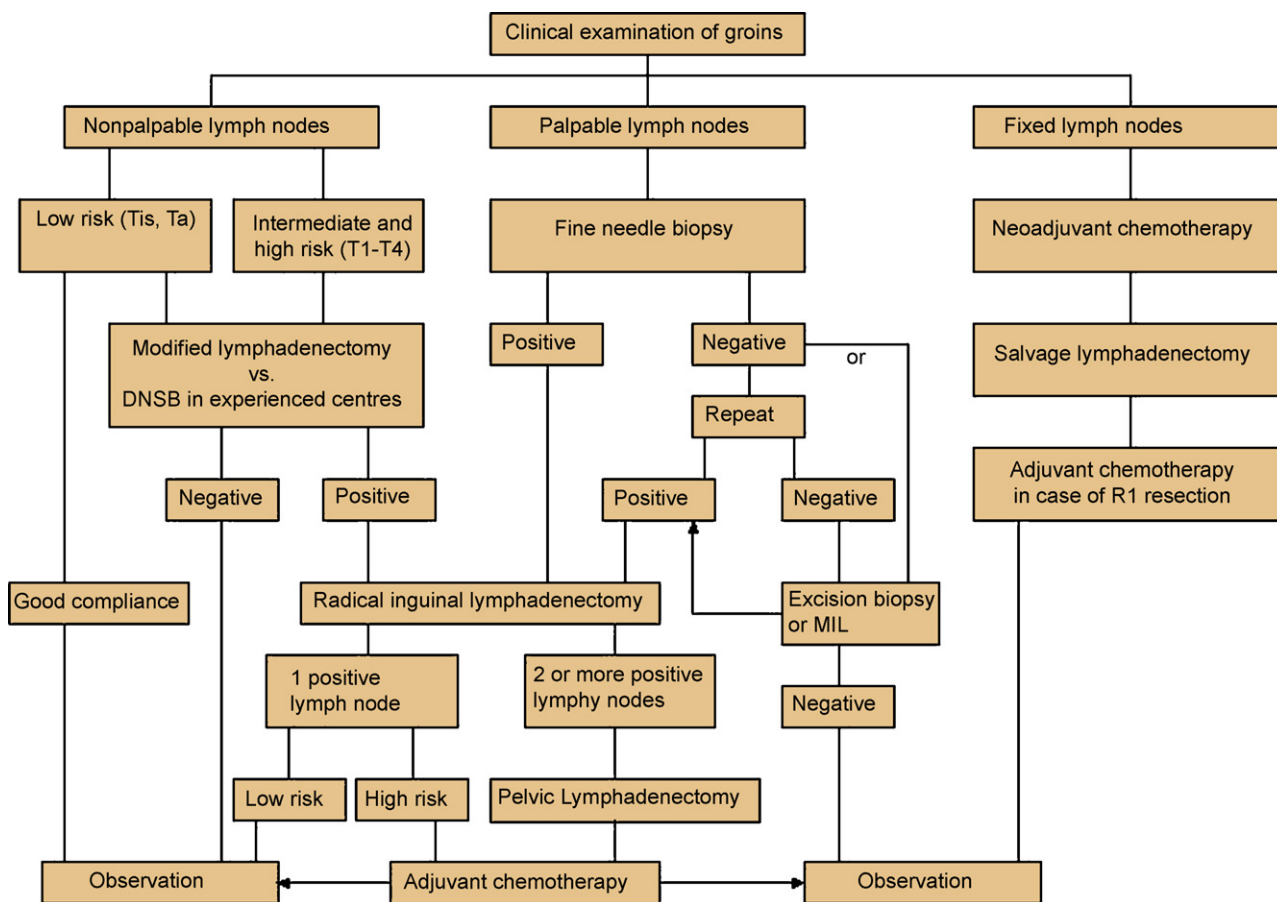


Fig. 3 – Work flow for the management of penile cancer patients regarding the inguinal lymph nodes based on this review. MIL = modified inguinal lymphadenectomy.

harbour metastases in a variable but large proportion. The most controversial group is that with clinically unaffected nodes in whom micrometastatic involvement may be present.

### 3.9.1. Patients with nonpalpable inguinal lymph nodes

It has been well documented that radical inguinal lymphadenectomy for all patients with nonpalpable lymph nodes results in overtreatment in >75% of cases. Most experts agree that radical bilateral lymphadenectomy is not warranted in these patients.

The current EAU guidelines, which were last updated in 2004 [28], still recommend surveillance of patients with good compliance for follow-up who are considered to be at low risk based on pathologic factors of tumour stage (pTis, pTaG1 and G2, pT1 G1). This recommendation is based on the assessment of the risk of finding micrometastatic lymph node disease being <17%. Considering that a surveillance strategy decreases tumour-specific survival in this patient group, this recommendation must be questioned. It is a matter of judgment whether a risk of roughly 15% of those harbouring metastatic disease of a potentially deadly disease is a small risk or not. At least the potential risks of a definite worsening of the prognosis in case of regional recurrence must be weighed against the non-life-threatening risks of lymphadenectomy and must be discussed with the patient.

Patients with pT1G2 are considered an intermediate-risk group. Up to 50% of these patients will harbour lymph node metastases [18]; therefore, lymphadenectomy must be recommended. Although the option of a surveillance strategy is also mentioned in the EAU guidelines for this subgroup, this must remain highly controversial, since clinical studies have clearly demonstrated an improved prognosis for penile cancer with early lymphadenectomy [6,26]. The extent of lymphadenectomy in this group of patients, however, may be reduced by using DSNB.

According to the EAU guidelines for high-risk patients (pT2–4 and any stage with G3), a modified lymphadenectomy is recommended. Certainly in cases of locally advanced and undifferentiated cancers (pT3 and G3), bilateral radical lymphadenectomy seems a safe option for management. In centres that are experienced with DSNB, surgical staging is done by DSNB, regardless of risk group.

### 3.9.2. Patients with palpable lymph nodes

In patients with penile cancer, moderately enlarged palpable inguinal nodes which are not fixed may or may not signify metastatic disease. The rate of false-

positive nodes has been reported to amount up to 50% [40], but in more recent series it was down to 30% [22]. A course of antibiotic treatment to reduce lymph node swelling due to potential infection is not recommended anymore, as it has never been shown to safely clarify the nature of lymph node swelling in penile cancer [15,73].

Although ultrasound-guided fine-needle biopsy is an excellent, rapid, and easy way to find evidence of metastatic involvement in palpable nodes, it is only reliable when the biopsy is tumour positive. If the biopsy is negative in such cases, it needs to be repeated or surgical staging needs to be done. As positive needle biopsy results will also be followed by lymphadenectomy, it can be argued that fine-needle biopsy in cases with palpable nodes may not be clinically all that useful.

DSNB is not reliable in this group of patients and should not be advocated [60,74]. In all clinically node-positive patients, early lymphadenectomy should be performed [6,26] and bilateral radical lymphadenectomy is the standard procedure. In case of contralateral nonpalpable lymph nodes, a modified lymph node dissection or DSNB can be considered for the clinically unaffected side.

### 3.9.3. Patients with fixed inguinal lymph nodes

These patients will have advanced and metastatic disease, and many of them will die of penile cancer. The value of neoadjuvant chemotherapy has been advocated in recent reviews [93]. The data supporting this approach come from nine studies of level 4 evidence [75–77]. Since this is the strongest evidence available, there are good arguments to follow it. Patients should be managed by neoadjuvant chemotherapy followed by bilateral radical lymphadenectomy [75–77], as long-term survivors have been described with this approach [77]. The problems remaining are those of the high toxicity of standard chemotherapy protocols and a high number of nonresponders [2].

## 4. Conclusions

Lymphadenectomy remains an integral part of the management of patients with penile cancer, since early inguinal lymphadenectomy improves their prognosis. Efforts should be made to ensure that lymphadenectomy is performed according to current guidelines. Surveillance strategies are no longer generally recommended except in well-informed, low-risk patients. In all other patients with clinically unaffected nodes, lymphadenectomy is a diagnostic staging procedure. DSNB seems adequate for staging

but should be routinely performed only in specialised centres. Otherwise, a modified bilateral lymphadenectomy should be performed for all cases with pT1G2 or more invasive stages with clinically unaffected nodes. Cases with tumour-positive inguinal nodes must undergo radical inguinal lymphadenectomy. If more than two inguinal nodes are metastatically involved, pelvic inguinal lymphadenectomy should be performed.

**Author contributions:** Chris Protzel had full access to all the data in the study and takes responsibility for the integrity of the data and the accuracy of the data analysis.

*Study concept and design:* Hakenberg, Protzel.

*Acquisition of data:* Hakenberg, Protzel.

*Analysis and interpretation of data:* Protzel, Alcaraz, Horenblas, Pizzocaro, Zlotta, Hakenberg.

*Drafting of the manuscript:* Protzel, Alcaraz, Horenblas, Pizzocaro, Zlotta, Hakenberg.

*Critical revision of the manuscript for important intellectual content:* Protzel, Alcaraz, Horenblas, Pizzocaro, Zlotta, Hakenberg.

*Statistical analysis:* None.

*Obtaining funding:* None.

*Administrative, technical, or material support:* None.

*Supervision:* None.

*Other (specify):* None.

**Financial disclosures:** I certify that all conflicts of interest, including specific financial interests and relationships and affiliations relevant to the subject matter or materials discussed in the manuscript (eg, employment/ affiliation, grants or funding, consultancies, honoraria, stock ownership or options, expert testimony, royalties, or patents filed, received, or pending), are the following: None.

**Funding/Support and role of the sponsor:** None.

## References

- [1] Jemal A, Siegel R, Ward E, Murray T, Xu J, Thun MJ. Cancer statistics, 2007. *CA Cancer J Clin* 2007;57:43–66.
- [2] Hakenberg OW, Nippgen JB, Froehner M, Zastrow S, Wirth MP. Cisplatin, methotrexate and bleomycin for treating advanced penile carcinoma. *BJU Int* 2006;98:1225–7.
- [3] Pizzocaro G, Nicolai N, Milani A. Taxanes in combination with cisplatin and fluorouracil for advanced penile cancer: preliminary results. *Eur Urol* 2009;55:546–51.
- [4] Horenblas S. Lymphadenectomy for squamous cell carcinoma of the penis. Part 2: the role and technique of lymph node dissection. *BJU Int* 2001;88:473–83.
- [5] Spiess PE, Hernandez MS, Pettaway CA. Contemporary inguinal lymph node dissection: minimizing complications. *World J Urol*. In press.
- [6] Ornellas AA, Seixas AL, Marota A, Wisnesky A, Campos F, de Moraes JR. Surgical treatment of invasive squamous cell carcinoma of the penis: retrospective analysis of 350 cases. *J Urol* 1994;151:1244–9.
- [7] Naumann CM, Filippow N, Seif C, et al. Penile carcinoma (pT1 G2): surveillance or inguinal lymph node dissection? *Onkologie* 2005;28:135–8.
- [8] Doehn C, Baumgartel M, Jocham D. Surgical therapy of penis carcinoma. *Urologe A* 2001;40:303–7.
- [9] Ficarra V, Zattoni F, Cunico SC, et al. Lymphatic and vascular embolizations are independent predictive variables of inguinal lymph node involvement in patients with squamous cell carcinoma of the penis: Gruppo Uro-Oncologico del Nord Est (Northeast Uro-Oncological Group) Penile Cancer data base data. *Cancer* 2005;103:2507–16.
- [10] Daseler EH, Anson BJ, Reimann AF. Radical excision of the inguinal and iliac lymph glands; a study based upon 450 anatomical dissections and upon supportive clinical observations. *Surg Gynecol Obstet* 1948;87:679–94.
- [11] Cabanas RM. An approach for the treatment of penile carcinoma. *Cancer* 1977;39:456–66.
- [12] Horenblas S, Jansen L, Meinhardt W, Hoefnagel CA, de Jong D, Nieweg OE. Detection of occult metastasis in squamous cell carcinoma of the penis using a dynamic sentinel node procedure. *J Urol* 2000;163:100–4.
- [13] Kroon BK, Horenblas S, Meinhardt W, et al. Dynamic sentinel node biopsy in penile carcinoma: evaluation of 10 years experience. *Eur Urol* 2005;47:601–6, discussion 606.
- [14] Leijte JAP, Valdés Olmos RA, Nieweg OE, Horenblas S. Anatomical mapping of lymphatic drainage in penile carcinoma with SPECT-CT: implications for the extent of inguinal lymph node dissection. *Eur Urol* 2008;54:885–92.
- [15] Horenblas S. Lymphadenectomy for squamous cell carcinoma of the penis. Part 1: diagnosis of lymph node metastasis. *BJU Int* 2001;88:467–72.
- [16] Culkin DJ, Beer TM. Advanced penile carcinoma. *J Urol* 2003;170:359–65.
- [17] Lopes A, Hidalgo GS, Kowalski LP, Torloni H, Rossi BM, Fonseca FP. Prognostic factors in carcinoma of the penis: multivariate analysis of 145 patients treated with amputation and lymphadenectomy. *J Urol* 1996;156:1637–42.
- [18] Naumann CM, Alkatout I, Al-Najar A, et al. Lymph-node metastases in intermediate-risk squamous cell carcinoma of the penis. *BJU Int* 2008;102:1102–6.
- [19] Ficarra V, Zattoni F, Artibani W, et al. Nomogram predictive of pathological inguinal lymph node involvement in patients with squamous cell carcinoma of the penis. *J Urol* 2006;175:1700–4, discussion 1704–5.
- [20] Berdjis N, Meye A, Nippgen J, et al. Expression of Ki-67 in squamous cell carcinoma of the penis. *BJU Int* 2005;96:146–8.
- [21] Lont AP, Kroon BK, Gallee MP, van Tinteren H, Moonen LM, Horenblas S. Pelvic lymph node dissection for penile carcinoma: extent of inguinal lymph node involvement as an indicator for pelvic lymph node involvement and survival. *J Urol* 2007;177:947–52, discussion 952.
- [22] Hegarty PK, Kayes O, Freeman A, Christopher N, Ralph DJ, Minhas S. A prospective study of 100 cases of penile

- cancer managed according to European Association of Urology guidelines. *BJU Int* 2006;98:526-31.
- [23] Leijte JA, Horenblas S. Shortcomings of the current TNM classification for penile carcinoma: time for a change? *World J Urol*. In press.
- [24] Theodorescu D, Russo P, Zhang ZF, Morash C, Fair WR. Outcomes of initial surveillance of invasive squamous cell carcinoma of the penis and negative nodes. *J Urol* 1996;155:1626-31.
- [25] Slaton JW, Morgenstern N, Levy DA, et al. Tumor stage, vascular invasion and the percentage of poorly differentiated cancer: independent prognosticators for inguinal lymph node metastasis in penile squamous cancer. *J Urol* 2001;165:1138-42.
- [26] Kroon BK, Horenblas S, Lont AP, Tanis PJ, Gallee MP, Nieweg OE. Patients with penile carcinoma benefit from immediate resection of clinically occult lymph node metastases. *J Urol* 2005;173:816-9.
- [27] Solsona E, Iborra I, Rubio J, Casanova JL, Ricos JV, Calabuig C. Prospective validation of the association of local tumor stage and grade as a predictive factor for occult lymph node micrometastasis in patients with penile carcinoma and clinically negative inguinal lymph nodes. *J Urol* 2001;165:1506-9.
- [28] Solsona E, Algaba F, Horenblas S, Pizzocaro G, Windahl T. EAU guidelines on penile cancer. *Eur Urol* 2004;46:1-8.
- [29] Leijte JAP, Kroon BK, Valdés Olmos RA, Nieweg OE, Horenblas S. Reliability and safety of current dynamic sentinel node biopsy for penile carcinoma. *Eur Urol* 2007;52:170-7.
- [30] Protzel C, Knoedel J, Wolf E, Kleist B, Poetsch M, Giebel J. Prognostic parameters of penis carcinoma. *Urologe A* 2007;46:1162.
- [31] Kayes O, Ahmed HU, Arya M, Minhas S. Molecular and genetic pathways in penile cancer. *Lancet Oncol* 2007;8:420-9.
- [32] Protzel C, Kakies C, Kleist B, Poetsch M, Giebel J. Down-regulation of the metastasis suppressor protein KAI1/CD82 correlates with occurrence of metastasis, prognosis and presence of HPV DNA in human penile squamous cell carcinoma. *Virchows Arch* 2008;452:369-75.
- [33] Lont AP, Kroon BK, Horenblas S, et al. Presence of high-risk human papillomavirus DNA in penile carcinoma predicts favorable outcome in survival. *Int J Cancer* 2006;119:1078-81.
- [34] Bezerra AL, Lopes A, Santiago GH, Ribeiro KC, Latorre MR, Villa LL. Human papillomavirus as a prognostic factor in carcinoma of the penis: analysis of 82 patients treated with amputation and bilateral lymphadenectomy. *Cancer* 2001;91:2315-21.
- [35] Protzel C, Knoedel J, Zimmermann U, Woenckhaus C, Poetsch M, Giebel J. Expression of proliferation marker Ki67 correlates to occurrence of metastasis and prognosis, histological subtypes and HPV DNA detection in penile carcinomas. *Histol Histopathol* 2007;22:1197-204.
- [36] Guimaraes GC, Leal ML, Campos RS, et al. Do proliferating cell nuclear antigen and MIB-1/Ki-67 have prognostic value in penile squamous cell carcinoma? *Urology* 2007;70:137-42.
- [37] Lopes A, Bezerra AL, Pinto CA, Serrano SV, de Mell OC, Villa LL. p53 as a new prognostic factor for lymph node metastasis in penile carcinoma: analysis of 82 patients treated with amputation and bilateral lymphadenectomy. *J Urol* 2002;168:81-6.
- [38] Martins AC, Faria SM, Cologna AJ, Suaid HJ, Tucci Jr S. Immunoexpression of p53 protein and proliferating cell nuclear antigen in penile carcinoma. *J Urol* 2002;167:89-92, discussion 92-3.
- [39] Zhu Y, Zhou XY, Yao XD, Dai B, Ye DW. The prognostic significance of p53, Ki-67, epithelial cadherin and matrix metalloproteinase-9 in penile squamous cell carcinoma treated with surgery. *BJU Int* 2007;100:204-8.
- [40] Persky L, deKernion J. Carcinoma of the penis. *CA Cancer J Clin* 1986;36:258-73.
- [41] Singh AK, Gonzalez-Torrez P, Kaewlai R, Tabatabaei S, Harisinghani MG. Imaging of penile neoplasm. *Semin Ultrasound CT MR* 2007;28:287-96.
- [42] Mueller-Lisse UG, Scher B, Scherr MK, Seitz M. Functional imaging in penile cancer: PET/computed tomography, MRI, and sentinel lymph node biopsy. *Curr Opin Urol* 2008;18:105-10.
- [43] Tabatabaei S, Harisinghani M, McDougal WS. Regional lymph node staging using lymphotropic nanoparticle enhanced magnetic resonance imaging with ferumoxtran-10 in patients with penile cancer. *J Urol* 2005;174:923-7, discussion 927.
- [44] Scher B, Seitz M, Reiser M, et al. 18F-FDG PET/CT for staging of penile cancer. *J Nucl Med* 2005;46:1460-5.
- [45] Scher B, Seitz M, Albinger W, et al. Value of PET and PET/CT in the diagnostics of prostate and penile cancer. *Recent Results Cancer Res* 2008;170:159-79.
- [46] Saisorn I, Lawrentschuk N, Leewansangtong S, Bolton DM. Fine-needle aspiration cytology predicts inguinal lymph node metastasis without antibiotic pretreatment in penile carcinoma. *BJU Int* 2006;97:1225-8.
- [47] Kroon BK, Horenblas S, Deurloo EE, Nieweg OE, Teertstra HJ. Ultrasonography-guided fine-needle aspiration cytology before sentinel node biopsy in patients with penile carcinoma. *BJU Int* 2005;95:517-21.
- [48] Lont AP, Horenblas S, Tanis PJ, Gallee MP, van Tinteren H, Nieweg OE. Management of clinically node negative penile carcinoma: improved survival after the introduction of dynamic sentinel node biopsy. *J Urol* 2003;170:783-6.
- [49] Leijte JAP, Kirrander P, Antonini N, Windahl T, Horenblas S. Recurrence patterns of squamous cell carcinoma of the penis: recommendations for follow-up based on a two-centre analysis of 700 patients. *Eur Urol* 2008;54:161-9.
- [50] Wein AJ, Kavoussi LR, Novick AC, Partin AW, Peters CA, editors. *Campbell-Walsh Urology*. 9th ed. Philadelphia, PA: Saunders Elsevier; 2007.
- [51] Bevan-Thomas R, Slaton JW, Pettaway CA. Contemporary morbidity from lymphadenectomy for penile squamous cell carcinoma: the M.D. Anderson Cancer Center Experience. *J Urol* 2002;167:1638-42.
- [52] Ravi R. Morbidity following groin dissection for penile carcinoma. *Br J Urol* 1993;72:941-5.

- [53] Catalona WJ. Modified inguinal lymphadenectomy for carcinoma of the penis with preservation of saphenous veins: technique and preliminary results. *J Urol* 1988;140:306–10.
- [54] Bouchot O, Rigaud J, Maillet F, Hetet JF, Karam G. Morbidity of inguinal lymphadenectomy for invasive penile carcinoma. *Eur Urol* 2004;45:761–6, discussion 765–6.
- [55] Lopes A, Rossi BM, Fonseca FP, Morini S. Unreliability of modified inguinal lymphadenectomy for clinical staging of penile carcinoma. *Cancer* 1996;77:2099–102.
- [56] Wespes E, Simon J, Schulman CC. Cabanas approach: is sentinel node biopsy reliable for staging penile carcinoma? *Urology* 1986;28:278–9.
- [57] Allen B, Campbell I, Desai S, Dray M, Scarlet J. Pilot study comparing the accuracy of lymphoscintigraphy sentinel lymph node localisation with axillary node dissection in women with operable breast cancer. *N Z Med J* 2001;114:233–6.
- [58] Statius Muller MG, van Leeuwen PA, Borgstein PJ, Pijpers R, Meijer S. The sentinel node procedure in cutaneous melanoma: an overview of 6 years' experience. *Eur J Nucl Med* 1999;26:S20–5.
- [59] Tanis PJ, Lont AP, Meinhardt W, Olmos RA, Nieweg OE, Horenblas S. Dynamic sentinel node biopsy for penile cancer: reliability of a staging technique. *J Urol* 2002;168:76–80.
- [60] Kroon BK, Horenblas S, Estourgie SH, Lont AP, Valdes Olmos RA, Nieweg OE. How to avoid false-negative dynamic sentinel node procedures in penile carcinoma. *J Urol* 2004;171:2191–4.
- [61] Ficarra V, Galfano A. Should the dynamic sentinel node biopsy (DSNB) be considered the gold standard in the evaluation of lymph node status in patients with penile carcinoma? *Eur Urol* 2007;52:17–9, discussion 20–1.
- [62] Tobias-Machado M, Tavares A, Ornellas AA, Molina Jr WR, Juliano RV, Wroclawski ER. Video endoscopic inguinal lymphadenectomy: a new minimally invasive procedure for radical management of inguinal nodes in patients with penile squamous cell carcinoma. *J Urol* 2007;177:953–7, discussion 958.
- [63] Sotelo R, Sanchez-Salas R, Carmona O, et al. Endoscopic lymphadenectomy for penile carcinoma. *J Endourol* 2007;21:364–7, discussion 367.
- [64] Tobias-Machado M, Tavares A, Silva MN, et al. Can video endoscopic inguinal lymphadenectomy achieve a lower morbidity than open lymph node dissection in penile cancer patients? *J Endourol* 2008;22:1687–91.
- [65] Lopes A, Bezerra AL, Serrano SV, Hidalgo GS. Iliac nodal metastases from carcinoma of the penis treated surgically. *BJU Int* 2000;86:690–3.
- [66] Zhu Y, Zhang SL, Ye DW, Yao XD, Jiang ZX, Zhou XY. Predicting pelvic lymph node metastases in penile cancer patients: a comparison of computed tomography, Cloquet's node, and disease burden of inguinal lymph nodes. *Onkologie* 2008;31:37–41.
- [67] Johnson DE, Lo RK. Management of regional lymph nodes in penile carcinoma. Five-year results following therapeutic groin dissections. *Urology* 1984;24:308–11.
- [68] Hakenberg OW, Wirth MP. Issues in the treatment of penile carcinoma. A short review. *Urol Int* 1999;62:229–33.
- [69] Ornellas AA, Seixas AL, de Moraes JR. Analyses of 200 lymphadenectomies in patients with penile carcinoma. *J Urol* 1991;146:330–2.
- [70] Loughlin KR. Surgical atlas. Surgical management of penile carcinoma: the inguinal nodes. *BJU Int* 2006;97:1125–34.
- [71] Nelson BA, Cookson MS, Smith Jr JA, Chang SS. Complications of inguinal and pelvic lymphadenectomy for squamous cell carcinoma of the penis: a contemporary series. *J Urol* 2004;172:494–7.
- [72] Perdona S, Autorino R, De Sio M, et al. Dynamic sentinel node biopsy in clinically node-negative penile cancer versus radical inguinal lymphadenectomy: a comparative study. *Urology* 2005;66:1282–6.
- [73] Preis E, Jakse G. The significance of inguinal lymphadenectomy in carcinoma of the penis. *Urologe A* 2006;45:176–80.
- [74] Hungerhuber E, Schlenker B, Frimberger D, et al. Lymphoscintigraphy in penile cancer: limited value of sentinel node biopsy in patients with clinically suspicious lymph nodes. *World J Urol* 2006;24:319–24.
- [75] Pizzocaro G, Piva L. Adjuvant and neoadjuvant vincristine, bleomycin, and methotrexate for inguinal metastases from squamous cell carcinoma of the penis. *Acta Oncol* 1988;27:823–4.
- [76] Bermejo C, Busby JE, Spiess PE, Heller L, Pagliaro LC, Pettaway CA. Neoadjuvant chemotherapy followed by aggressive surgical consolidation for metastatic penile squamous cell carcinoma. *J Urol* 2007;177:1335–8.
- [77] Leijte JAP, Kerst JM, Bais E, Antonini N, Horenblas S. Neoadjuvant chemotherapy in advanced penile carcinoma. *Eur Urol* 2007;52:488–94.
- [78] Horenblas S, van Tinteren H, Delemarre JF, Moonen LM, Lustig V, van Waardenburg EW. Squamous cell carcinoma of the penis. III. Treatment of regional lymph nodes. *J Urol* 1993;149:492–7.
- [79] Narayana AS, Olney LE, Loening SA, Weimar GW, Culp DA. Carcinoma of the penis: analysis of 219 cases. *Cancer* 1982;49:2185–91.
- [80] Solsona E, Iborra I, Ricos JV, et al. Corpus cavernosum invasion and tumor grade in the prediction of lymph node condition in penile carcinoma. *Eur Urol* 1992;22:115–8.
- [81] Parra RO. Accurate staging of carcinoma of the penis in men with nonpalpable inguinal lymph nodes by modified inguinal lymphadenectomy. *J Urol* 1996;155:560–3.
- [82] Colberg JW, Andriole GL, Catalona WJ. Long-term follow-up of men undergoing modified inguinal lymphadenectomy for carcinoma of the penis. *Br J Urol* 1997;79:54–7.
- [83] Coblentz TR, Theodorescu D. Morbidity of modified prophylactic inguinal lymphadenectomy for squamous cell carcinoma of the penis. *J Urol* 2002;168:1386–9.
- [84] d'Ancona CA, de Lucena RG, Querne FA, Martins MH, Denardi F, Netto Jr NR. Long-term followup of penile carcinoma treated with penectomy and bilateral modified

- inguinal lymphadenectomy. *J Urol* 2004;172:498-501, discussion 501.
- [85] Wawroschek F, Vogt H, Bachter D, Weckermann D, Hamm M, Harzmann R. First experience with gamma probe guided sentinel lymph node surgery in penile cancer. *Urol Res* 2000;28:246-9.
- [86] Spiess PE, Izawa JI, Bassett R, et al. Preoperative lymphoscintigraphy and dynamic sentinel node biopsy for staging penile cancer: results with pathological correlation. *J Urol* 2007;177:2157-61.
- [87] Gonzaga-Silva LF, Tavares JM, Freitas FC, Tomas Filho ME, Oliveira VP, Lima MV. The isolated gamma probe technique for sentinel node penile carcinoma detection is unreliable. *Int Braz J Urol* 2007;33:58-63, discussion 64-7.
- [88] Hernandez-Toris N, Quintero-Becerra J, Gallegos-Hernandez JF, et al. Lymphatic mapping and sentinel node biopsy in penis cancer. Feasibility study and preliminary report [in Spanish]. *Cir Cir* 2007;75:87-91.
- [89] Hadway P, Smith Y, Corbishley C, Heenan S, Watkin NA. Evaluation of dynamic lymphoscintigraphy and sentinel lymph-node biopsy for detecting occult metastases in patients with penile squamous cell carcinoma. *BJU Int* 2007;100:561-5.
- [90] Jacobellis U. Modified radical inguinal lymphadenectomy for carcinoma of the penis: technique and results. *J Urol* 2003;169:1349-52.
- [91] Milathianakis C, Bogdanos J, Karamanolakis D. Morbidity of prophylactic inguinal lymphadenectomy with saphenous vein preservation for squamous cell penile carcinoma. *Int J Urol* 2005;12:776-8.
- [92] Heyns CF, Theron PD. Evaluation of dynamic sentinel lymph node biopsy in patients with squamous cell carcinoma of the penis and palpable inguinal nodes. *BJU Int* 2008;102:305-9.
- [93] Protzel C, Hakenberg OW. Chemotherapy in patients with penile carcinoma. *Urol Int* 2009;82:1-7.



**eusp**  
European Urological  
Scholarship Programme

**The EUSP offers EAU members the following programmes:**

- **Scholarship - 1 year for research**
- **Clinical Fellowship - 6 weeks to 3 months**
- **Short Term Visit - 2 to 3 weeks**
- **Visiting Professor**

Application for the various EUSP programmes can be submitted online.  
Please visit [www.uroweb.org](http://www.uroweb.org) or go directly to <http://www.uroweb.org/professional-resources>

**EAU**  
European  
Association  
of Urology