

8ο Ελληνικό Διαδραστικό Σχολείο Ουρολογίας
(5-8 Μαρτίου, Πορταριά, Πήλιο)

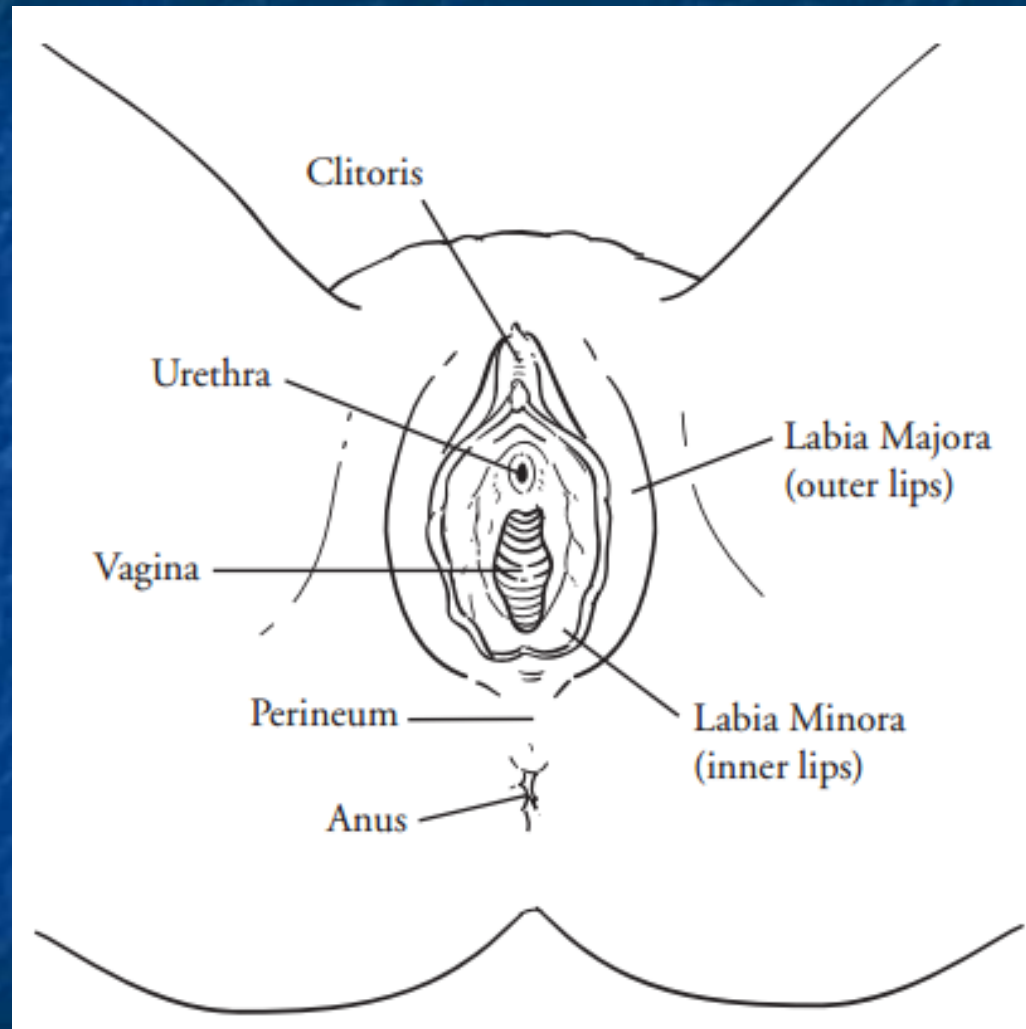
Φροντιστήριο Ι

**Τι πρέπει να γνωρίζει ο Ουρολόγος για τις
παθήσεις του αιδοίου και του κόλπου;**

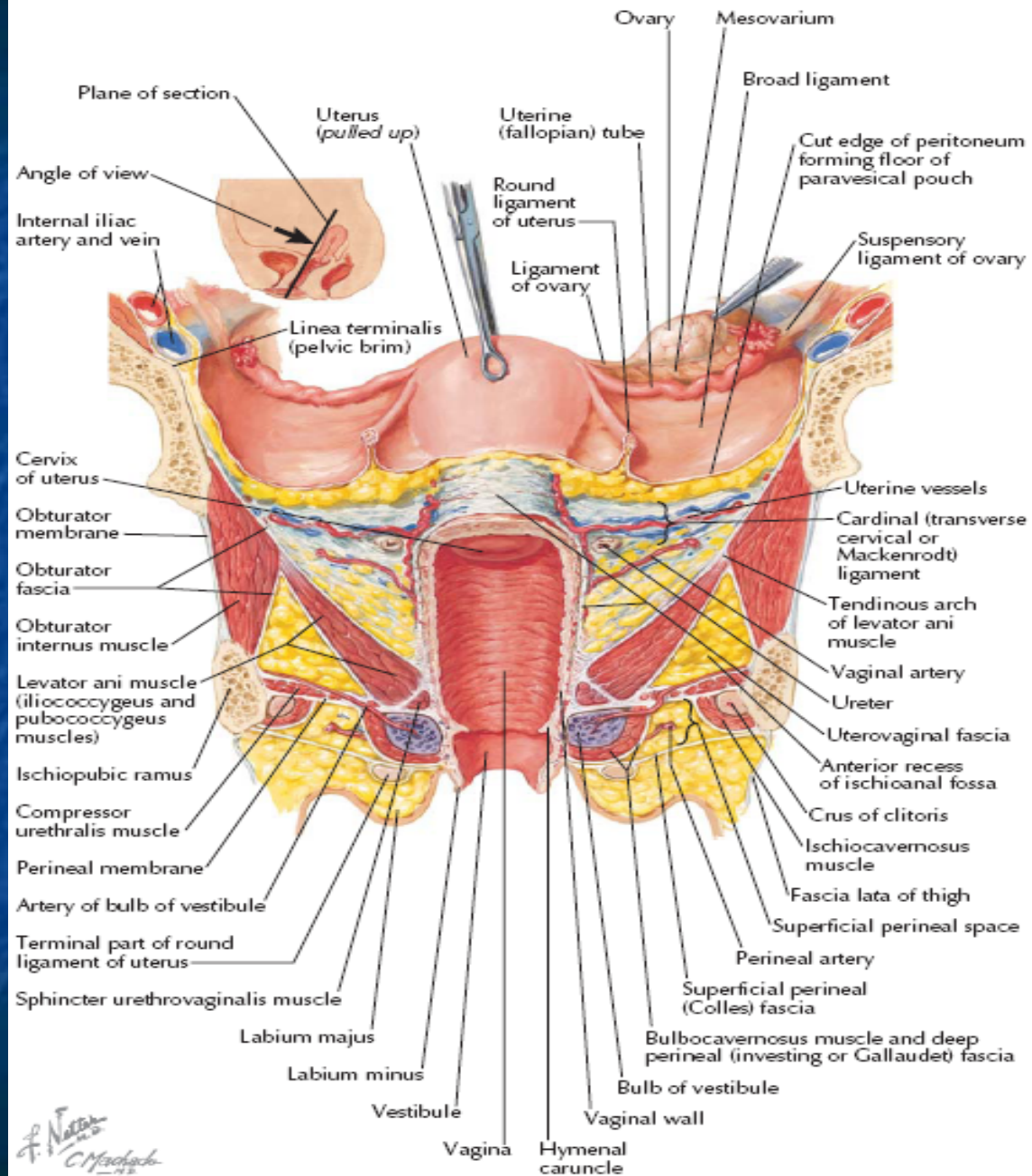
Θ. Αγοραστός
Καθηγητής Μαιευτικής-Γυναικολογίας
Αριστοτελείου Πανεπιστημίου Θεσσαλονίκης

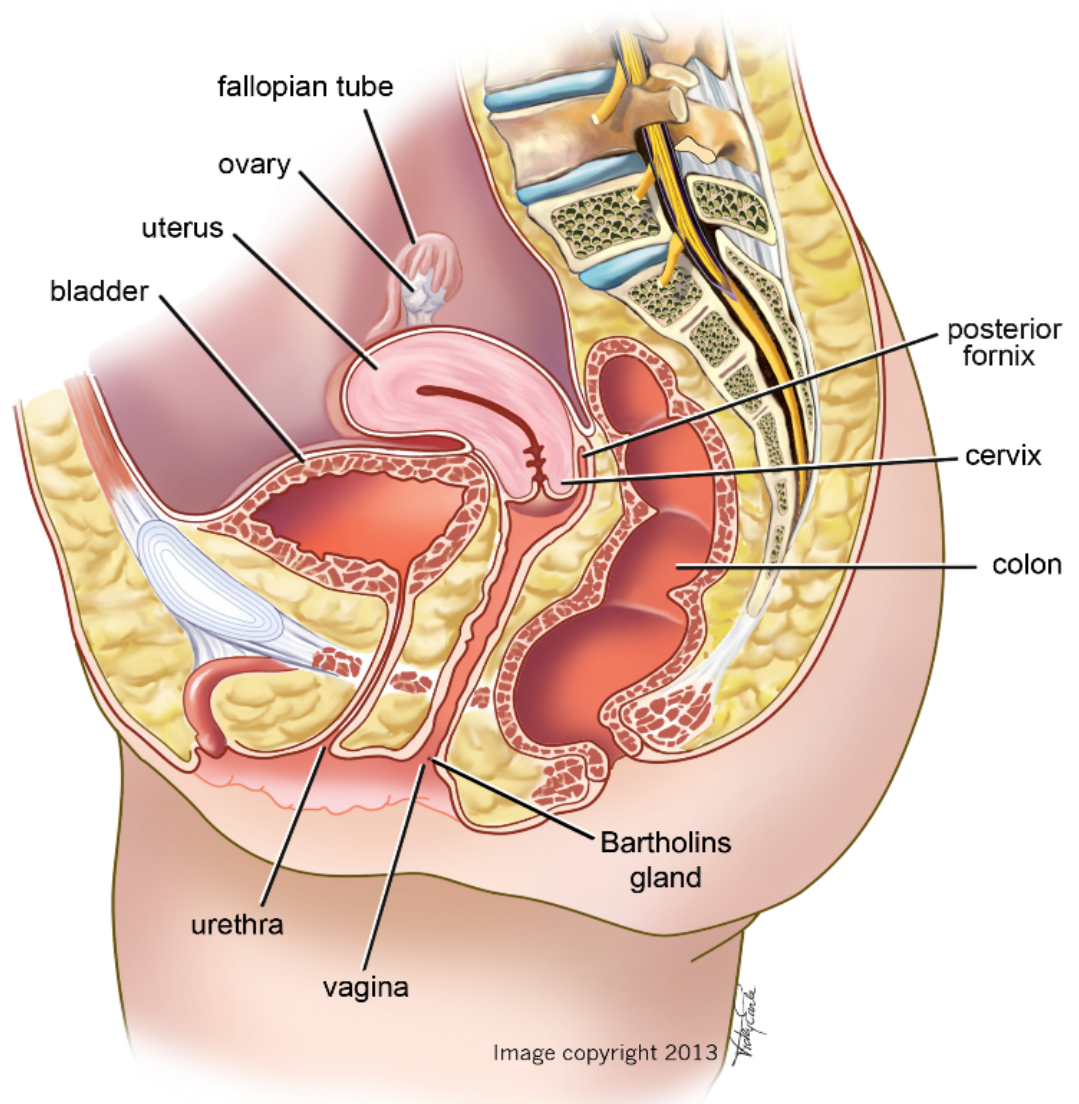
Disclosed potential conflicts of interest

- Free testing or reduced fees for testing of study specimens in collaborative work with Roche Molecular Systems and Qiagen
- Screening and HPV testing trials partially supported by Vianex/Sanofi Pasteur MSD
- Research grants by Volkswagen, Bodossakis and Papageorgiou Foundations
- Travel support to conferences/meetings/symposia occasionally granted by either Vianex/Sanofi Pasteur MSD, GlaxoSmithKline or Roche.



The Vagina

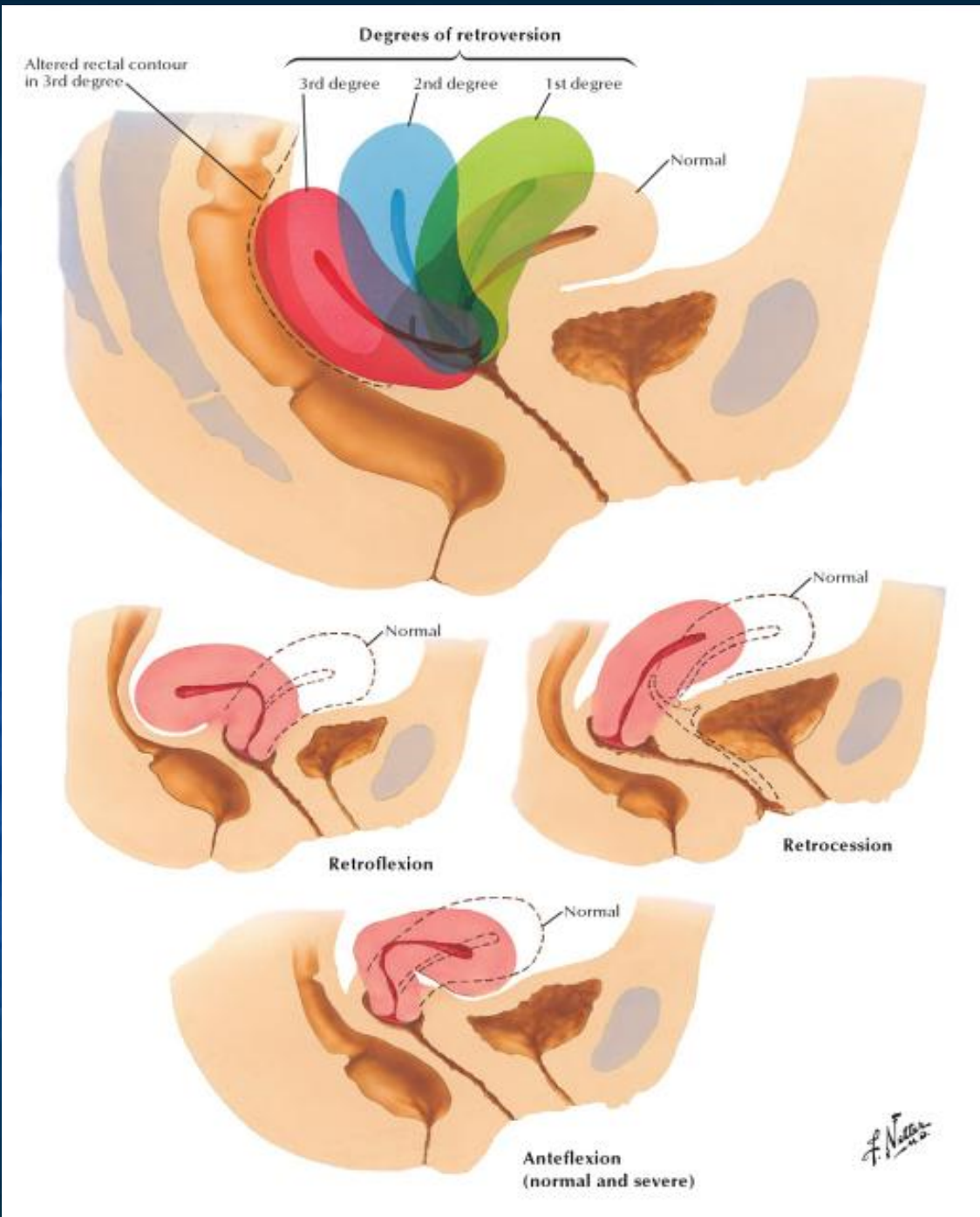




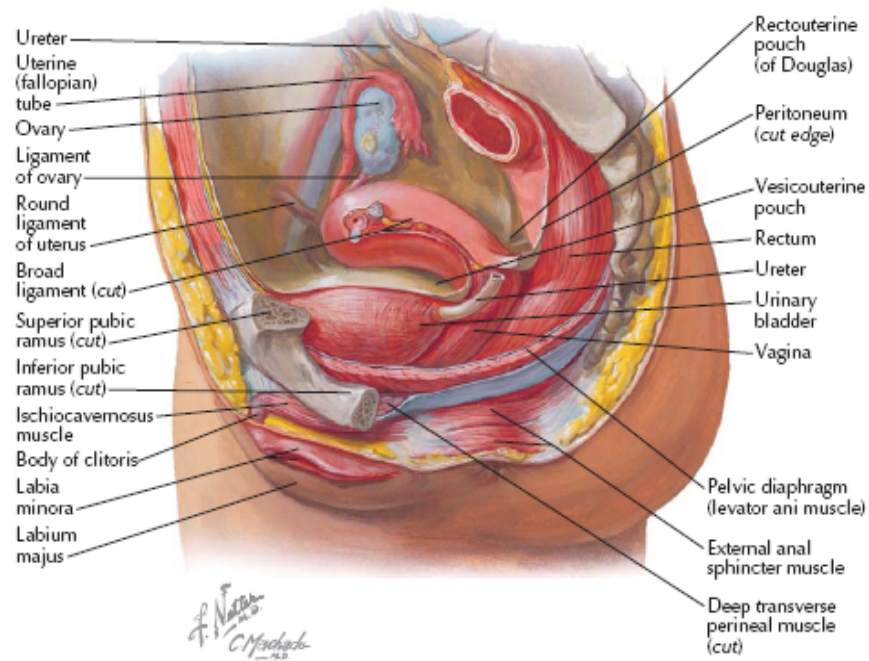
fallopian tube
ovary
uterus
bladder
posterior fornix
cervix
colon
Bartholins gland
vagina
urethra

Image copyright 2013

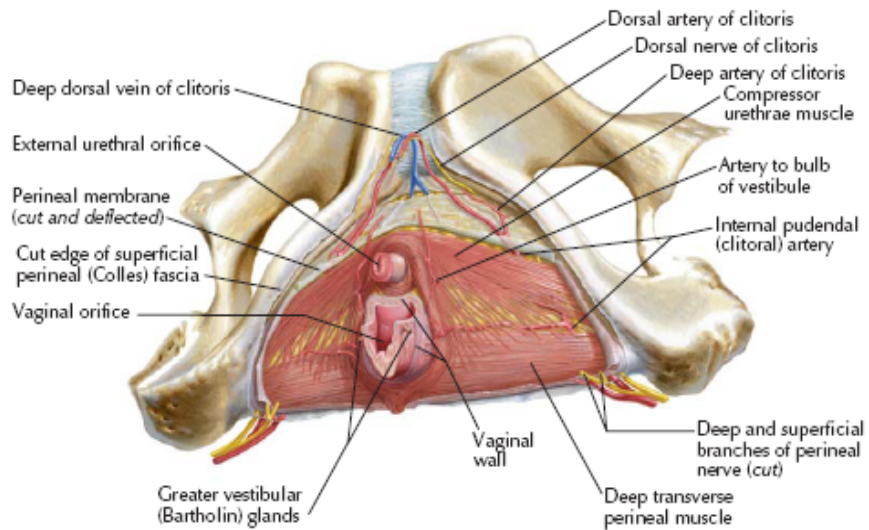
Medical Science

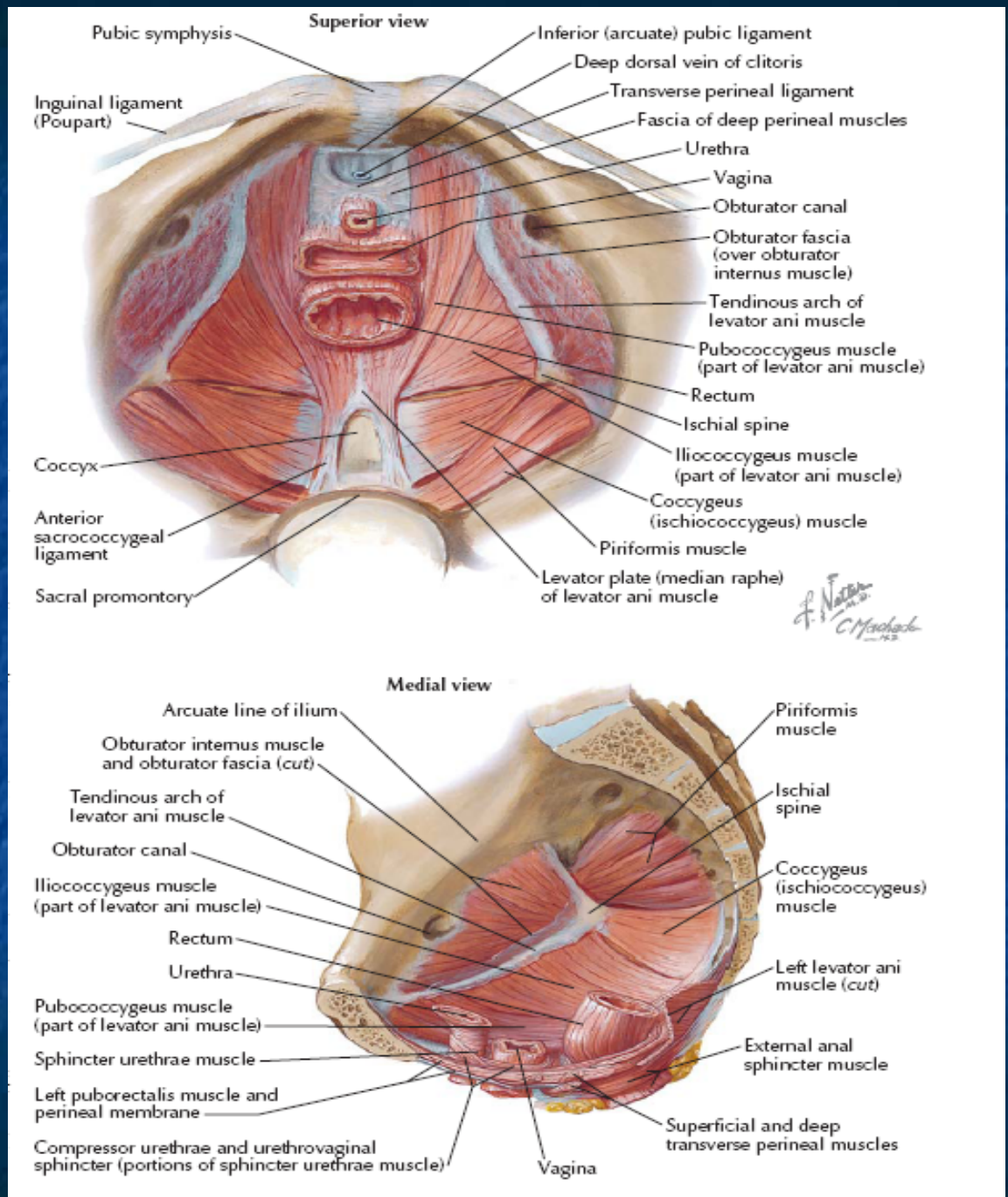


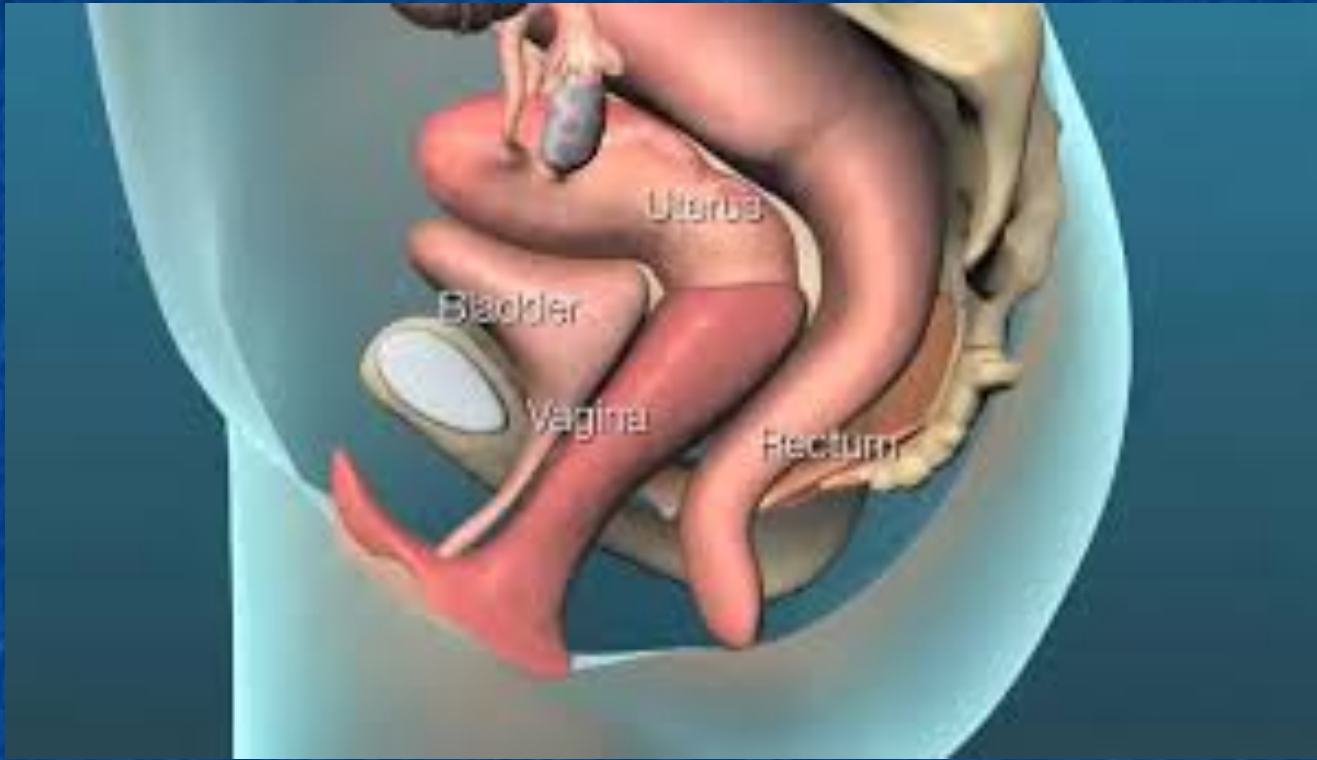Paramedian (sagittal) dissection



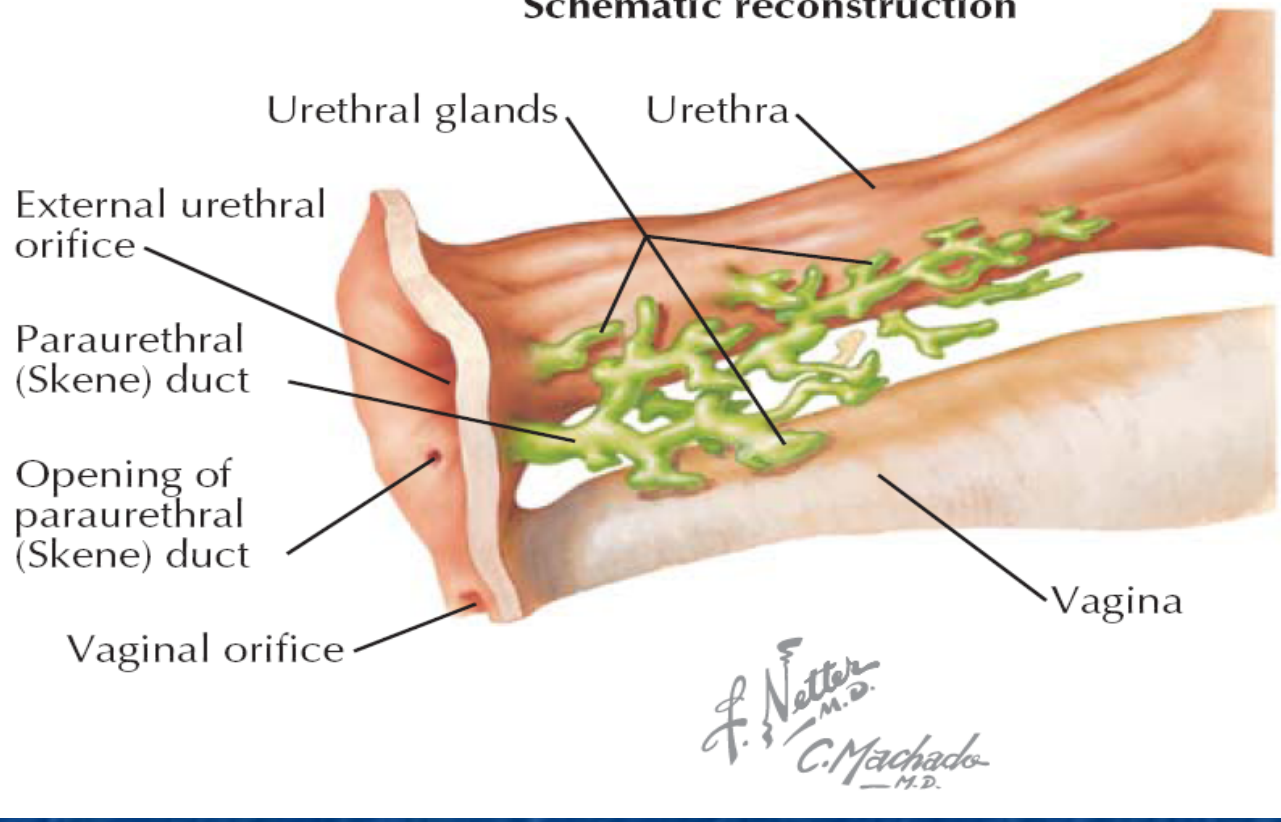
Deep perineal space

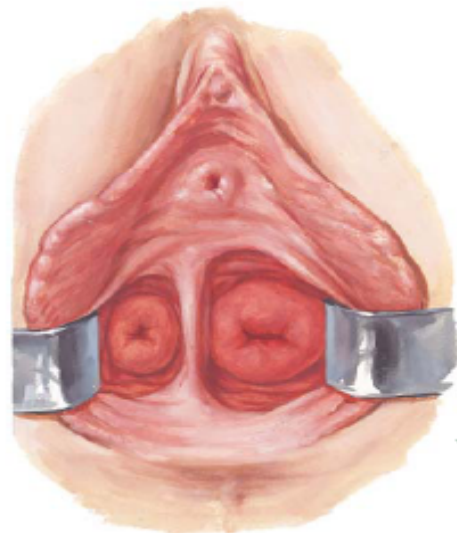






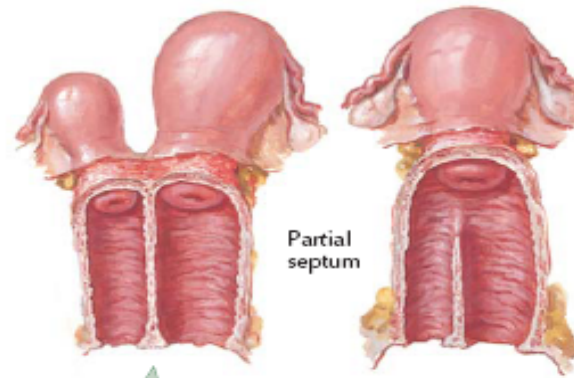
Schematic reconstruction





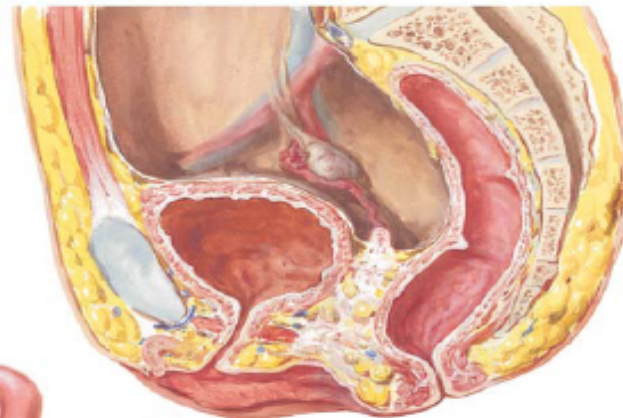Double vagina

Septum is usually less than one centimeter in thickness and may be complete or incomplete. Location is variable

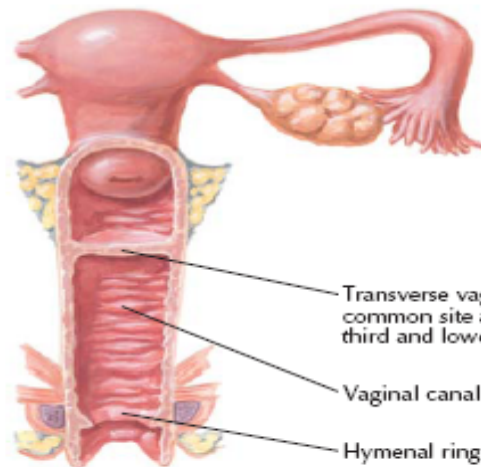


Partial septum

Complete septum with double uterus



Absence of vagina and uterus

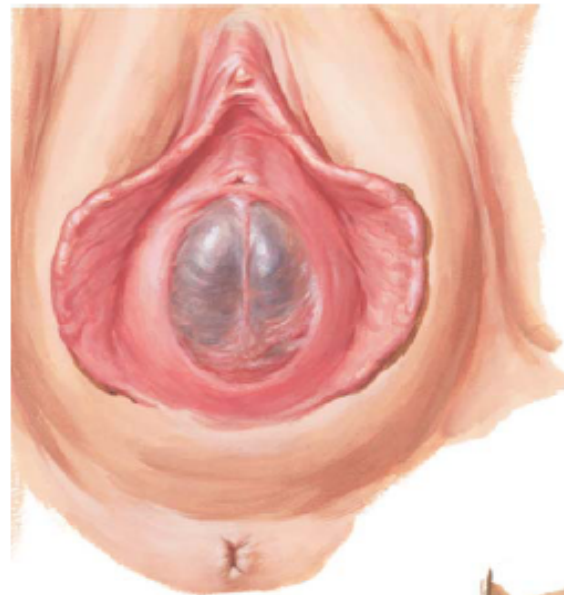


Transverse vaginal septum—most common site at junction of upper third and lower two-thirds of vaginal canal

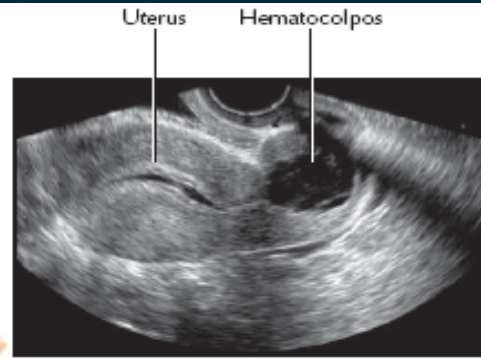
Vaginal canal

Hymenal ring

J. N. M.D.
JOHN A. CRAIG M.D.

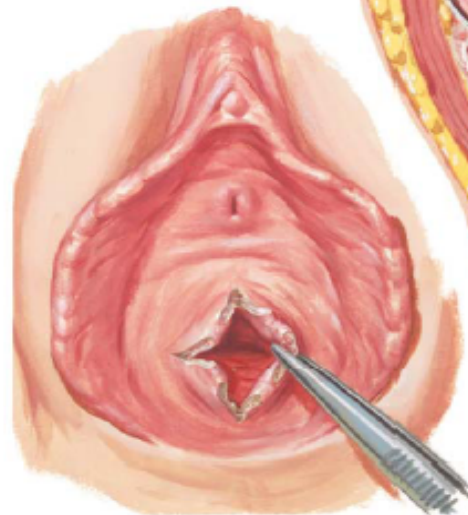


Imperforate hymen

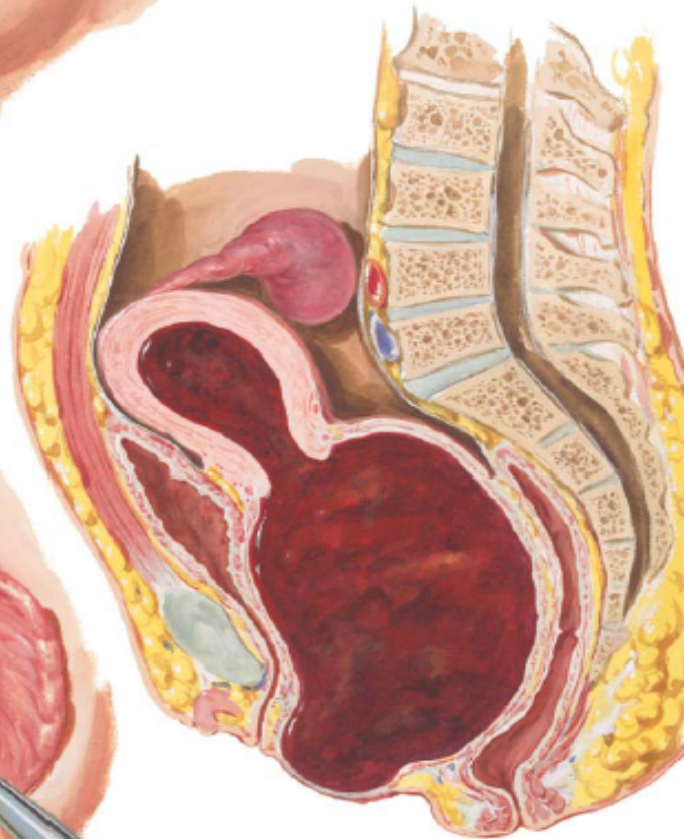

Uterus Hematocolpos

Sagittal view

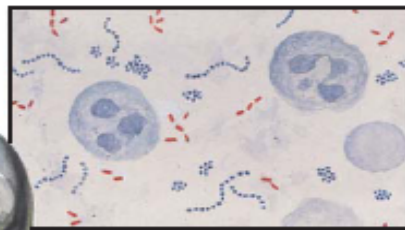
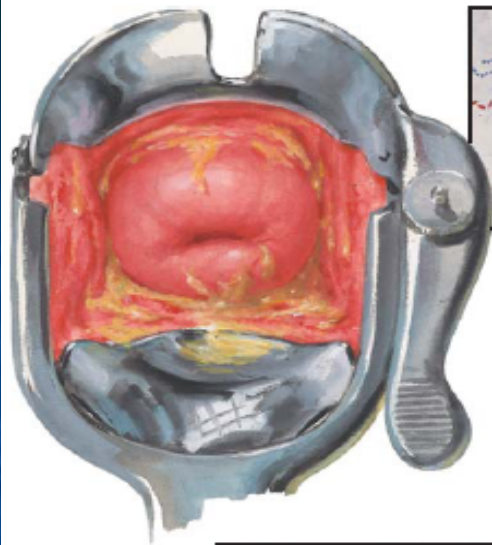


Thick, fibrous hymen (after cruciate incision)

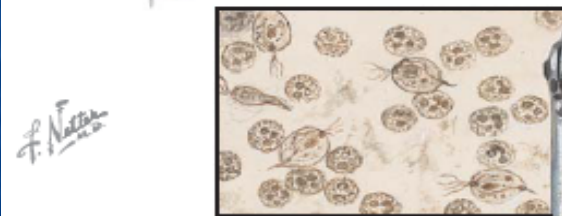


Hematocolpos with hematometra and hematosalpinx

F. Netter
M.D.

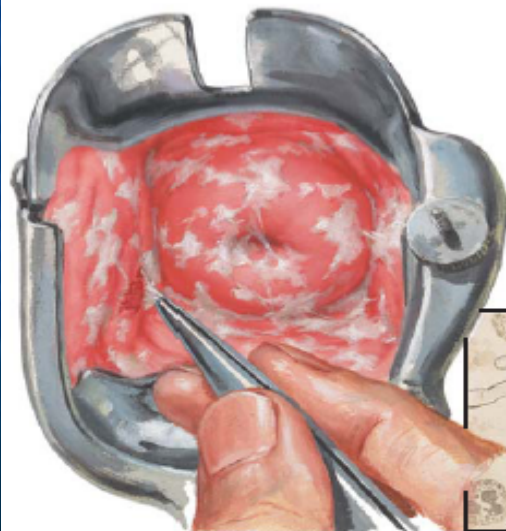
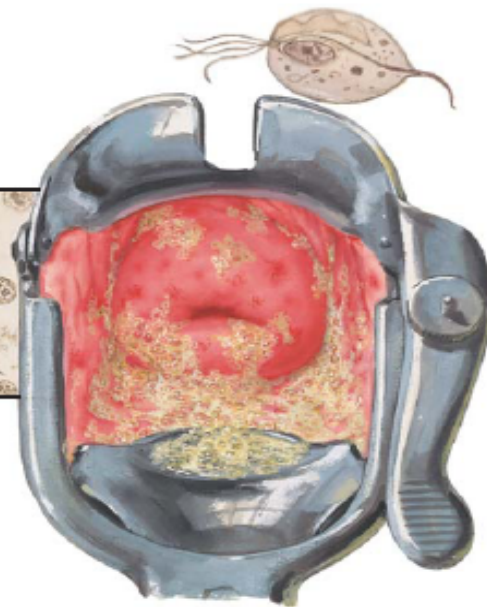


Bacterial vaginosis

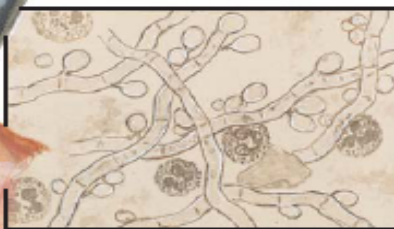

F. Netter
1925

Trichomonas vaginalis

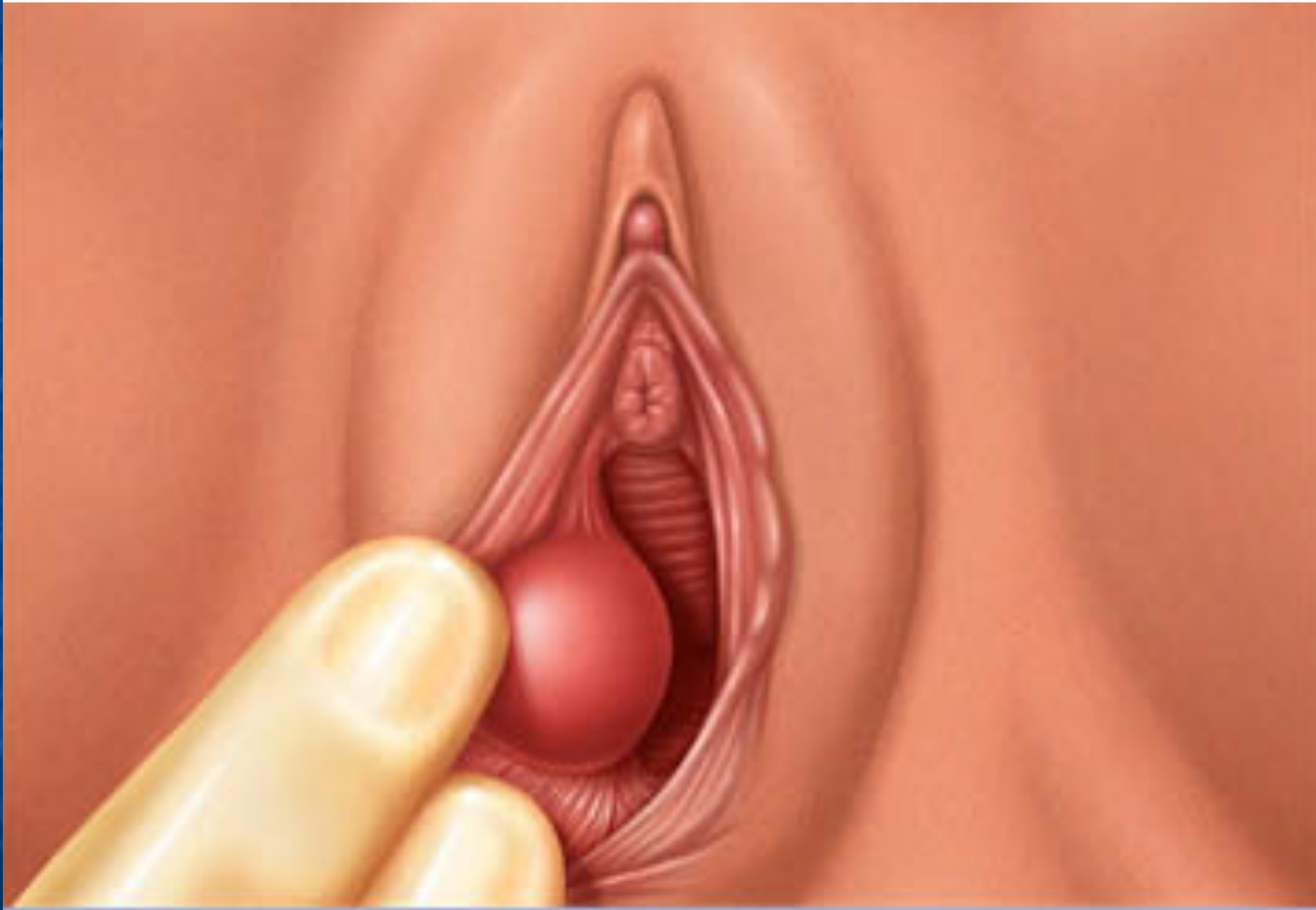

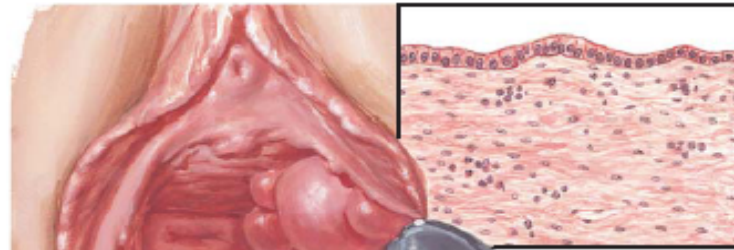
Monilia albicans





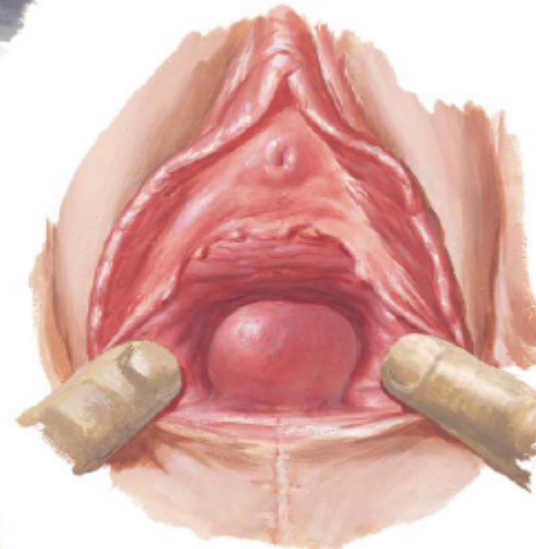
Bartholin's cyst



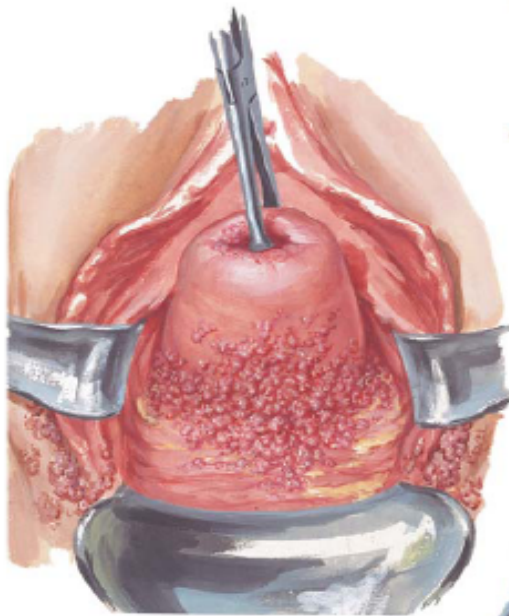


Gartner duct cyst, section of wall with columnar and cuboidal epithelium

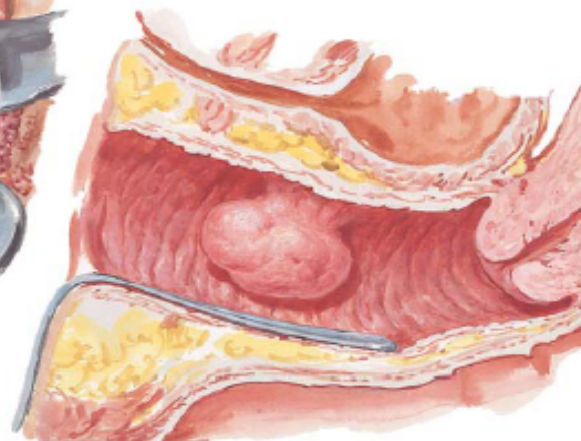
Multiple Gartner duct cysts



Inclusion cyst

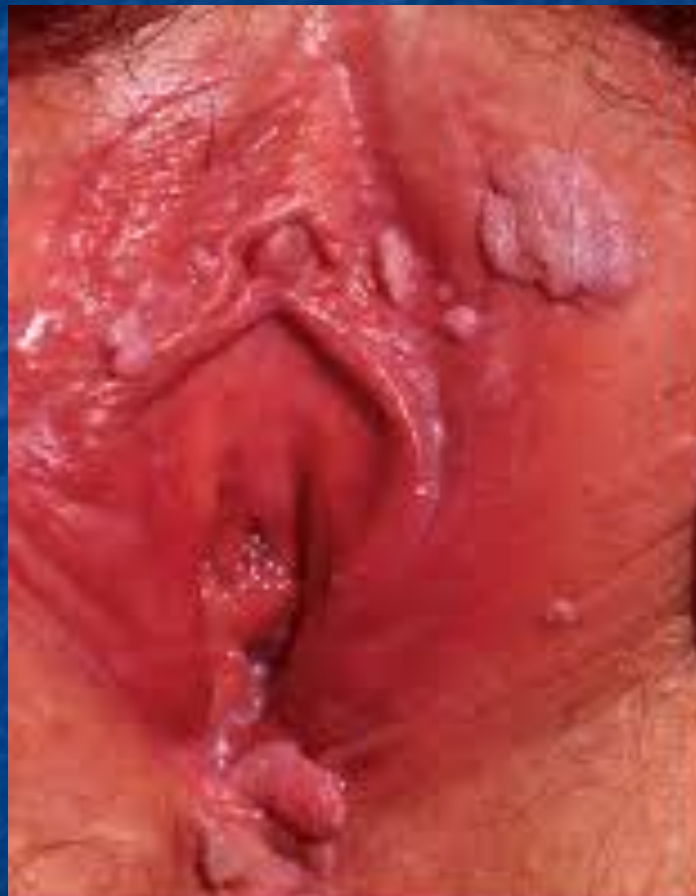

Condylomata acuminata

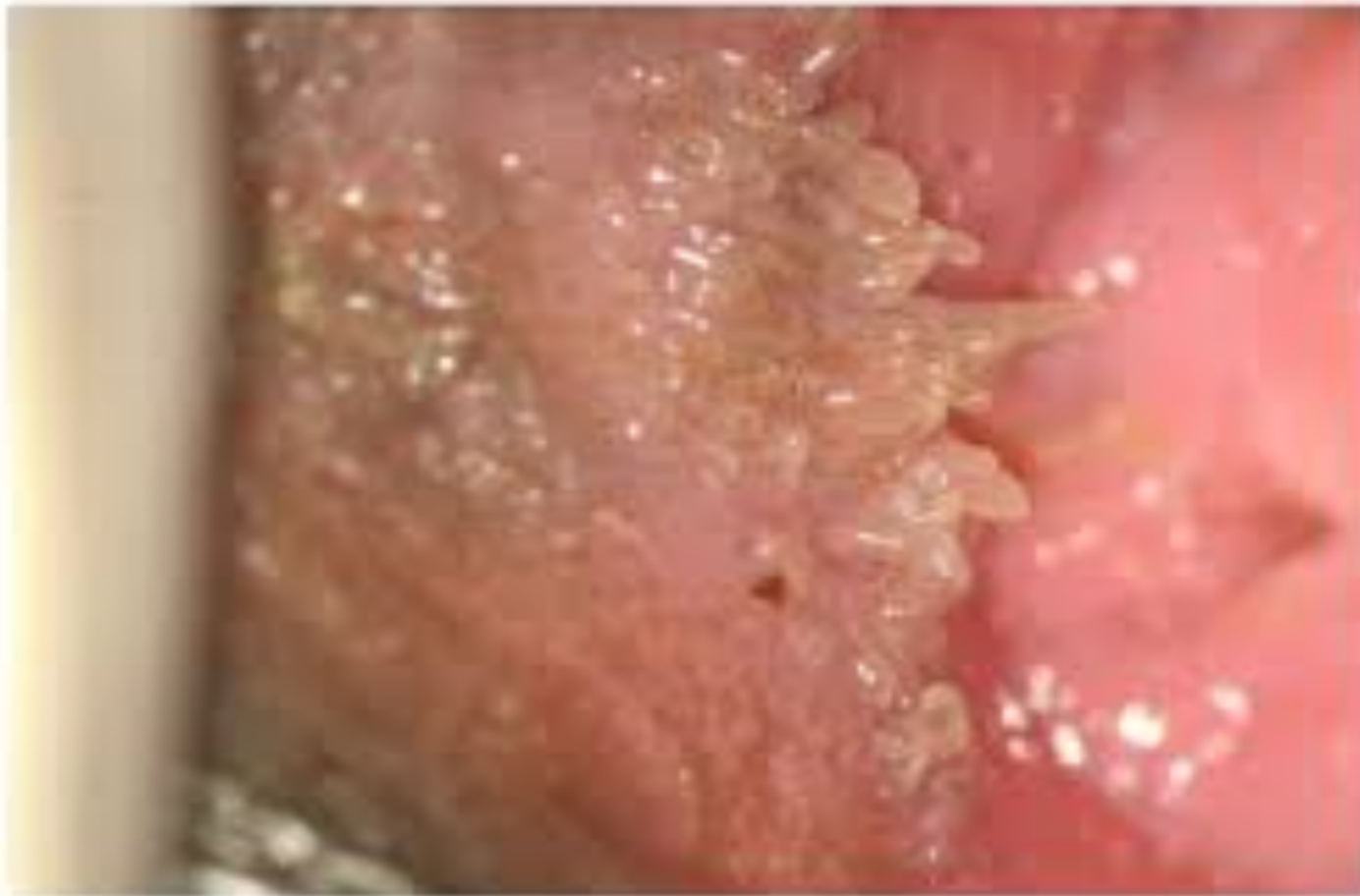

Fibroma

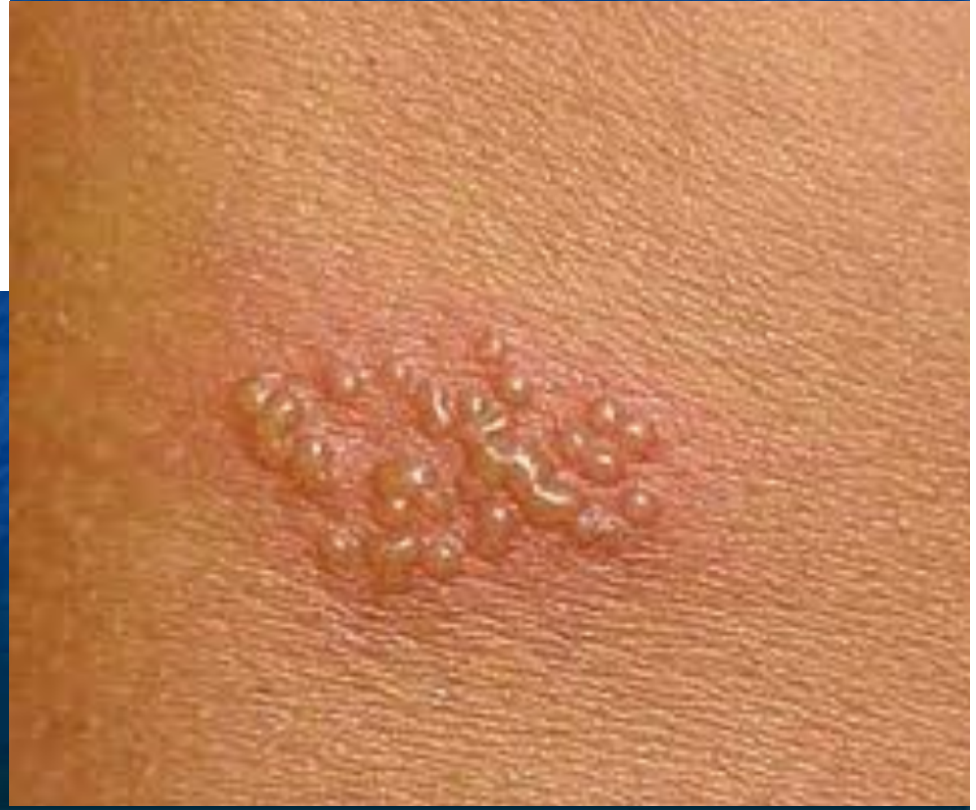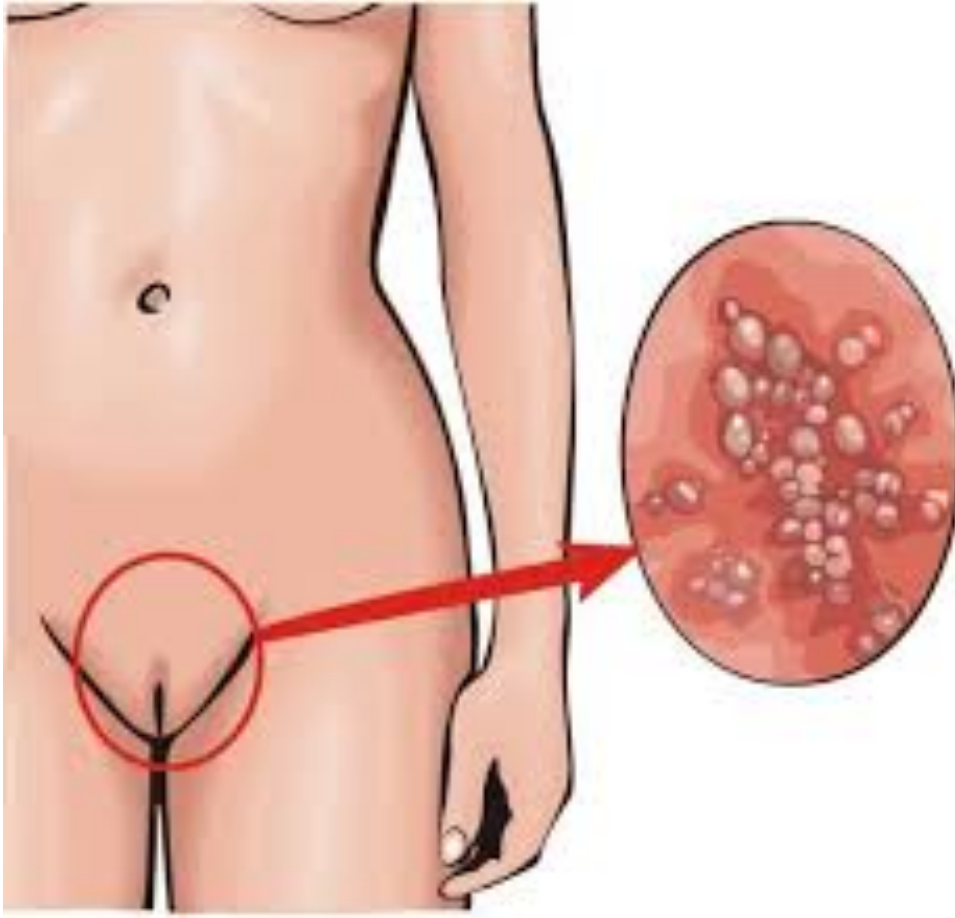
f. Netter



Vulvar papillomatosis



Herpes Genitalis

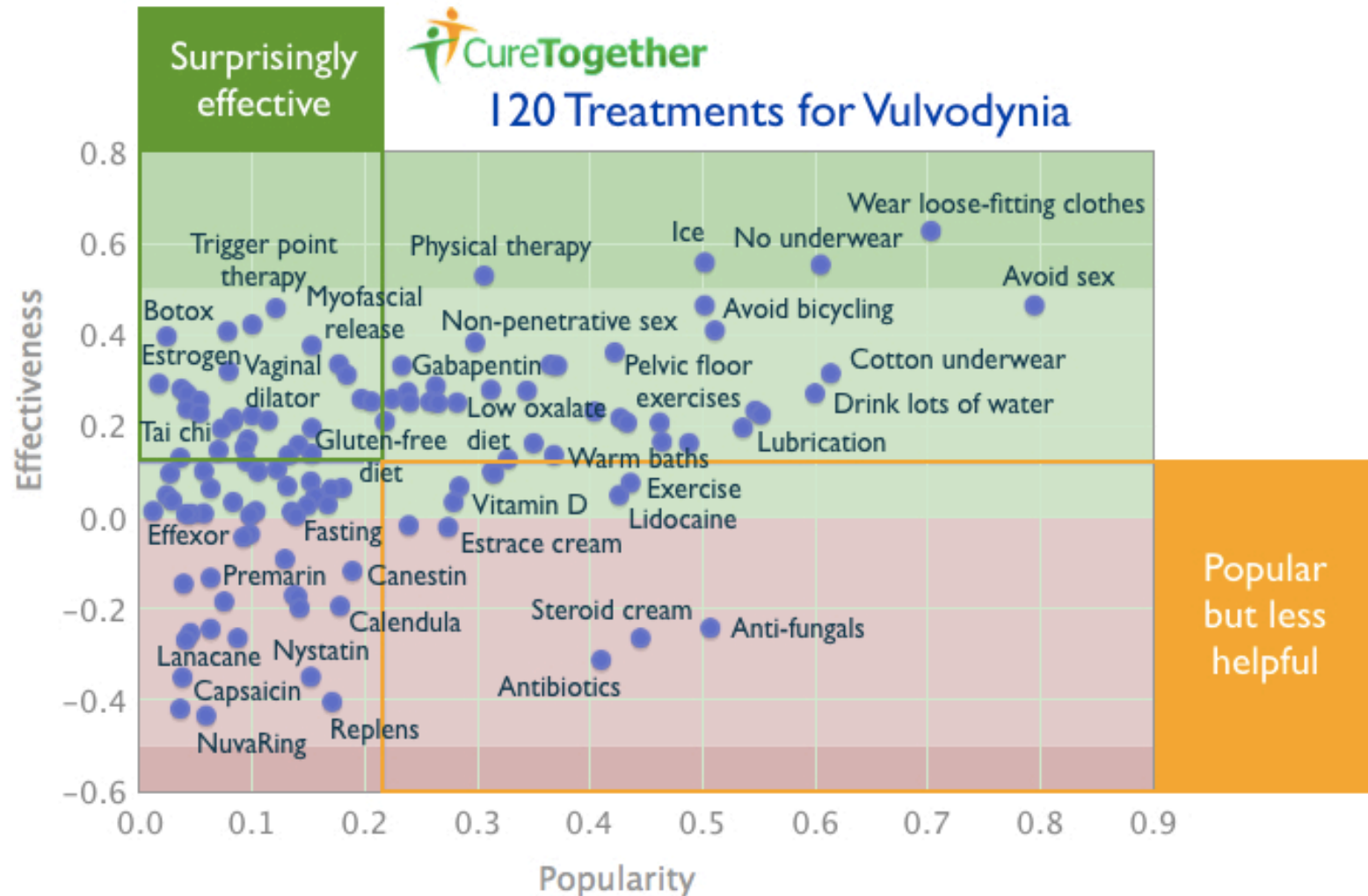


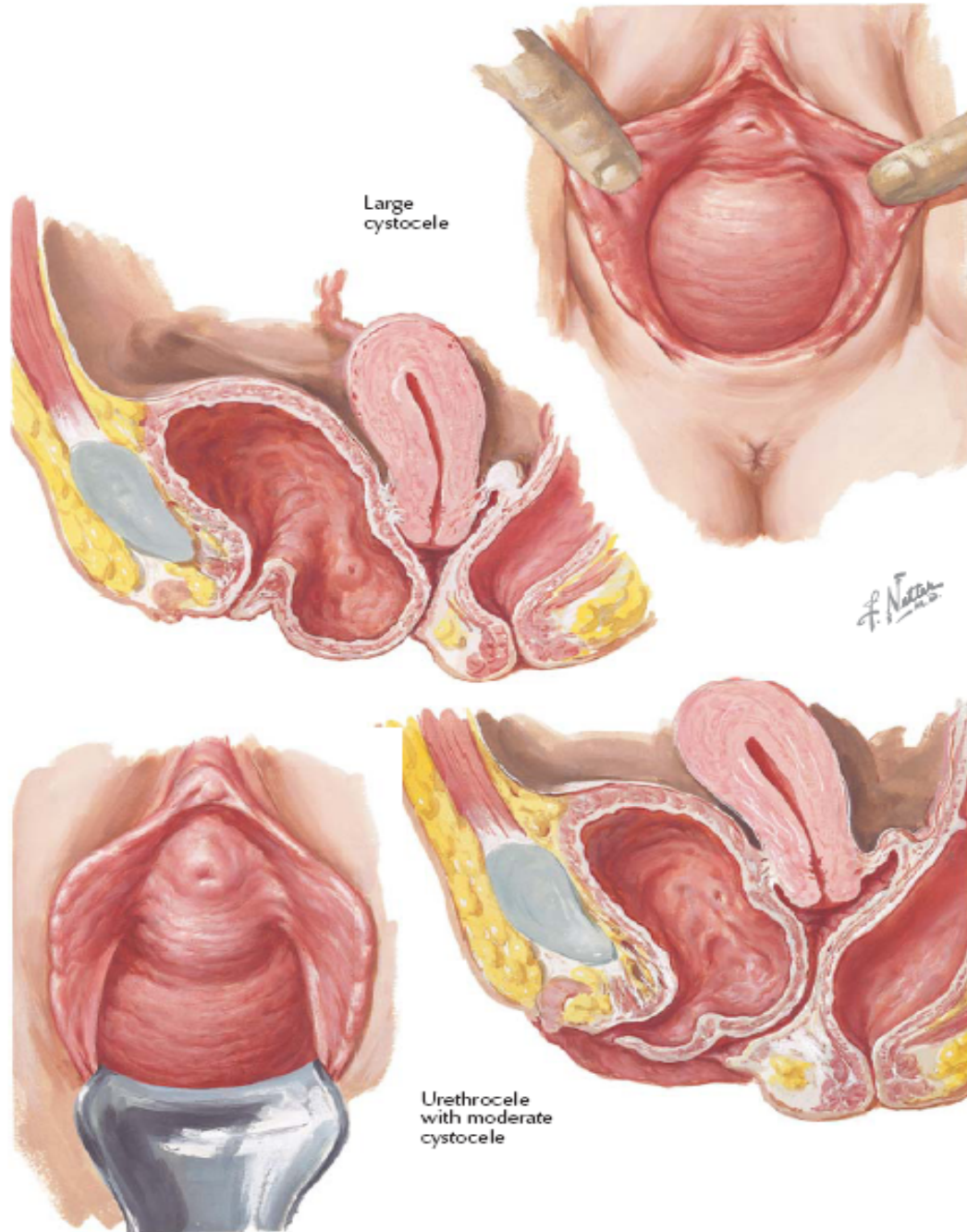


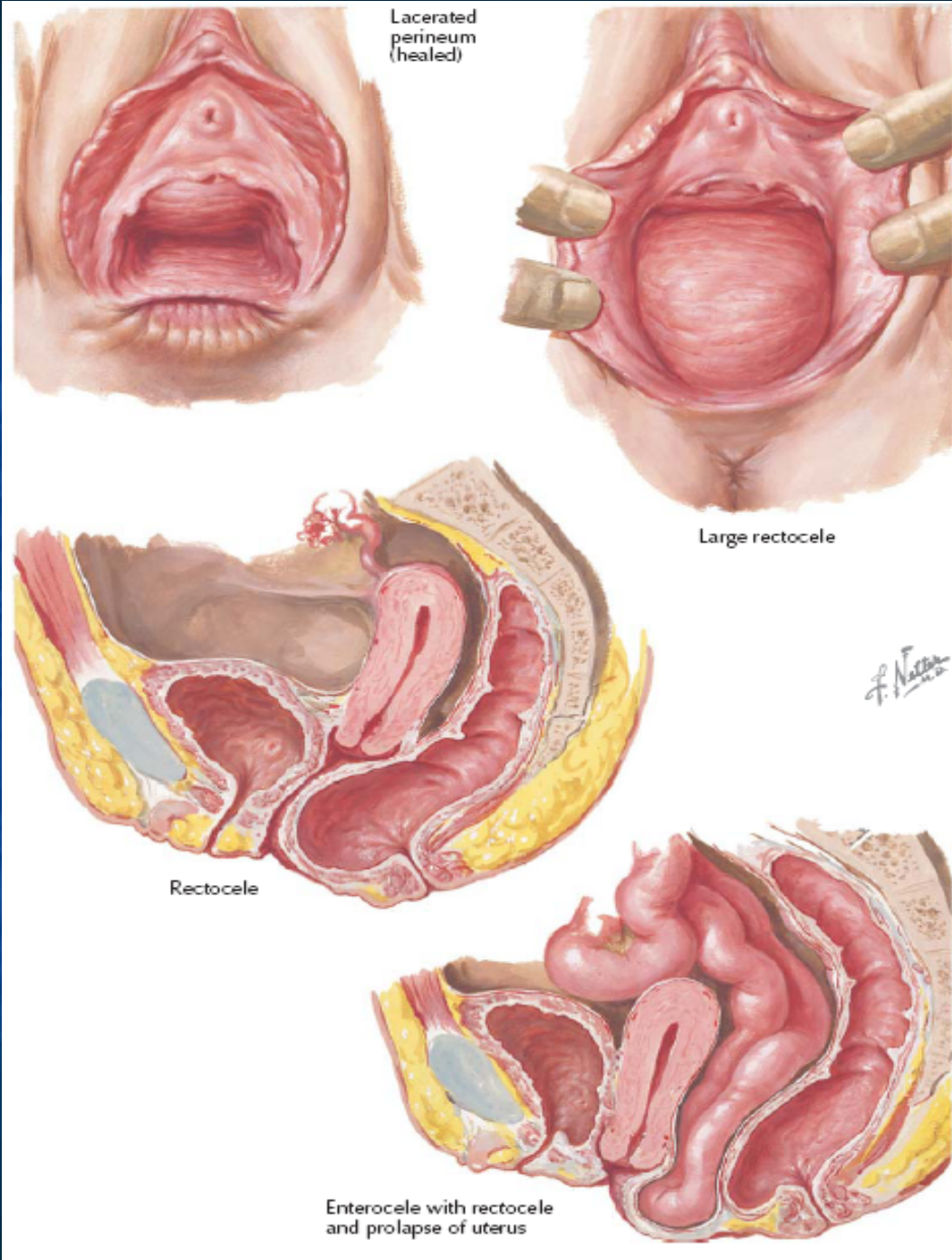


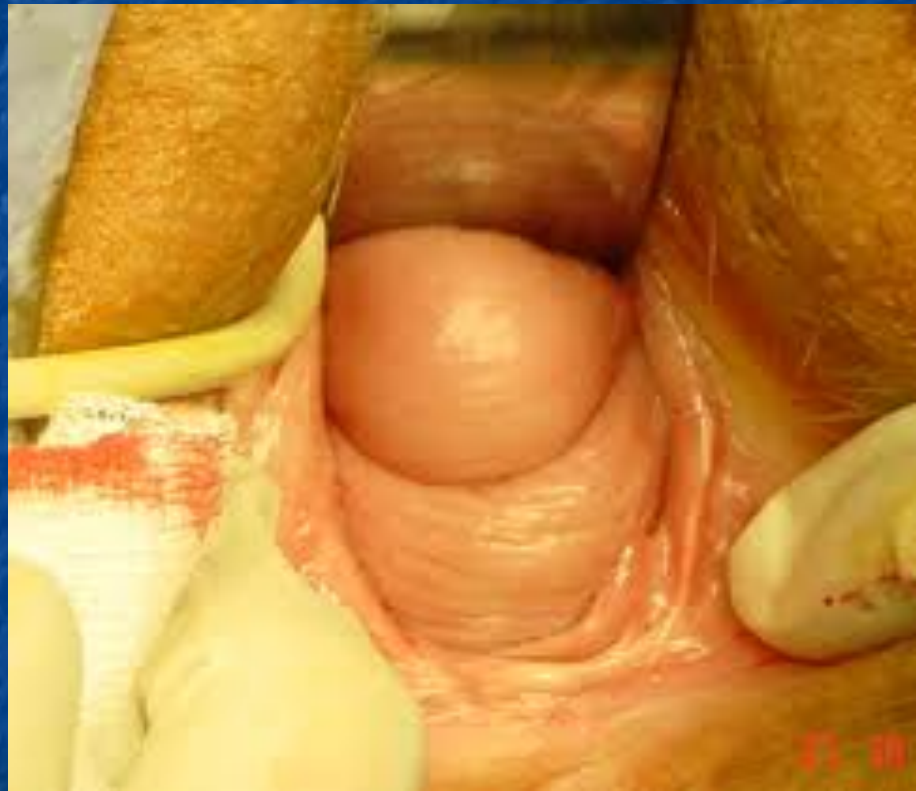

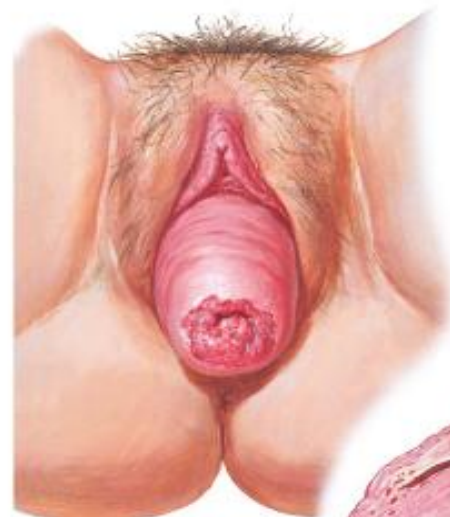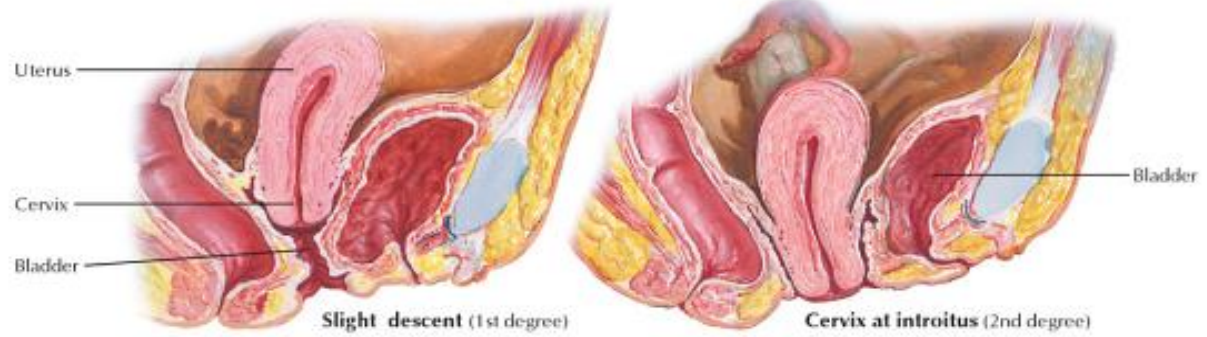120 Treatments for Vulvodynia



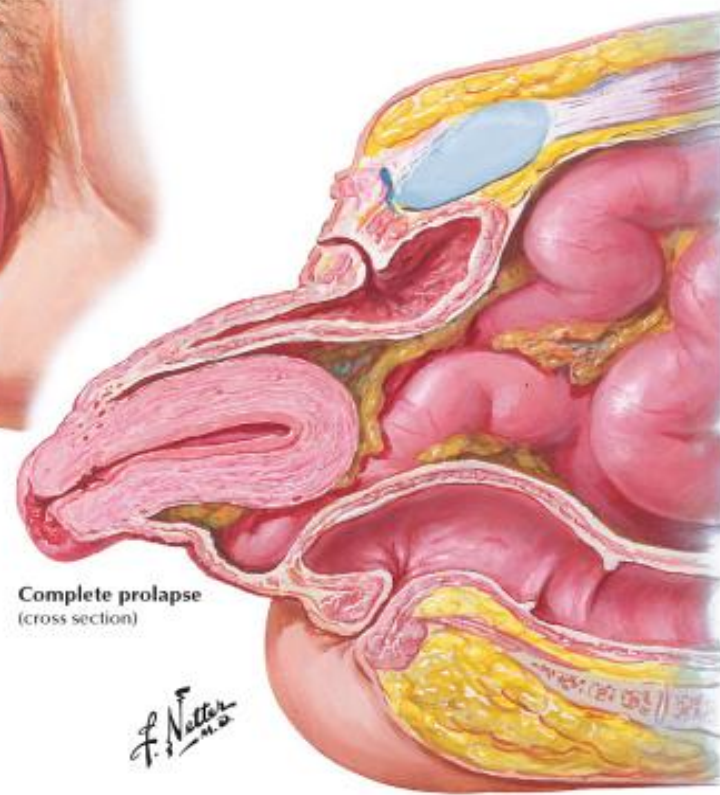




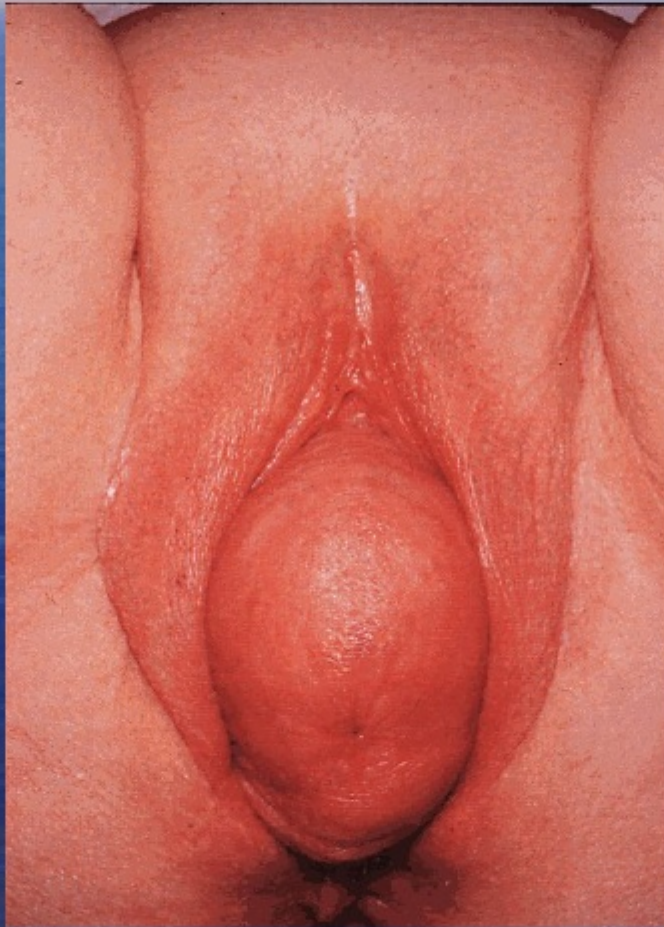





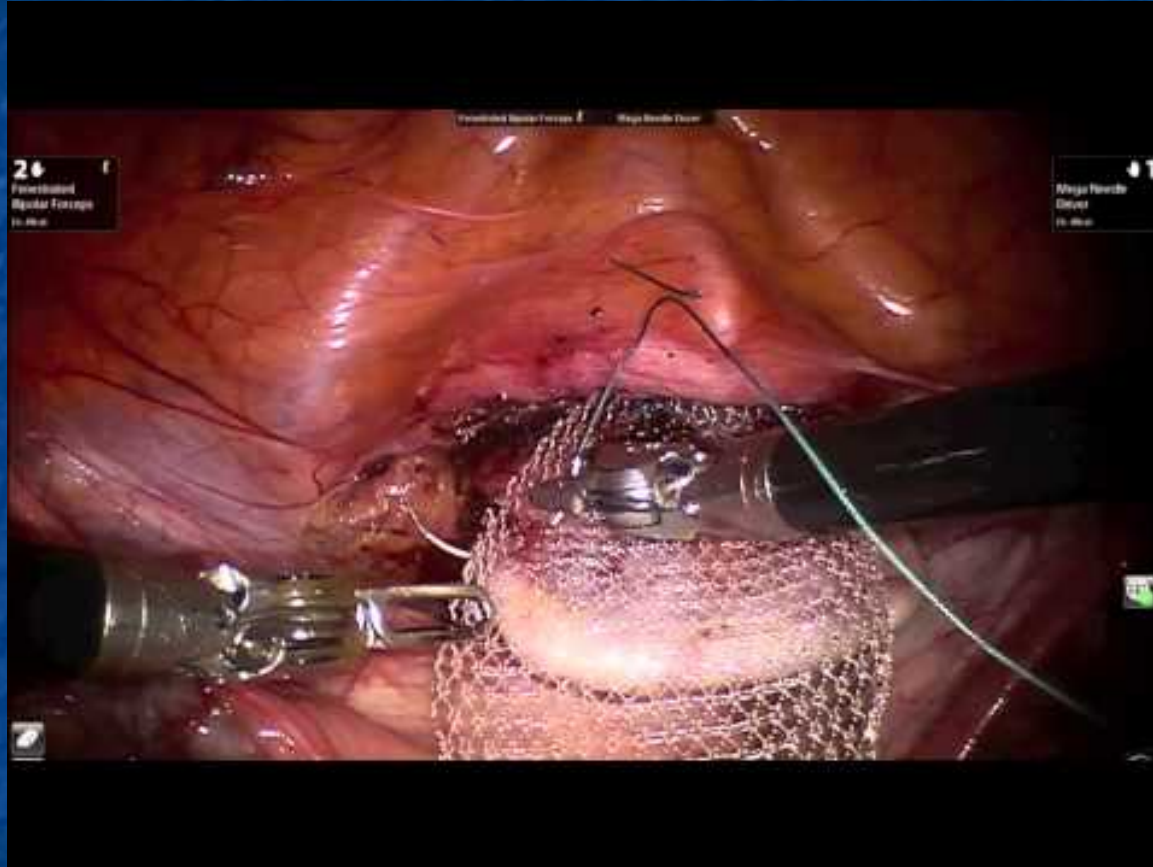
Clinical appearance
procidentia



Uterine Prolapse

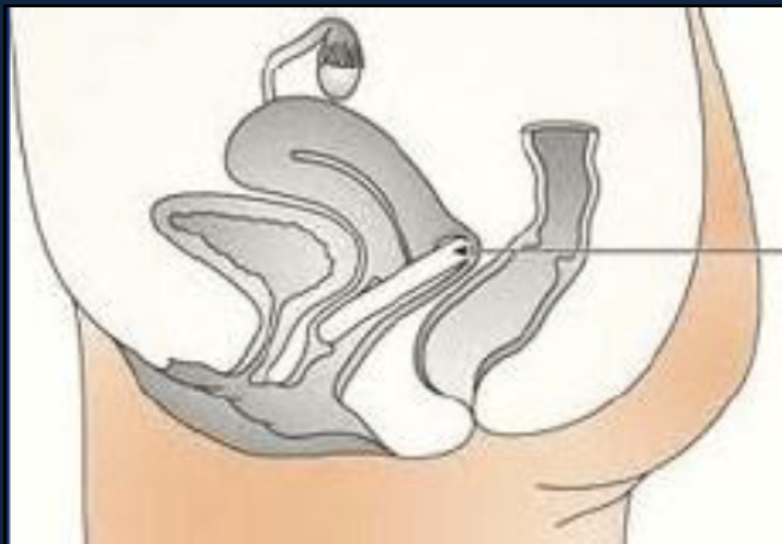




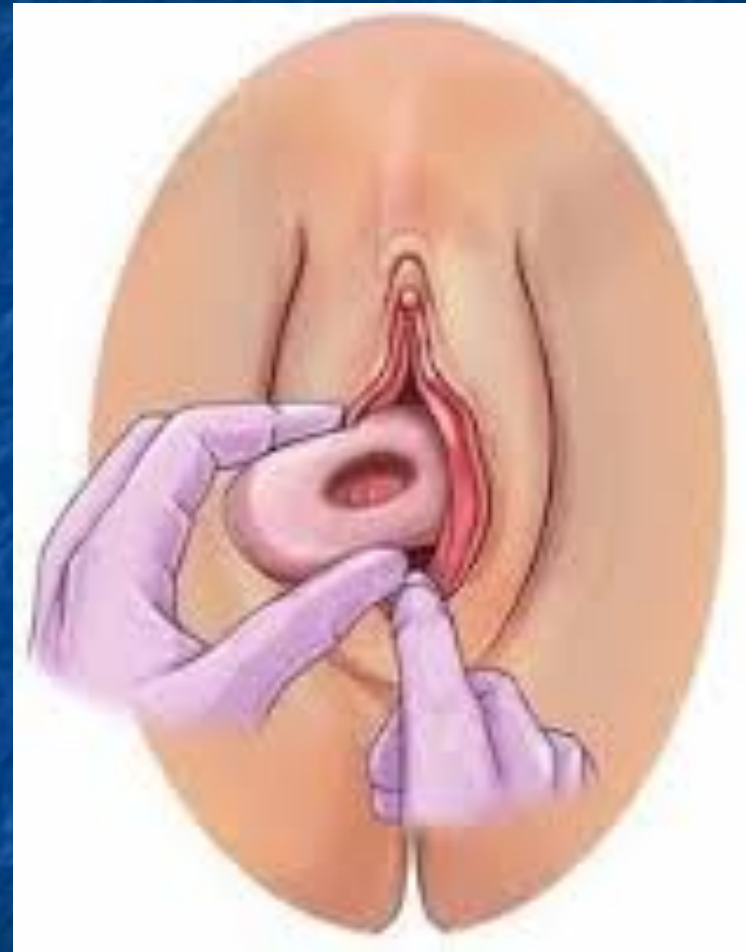

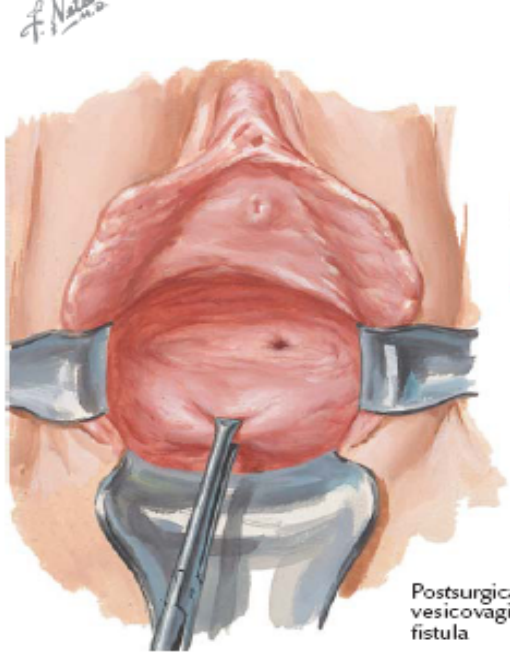
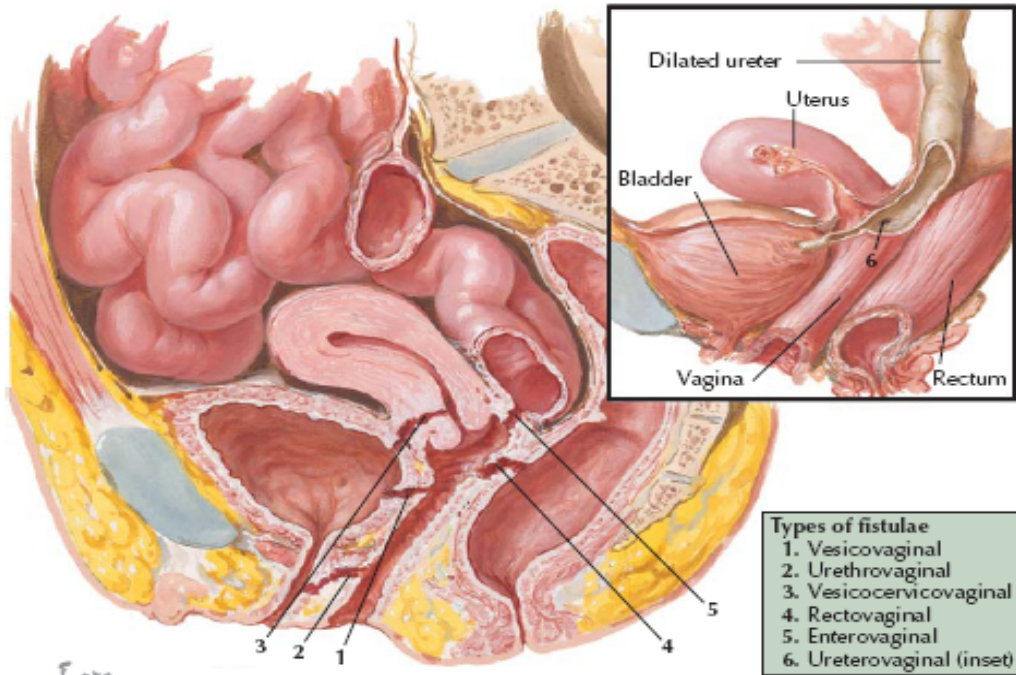


Vaginal ring pessaries

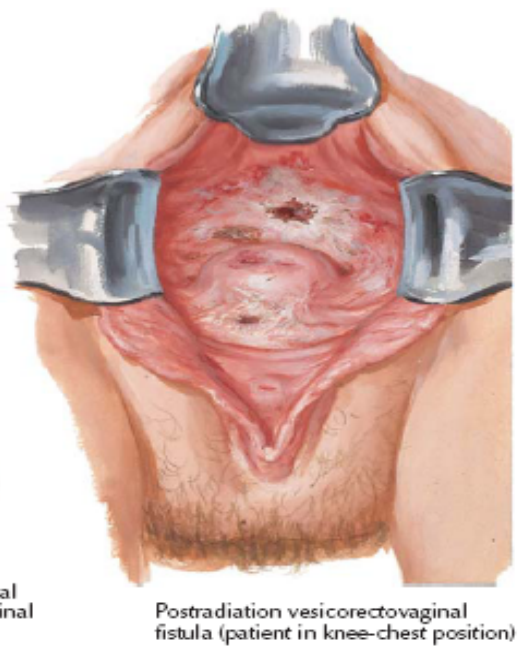


Correctly fitted ring pessary





Postsurgical vesicovaginal fistula



Postradiation vesicorectovaginal fistula (patient in knee-chest position)

Ευχαριστώ πολύ!