

Guidelines on Penile Cancer

G. Pizzocaro (past-chair), F. Algaba, E. Solsona,
S. Tana, H. Van Der Poel, N. Watkin, S. Horenblas (chair)

TABLE OF CONTENTS

PAGE

1.	INTRODUCTION	4
2.	METHODOLOGY	4
2.1	References	5
3.	DEFINITION OF PENILE CANCER	5
4.	EPIDEMIOLOGY	5
4.1	References	6
5.	RISK FACTORS AND PREVENTION	7
5.1	References	7
6.	TNM CLASSIFICATION AND PATHOLOGY	9
6.1	TNM classification	9
6.1.1	References	10
6.2	Pathology	10
6.2.1	Penile biopsy	11
6.2.2	Pathological categories	11
6.2.3	Histology and metastatic risk	11
6.2.4	References	11
7.	DIAGNOSIS AND STAGING	12
7.1	Primary lesion	12
7.2	Regional lymph nodes	13
7.2.1	Lymphatic drainage of the penis	13
7.2.2	Non-palpable nodes	13
7.2.3	Risk factors and metastasis detection	13
7.2.4	Palpable nodes	13
7.2.5	Conclusion	14
7.3	Distant metastases	14
7.4	Guidelines for the diagnosis and staging of penile cancer	14
7.5	References	14
8.	TREATMENT	17
8.1	Primary tumour	17
8.1.1	Categories Tis, Ta, and T1a	17
8.1.2	Category T1b tumours of the glans with deeper infiltration (> 1 mm)	17
8.1.3	Category T2 (limited to the glans)	18
8.1.4	Local disease recurrence after conservative surgery	18
8.1.5	Category T2 with invasion into the corpus cavernosum	18
8.1.6	Categories T3 and T4	18
8.1.7	Radiotherapy	18
8.1.8	Guidelines for treatment strategies for penile cancer	18
8.2	Regional lymph nodes	19
8.2.1	Surveillance	19
8.2.2	Management of patients with non-palpable inguinal nodes	19
8.2.3	Management of patients with palpable inguinal nodes	19
8.2.4	Adjuvant chemotherapy	20
8.2.5	Management of patients with fixed or relapsed inguinal nodes	20
8.2.6	The role of radiotherapy	20
8.2.7	Guidelines for treatment strategies for nodal metastases	20
8.3	References	21
9.	FOLLOW-UP	23
9.1	How to follow-up	23
9.2	When to follow-up	23
9.3	Primary tumour	24

9.4	Regional recurrences	24
9.5	Guidelines for follow-up in penile cancer	24
9.6	References	25
10.	QUALITY OF LIFE	25
10.1	Sexuality and fertility after cancer	25
	10.1.1 Sexual activity and quality of life after penile cancer laser treatment	25
	10.1.2 Sexual function after partial penectomy for penile cancer	25
10.2	Sexual mutilation, relapse, and death	26
10.3	References	26
11.	ABBREVIATIONS USED IN THE TEXT	27

1. INTRODUCTION

The European Association of Urology (EAU) Guidelines Group on Penile Cancer has prepared this guidelines document to assist medical professionals in the management of penile cancer. The guidelines aim to provide detailed, up-to-date information, based on recent developments in our understanding and management of penile squamous cell carcinoma (SCC). However, it must be emphasised that these guidelines provide an updated, but not yet standardised general approach to treatment and that they provide guidance and recommendations without legal implications.

Publication history information: The Penile Cancer Guidelines were first published in 2001 and updated in 2004 and 2009. The literature search for the 2009 update covered the period from October 2004 to December 2008. The reason to present such an early update can also be attributed to the recent publication of the 2009 Tumour Node Metastasis (TNM) classification which, for penile cancer, had remained unchanged since 1987. Additionally, this update allowed inclusion of relevant new references.

2. METHODOLOGY

A systematic literature search on penile cancer was performed by all members of the EAU Penile Cancer Working Panel which covered the period between October 2004 and December 2008. At the onset of the project, each member was assigned one or two topics in accordance with their particular expertise. Each panel member was teamed up with another panel member who acted as a reviewer of a section. The panel decided to avoid rare diseases and to restrict the guidelines to SCC only. Since new publications became available in the first 3 years, the initial literature acquisition resulted in a first draft for discussion in 2008. This document was reviewed and updated by the panel and published in the 2009 edition of the EAU guidelines book and as an ultra-short (pocket) edition at the Annual EAU Congress in Stockholm, Sweden. For this 2010 print, the results of the updated search performed by the panel for their scientific publication (1) covering the period between December 2008 and December 2009 was supplemented by a second search with a cut-off date of March 2010.

To date the physician data query on 'Penile Cancer Treatment' (Health Professional Version) published by the National Cancer Institute, National Institutes of Health in Bethesda, MD, USA (2), remains the only evidence-based, peer-reviewed document available. No randomised controlled trials or Cochrane reviews have been published.

References used in the text have been assessed according to their level of scientific evidence (Table 1), and guideline recommendations have been graded (Table 2) according to the Oxford Centre for Evidence-based Medicine Levels of Evidence (3). The aim of grading recommendations is to provide transparency between the underlying evidence and the recommendation given. As a result of the lack of randomised studies, the levels of evidence (LE) and grades of recommendation (GR) provided in the document are low.

Additionally, a quick reference guide is available. All texts can be viewed and downloaded for personal use at the society website: <http://www.uroweb.org/guidelines/online-guidelines/>.

Table 1: Level of evidence*

Level	Type of evidence
1a	Evidence obtained from meta-analysis of randomised trials
1b	Evidence obtained from at least one randomised trial
2a	Evidence obtained from one well-designed controlled study without randomisation
2b	Evidence obtained from at least one other type of well-designed quasi-experimental study
3	Evidence obtained from well-designed non-experimental studies, such as comparative studies, correlation studies and case reports
4	Evidence obtained from expert committee reports or opinions or clinical experience of respected authorities

*Modified from Sackett et al. (3).

Table 2: Grade of recommendation*

Grade	Nature of recommendations
A	Based on clinical studies of good quality and consistency addressing the specific recommendations and including at least one randomised trial
B	Based on well-conducted clinical studies, but without randomised clinical trials
C	Made despite the absence of directly applicable clinical studies of good quality

*Modified from Sackett et al. (3).

2.1 References

1. Pizzocaro G, Algaba F, Horenblas S, et al. EAU penile cancer guidelines 2009. *Eur Urol* 2010 Jun;57(6):1002-12.
<http://www.ncbi.nlm.nih.gov/pubmed/20163910>
2. National Cancer Institute. Penile Cancer Treatment (PDQ). Health Professional Version. US National Institutes of Health, 2008, pp. 1-13.
<http://www.cancer.gov/cancertopics/pdq/treatment/penile/healthprofessional/allpages>
3. Oxford Centre for Evidence-based Medicine Levels of Evidence (May 2009). Produced by Bob Phillips, Chris Ball, Dave Sackett, Doug Badenoch, Sharon Straus, Brian Haynes, Martin Dawes since November 1998. Updated by Jeremy Howick March 2009.
<http://www.cebm.net/index.aspx?o=1025> [Access date January 2012]

3. DEFINITION OF PENILE CANCER

Penile cancer is a relatively rare SCC. It usually originates in the epithelium of the inner prepuce and glans. It shares similar pathology and natural history with SCC of the oropharynx, female genitalia (cervix, vagina and vulva), and anus. Phimosis, poor hygiene, and smoking are the major risk factors for penile cancer. Typing has been done of the human papillomaviruses (HPVs) that are responsible for the sexual transmission of genital warts, condyloma acuminata, and SCC.

An improved understanding of the natural history of the disease, earlier diagnosis, better technology, research group collaboration, and centralisation of patients in centres of excellence has improved the cure rate for penile cancer from 50% in the 1990s to 80% in recent years.

4. EPIDEMIOLOGY

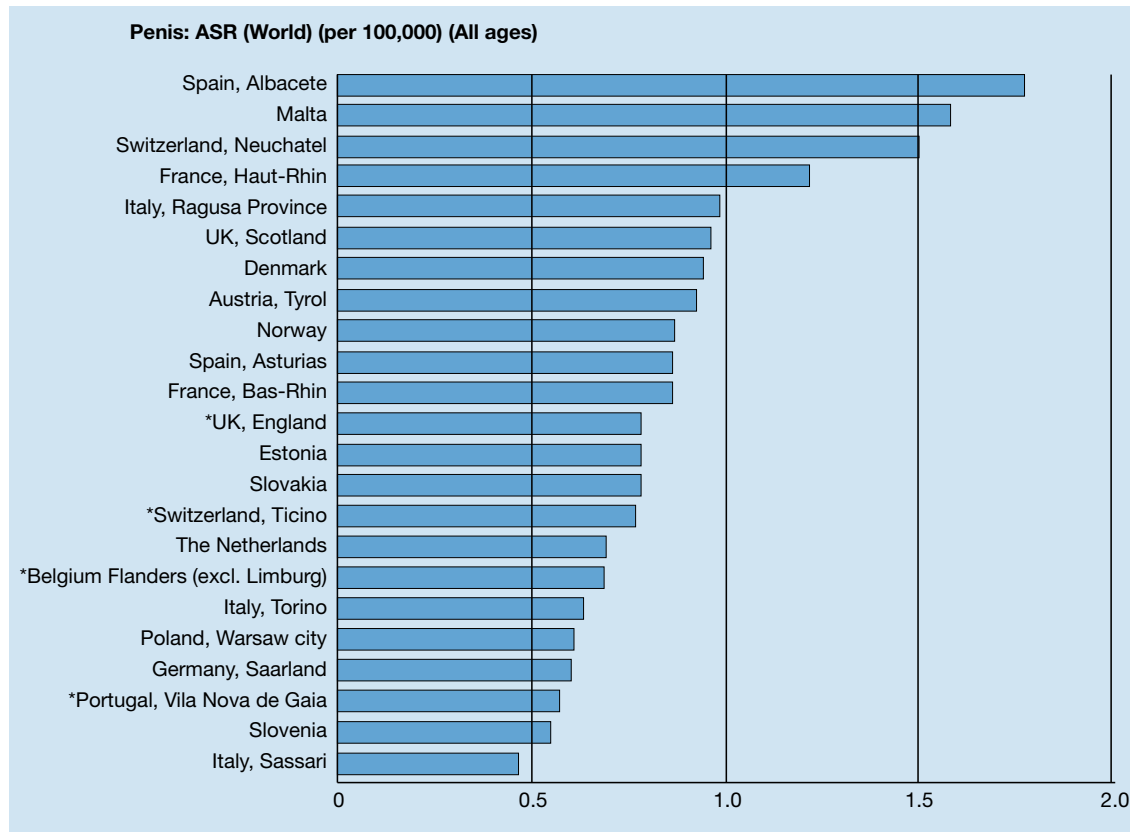
In Western countries, primary malignant penile cancer is uncommon, with an incidence of less than 1.00 per 100,000 males in Europe and the United States (1,2). However, there are significant geographical variations within Europe (Figure 1), reporting an incidence greater than 1.00 per 100,000 men (3). Incidence is also affected by race and ethnicity in North America (1), with the highest incidence of penile cancer found in white Hispanics (1.01 per 100,000), followed by Alaskan, Native/American Indians (0.77 per 100,000), Blacks (0.62 per 100,000) and white non-Hispanics (0.51 per 100,000).

In contrast, in the non-Western world, the incidence of penile cancer is much higher and can represent 10-20% of malignant diseases in men ranging from an age-adjusted incidence of 0.7-3 per 100,000 people in India to 8.3 per 100,000 men in Brazil, and even higher in Uganda, where it is the most commonly diagnosed cancer.

Important risk factors include social and cultural habits, and hygienic and religious practices (4). Penile carcinoma is rare in communities that practise circumcision in newborns or before puberty (Jews, Muslims, and the Ibos of Nigeria). Early circumcision reduces the risk of penile cancer by 3-5 times. Adult circumcision does not protect against penile cancer.

In the USA, the overall age-adjusted incidence rate decreased considerably between 1973 and 2002 from 0.84 per 100,000 in 1973-1982 to 0.69 per 100,000 in 1983-1992, and further to 0.58 per 100,000 in 1993-2002 (1). In European countries, the incidence during the 1980s and 1990s was stable or increased only slightly (2). Incidence increases with age (2); however, the disease has been reported in younger men and even in children in non-western countries (3).

Figure 1: Annual incidence rate (world standardised) by European region/country*



*From Parkin et al. (2003) (3).

4.1 References

1. Barnholtz-Sloan JS, Maldonado JL, Pow-sang J, et al. Incidence trends in primary malignant penile cancer. *Urol Oncol* 2007 Sep-Oct;25(5):361-7. <http://www.ncbi.nlm.nih.gov/pubmed/17826651>
2. ENCR (European Network of Cancer Registries). Eurocim version 4.0. European incidence database V2.2 (1999). Lyon, France: IARC, 2001. http://www.encl.com.fr/encl_EUROCIM1.htm
3. Parkin DM, Whelan SL, Ferlay J, et al. Cancer Incidence in Five Continents. Vol. VIII. IARC Scientific Publications. No. 155. Lyon, France: IARC, 2002. <http://www.iarc.fr/en/publications/pdfs-online/epi/sp155/index.php>
4. Misra S, Chaturvedi A, Misra NC. Penile carcinoma: a challenge for the developing world. *Lancet Oncol* 2004 Apr;5(4):240-7. <http://www.ncbi.nlm.nih.gov/pubmed/15050955>

5. RISK FACTORS AND PREVENTION

Risk factors for penile cancer were identified by the Karolinska Institute based on a Medline search of published literature from 1966 to 2000 (1). Strong risk factors (OR > 10) identified by case-control studies included (LE: 2a):

- Phimosis;
- Chronic inflammatory conditions, e.g. balanoposthitis, lichen sclerosus, and atrophicus (balanitis xerotica obliterans);
- Treatment with sporalene and ultraviolet A photochemotherapy.

Sexual history (multiple partners, early age of first intercourse) and a self-reported history of condylomata are associated with a 3-5-fold increased risk of penile cancer. Smoking is also a risk factor. Cervical cancer in female sexual partners is not consistently associated with penile cancer in their male partners.

In many case series, HPV DNA has been identified in 70-100% of intraepithelial neoplasia and in 40-50% of cases with invasive penile cancer. These results have been confirmed by a population-based case-control study (2). Among men not circumcised in childhood, phimosis was strongly associated with the development of invasive penile cancer (OR: 11.4; 95% CI: 5.0-25.9) and cigarette smoking was associated with a 4.5-fold increased risk (95% CI: 2.0-10.1). Human papillomavirus DNA was detected in 80% of tumour specimens and 69% were positive for HPV-16 (LE: 2a).

Smegma as a carcinogen has been clearly excluded (3). The risk of cancer of the vulva, vagina, penis, and anus is increased in patients with condyloma acuminata (4) (LE: 2b).

Human papillomavirus-16 and 18 have a causal role in 70% of cancers of the cervix, vagina, and anus and 40-50% of cancers of the vulva, penis, and oropharynx. Other cofactors are very likely to be necessary for progression from HPV infection to cancer (5). Verrucous carcinoma is not related to HPV infection (6).

In June 2006, the US Food and Drug Administration (FDA) licensed the first vaccine to prevent cervical cancer and other HPV-associated diseases in women (7). The vaccine protects against infection with HPV-6, 11, 16 and 18, which together are responsible for 70% of cervical cancers and 90% of genital warts.

Human papillomavirus is highly transmissible, with a peak incidence soon after the onset of sexual activity. The recommended age for vaccination in girls is 11-12 years (8), with catch-up vaccination recommended in females aged 13-26 years.

However, vaccination is not a substitute for routine cervical cancer screening and vaccinated women should continue to have cervical cancer screening. Vaccination against HPV has also been recommended in men (9). Although one study has found that mid-adult women (≥ 25 years) have a high level of acceptance of HPV vaccination (10), only 33% of men wanted the HPV vaccine, 27% did not, and 40% were undecided (11). It has been decided that vaccination in men must wait for results of female HPV vaccination (12).

Interestingly, the presence of high-risk HPV DNA in penile cancer does not compromise prognosis. An early study has found no difference between HPV DNA-negative and -positive patients for lymph node metastases and 10-year survival rate (13). In a more recent study (14), disease-specific 5-year survival in the high-risk HPV-negative group was 78% versus 93% in the high-risk HPV-positive group (log rank test $P = 0.03$). This suggests the presence of high-risk HPV confers a survival advantage in patients with penile cancer. The virus plays an important role in oncogenesis through interaction with oncogenes and tumour suppressor genes (P53 and Rb genes) (15).

5.1 References

1. Dillner J, von Krogh G, Horenblas S, et al. Etiology of squamous cell carcinoma of the penis. *Scand J Urol Nephrol Suppl* 2000;(205):189-93.
<http://www.ncbi.nlm.nih.gov/pubmed/11144896>
2. Daling JR, Madeleine MM, Johnson LG, et al. Penile cancer: importance of circumcision, human papillomavirus and smoking in situ and invasive disease. *Int J Cancer* 2005 Sep;116(4):606-16.
<http://www.ncbi.nlm.nih.gov/pubmed/15825185>
3. Van Howe RS, Hodges FM. The carcinogenicity of smegma: debunking a myth. *Eur Acad Dermatol Venereol* 2006 Oct;20(9):1046-54.
<http://www.ncbi.nlm.nih.gov/pubmed/16987256>
4. Nordenvall C, Chang ET, Adami HO, et al. Cancer risk among patients with condylomata acuminata. *Int J Cancer* 2006 Aug;119(4):888-93.
<http://www.ncbi.nlm.nih.gov/pubmed/16557590>
5. Muñoz N, Castelisague X, de Gonzalez AB, et al. HPV in the etiology of human cancer. *Vaccine* 2006 Aug;24(Suppl 3):S3/1-10.
<http://www.ncbi.nlm.nih.gov/pubmed/16949995>

6. Stankiewicz E, Kudahetti SC, Prowse DM, et al. HPV infection and immunochemical detection of cell-cycle markers in verrucous carcinoma of the penis. *Mod Pathol* 2009 Sep;22:1160-8.
<http://www.ncbi.nlm.nih.gov/pubmed/19465901>
7. Huang CM. Human papillomavirus and vaccination. *Mayo Clin Proc* 2008 Jun;83(6):701-6.
<http://www.ncbi.nlm.nih.gov/pubmed/18533087>
8. Markowitz LE, Dunne EF, Saraiya M, et al; Centers for Disease Control and Prevention (CDC); Advisory Committee on Immunization Practices (ACIP). Quadrivalent Human Papillomavirus Vaccine: recommendations of the Advisory Committee on Immunization Practices (ACIP). *MMWR Recomm Rep* 2007 Mar;56(RR-2):1-24.
<http://www.ncbi.nlm.nih.gov/pubmed/17380109>
9. Giuliano AR. Human papillomavirus vaccination in males. *Gynecol Oncol* 2007 Nov;107(2 Suppl 1): S24-S26.
<http://www.ncbi.nlm.nih.gov/pubmed/17938015>
10. Ferris DG, Waller JL, Owen A, et al. Midadult women's attitudes about receiving the prophylactic human papillomavirus vaccine. *J Low Genit Tract Dis* 2007 Jul;11(3):166-72.
<http://www.ncbi.nlm.nih.gov/pubmed/17596762>
11. Ferris DG, Waller JL, Miller J, et al. Men's attitudes toward receiving the human papillomavirus vaccine. *J Low Genit Tract Dis* 2008 Oct;12(4):276-81.
<http://www.ncbi.nlm.nih.gov/pubmed/18820541>
12. Gerend MA, Barley J. Human papillomavirus vaccine acceptability among young adult men. *Sex Transm Dis* 2009 Jan;36:58-62.
<http://www.ncbi.nlm.nih.gov/pubmed/18830138>
13. Bezerra AL, Lopes A, Santiago GH, et al. Human papillomavirus as a prognostic factor in carcinoma of the penis: analysis of 82 patients treated with amputation and bilateral lymphadenectomy. *Cancer*. 2001 Jun 15;91(12): 2315-21.
<http://www.ncbi.nlm.nih.gov/pubmed/11413520>
14. Lont AP, Kroon BK, Horenblas S, et al. Presence of high risk human papillomavirus DNA in penile carcinoma predicts favorable outcome in survival. *Int J Cancer* 2006 Sep;119(5):1078-81.
<http://www.ncbi.nlm.nih.gov/pubmed/16570278>
15. Kayes O, Ahmed HU, Arya M, et al. Molecular and genetic pathways in penile cancer. *Lancet Oncol* 2007 May;8(5):420-9.
<http://www.ncbi.nlm.nih.gov/pubmed/17466899>

6. TNM CLASSIFICATION AND PATHOLOGY

6.1 TNM classification

The new 2009 TNM classification for penile cancer (1) includes a change for the T1 category (Table 3). This classification needs a further update for the definition of the T2 category*. Two recent publications have shown that the prognosis for corpus spongiosum invasion is much better than for corpora cavernosa invasion (2,3).

Table 3: 2009 TNM clinical and pathological classification of penile cancer

Clinical classification	
T - Primary tumour	
TX	Primary tumour cannot be assessed
T0	No evidence of primary tumour
Tis	Carcinoma <i>in situ</i>
Ta	Non-invasive verrucous carcinoma, not associated with destructive invasion
T1	Tumour invades subepithelial connective tissue
T1a	Tumour invades subepithelial connective tissue without lymphovascular invasion and is not poorly differentiated or undifferentiated (T1G1-2)
T1b	Tumour invades subepithelial connective tissue without with lymphovascular invasion or is poorly differentiated or undifferentiated (T1G3-4)
T2 *	Tumour invades corpus spongiosum/corpora cavernosa
T3	Tumour invades urethra
T4	Tumour invades other adjacent structures
N - Regional lymph nodes	
NX	Regional lymph nodes cannot be assessed
N0	No palpable or visibly enlarged inguinal lymph node
N1	Palpable mobile unilateral inguinal lymph node
N2	Palpable mobile multiple or bilateral inguinal lymph nodes
N3	Fixed inguinal nodal mass or pelvic lymphadenopathy, unilateral or bilateral
M - Distant metastasis	
M0	No distant metastasis
M1	Distant metastasis
Pathological classification	
The pT categories correspond to the T categories. The pN categories are based upon biopsy or surgical excision.	
pN - Regional lymph nodes	
pNX	Regional lymph nodes cannot be assessed
pN0	No regional lymph node metastasis
pN1	Intranodal metastasis in a single inguinal lymph node
pN2	Metastasis in multiple or bilateral inguinal lymph nodes
pN3	Metastasis in pelvic lymph node(s), unilateral or bilateral or extranodal extension of regional lymph node metastasis
pM - Distant metastasis	
pM0	No distant metastasis
pM1	Distant metastasis
G - Histopathological grading	
GX	Grade of differentiation cannot be assessed
G1	Well differentiated
G2	Moderately differentiated
G3-4	Poorly differentiated/undifferentiated

Rees et al. (2) have investigated 72 patients with T2 tumours. Local recurrence (35% vs. 17%) and mortality (30% vs. 21%) rates were higher in patients with tunica or cavernosal involvement versus glands-only invasion after a mean follow-up of 3 years (LE: 2b). The authors have proposed defining T2a patients by spongiosum-only invasion and T2b patients by involvement of tunica or corpus cavernosum.

A retrospective analysis of the records of 513 patients treated between 1956 and 2006 has confirmed the above-mentioned difference between tumour invasion of the corpus spongiosum only versus corpus cavernosum (3). It also has confirmed that there are no differences in long-term survival between patients with T2 and T3 tumours, and no significant differences between N1 and N2 tumours in the 1987-2002 TNM classification (LE: 2a).

In the new UICC 2009 TNM classification (1), retroperitoneal node metastases are correctly and accurately defined as extraregional nodal and distant metastases. The difference between corpus spongiosum and corpora cavernosa invasion is not considered.

6.1.1 References

1. Sobin LH, Gospodariwics M, Wittekind C (eds). TNM Classification of Malignant Tumours. UICC International Union Against Cancer 7th edition, Willy-Blackwell, 2009 Dec; 239-42. <http://www.uicc.org/tnm/>
2. Rees RW, Freeman A, Borley N, et al. PT2 penile squamous cell carcinomas: cavernosus vs. spongiosus invasion. Eur Urol Suppl 2008;7(3):111 (abstract #163).
3. Leijte JA, Gallee M, Antonini N, et al. Evaluation of current (2002) TNM classification of penile carcinoma. J Urol 2008;180(3):933-8; discussion 938. <http://www.ncbi.nlm.nih.gov/pubmed/18635216>

6.2 Pathology

Squamous cell carcinoma accounts for more than 95% of cases of malignant disease of the penis. Malignant melanoma and basal cell carcinoma are much less common. It is not known how often SCC is preceded by premalignant lesions (1-4). Although SCC is the most common penile neoplasia, different types and varying growth patterns have been identified (5-7) (Tables 4 and 5).

Table 4: Premalignant lesions

Lesions sporadically associated with SCC of the penis
<ul style="list-style-type: none"> • Cutaneous horn of the penis • Bowenoid papulosis of the penis • Balanitis xerotica obliterans (lichen sclerosus et atrophicus)
Lesions at high risk of developing SCC of the penis (up to one-third transform to invasive SCC)
<ul style="list-style-type: none"> • Penile intraepithelial neoplasia (carcinoma <i>in situ</i>): erythroplasia of Queyrat and Bowen's disease

Table 5: Penile SCC

<p>Types of SCC</p> <ul style="list-style-type: none"> • Classic • Basaloid • Verrucous and its varieties: <ul style="list-style-type: none"> - Warty (condylomatous) carcinoma - Verrucous carcinoma - Papillary carcinoma - Hybrid verrucous carcinoma - Mixed carcinomas (warty basaloid and adenobasaloid carcinoma) • Sarcomatoid • Adenosquamous
<p>Growth patterns of SCC</p> <ul style="list-style-type: none"> • Superficial spread • Nodular or vertical-phase growth • Verrucous

Differentiation grading systems for SCC

- Broders' grading system (8)
- Maiche's system score (9)

6.2.1 **Penile biopsy**

There is no need for biopsy if:

- there is no doubt about the diagnosis and/or;
- treatment of the lymph nodes is postponed after treatment of the primary tumour and/or after histological examination of the sentinel node(s).

There is a need for histological confirmation if:

- there is doubt about the exact nature of the lesion (e.g. metastasis or melanoma) and/or;
- treatment of the lymph nodes is based on preoperative histological information (risk-adapted strategy).

In these cases an adequate biopsy is advised. When performing a biopsy, it is important to consider the findings from a study of biopsy size. Studies of biopsies with an average size of 0.1 cm found the following difficulties:

- difficulty in evaluating the extent of depth in 91% of biopsies;
- discordance between the grade at biopsy and in the final specimen in 30% of cases;
- failure to detect cancer in 3.5% of cases (1).

Thus, although a punch biopsy may be sufficient for superficial lesions, an excisional biopsy is preferred.

6.2.2 **Pathological categories**

Traditionally, SCC has been considered as superficial or invasive. However, Cubilla et al. (5) have divided penile carcinoma into four categories:

- superficial spreading;
- vertical growth;
- verrucous;
- multicentric.

Different types of growth pattern have different prognoses (10) and different ways of dissemination. The limits of partial surgical resection must therefore be set according to the growth pattern at the time of evaluation of the frozen sections (11). If the margins are studied following these criteria (including urethral and periurethral tissue), only 3-4 mm of tumour-free tissue is sufficient to consider the surgical margins to be negative (12). Basaloid SSC is a cellular subtype that is better recognised than before, and it is highly aggressive (13).

6.2.3 **Histology and metastatic risk**

Histological subtypes carry different risks of developing metastatic lymph nodes:

- Condylomatous: 18.2%;
- SCC: 56.7%;
- Sarcomatoid carcinoma: 89%.

Perineural (14) and lymphovascular invasion (14,15) are correlated with lymph node metastases, with 23.1% of positive lymph nodes associated with a nodular pattern, and 64.6% with an infiltrative pattern. Perineural invasion, lymphovascular invasion, and high histological grade appear to be the most important adverse pathological prognostic factors, reaching 80% mortality (15).

6.2.4 **References**

1. Velazquez EF, Barreto JE, Rodriguez I, et al. Limitations in the interpretation of biopsies in patients with penile squamous cell carcinoma. *Int J Surg Pathol* 2004 Apr;12(2):139-46.
<http://www.ncbi.nlm.nih.gov/pubmed/15173919>
2. Velazquez EF, Cubilla AL. Lichen sclerosus in 68 patients with squamous cell carcinoma of the penis: frequent atypias and correlation with special carcinoma variants suggests a precancerous role. *Am Surg Pathol* 2003 Nov;27:1448-53.
<http://www.ncbi.nlm.nih.gov/pubmed/14576478>
3. Teichman JM, Thompson IM, Elston DM. Non infectious penile lesions. *Am Fam Physician* 2010 Jan;81(2):167-74.
<http://www.ncbi.nlm.nih.gov/pubmed/20082512>

4. Renand-Vilmer C, Cavalier-Balloy B, Verola O, et al. Analysis of alterations adjacent to invasive squamous cell carcinoma of the penis and their relationship with associated carcinoma. *J Am Acad Dermatol* 2010 Feb;62(2):284-90.
<http://www.ncbi.nlm.nih.gov/pubmed/20115951>
5. Cubilla AL, Barreto J, Caballero C, et al. Pathologic features of epidermoid carcinoma of the penis. A prospective study of 66 cases. *Am J Surg Pathol* 1993 Aug;17(8):753-63.
<http://www.ncbi.nlm.nih.gov/pubmed/8338190>
6. Chaux A., Soares F, Rodriguez I, et al. Papillary squamous cell carcinoma, not otherwise specified (NOS) of the penis: clinical pathologic features differential diagnosis and outcome of 35 cases. *Am J Surg Pathol* 2010 Feb;34(2):223-30.
<http://www.ncbi.nlm.nih.gov/pubmed/20061934>
7. Ranganath R, Singh SS, Sateeshan B. Sarcomatoid carcinoma of the penis: clinico pathological features. *Indian J Urol* 2008 Apr;24(2):267-8.
<http://www.ncbi.nlm.nih.gov/pubmed/19468412>
8. Broders AC. Squamous cell epithelioma of the skin: A study of 256 cases. *Ann Surg* 1921 Feb;73(2):141-60.
<http://www.ncbi.nlm.nih.gov/pubmed/17864409>
9. Maiche AG, Pyrhönen S, Karkinen M. Histological grading of squamous cell carcinoma of the penis: a new score system. *Br J Urol* 1991 May;67(5):522-526.
<http://www.ncbi.nlm.nih.gov/pubmed/1710163>
10. Villavicencio H, Rubio-Briones J, Regalado R, et al. Grade, local stage and growth pattern as prognostic factors in carcinoma of the penis. *Eur Urol* 1997;32(4):442-7.
<http://www.ncbi.nlm.nih.gov/pubmed/9412803>
11. Velazquez EF, Soskin A, Bock A, et al. Positive resection margins in partial penectomies: sites of involvement and proposal of local routes of spread of penile squamous cell carcinoma. *Am J Surg Pathol* 2004 Mar;28(3):384-9.
<http://www.ncbi.nlm.nih.gov/pubmed/15104302>
12. Minhas S, Kayes O, Hegarty P, et al. What surgical resection margins are required to achieve oncological control in men with primary penile cancer? *BJU Int* 2005 Nov;96(7):1040-3.
<http://www.ncbi.nlm.nih.gov/pubmed/16225525>
13. Cubilla AL, Reuter V, Velazquez E, et al. Histologic classification of penile carcinoma and its relation to outcome in 61 patients with primary resection. *Int J Surg Pathol* 2001 Apr;9(2):111-20.
<http://www.ncbi.nlm.nih.gov/pubmed/11484498>
14. Cubilla AL. The role of pathologic prognostic factors in squamous cell carcinoma of the penis. *World J Urol* 2009 Apr;27:169-77.
<http://www.ncbi.nlm.nih.gov/pubmed/18766352>
15. Chaux A, Reuter V, Lezcano G, et al: Comparison of morphologic features and outcome of resected recurrent and non recurrent squamous cell carcinoma of the penis. A study of 81 cases. *Am J Surg Pathol* 2009 Sep;33(9):1299-306.
<http://www.ncbi.nlm.nih.gov/pubmed/19471153>

7. DIAGNOSIS AND STAGING

The primary tumour and regional lymph nodes must be staged correctly to enable the most appropriate treatment.

7.1 Primary lesion

Physical examination of a patient with penile cancer includes:

- diameter of the penile lesion or suspicious areas;
- location of lesion on the penis;
- number of lesions;
- morphology of lesion: papillary, nodular, ulcerous or flat;
- relationship of lesion to other structures, e.g. submucosa, tunica albuginea, and urethra;
- corpus spongiosum and corpus cavernosum;
- colour and boundaries of lesion;
- penis length.

Accurate histological diagnosis and staging of the primary tumour and regional nodes are necessary for making treatment decisions (1). In a small series, physical examination alone proved more reliable than imaging with ultrasound (US) to judge infiltration into the corpora cavernosa (2). Artificial erection with prostaglandin E1 (alprostadil) in combination with magnetic resonance imaging (MRI) is helpful in excluding tumour invasion into the corpora cavernosa, and deciding whether limited surgery (e.g. glansectomy) can be performed (3,4).

7.2 Regional lymph nodes

7.2.1 Lymphatic drainage of the penis

Primary lymphatic drainage of penile cancer occurs to the inguinal nodes. A recent single photon emission computed tomography (CT) study (5) has shown that all sentinel nodes were located in the superior and central inguinal zones, with most found in the medial superior zone. No lymphatic drainage was observed from the penis to the two inferior regions of the groin, and no direct drainage to the pelvic nodes was visualised. These findings confirm earlier studies (6-8).

7.2.2 Non-palpable nodes

Careful inguinal physical examination is necessary. In the absence of palpable abnormalities, inguinal US (7.5 MHz) can reveal abnormal nodes and can be used as a guide for fine-needle aspiration biopsy (FNAB) (9,10). A sentinel node biopsy (SNB) (8) was not recommended until 10 years ago because of a high rate of false-negative results (25%, range: 9-50%) (11). However, recent reports have suggested that dynamic sentinel node biopsy (DSNB) using isosulphan blue and/or Tc99m-colloid sulphur improves survival compared to a 'wait-and-see' policy (LE: 3), and reduces side effects compared to those with inguinal lymphadenectomy (LAD) (12,13). Prospective studies on DSNB have obtained 100% specificity and 95% sensitivity (14-18) (LE: 2b). As analysis of dynamic SNB is operator-dependent (19) and relies on experience, the procedure is only available in a few centres. Nevertheless, a two-centre evaluation of DSNB has demonstrated the reproducibility of the technique, with a short learning curve (20).

Iliac lymph node metastases do not occur in the absence of inguinal metastases (19), therefore pelvic CT is not necessary in patients with no inguinal node metastases.

Conventional CT or MRI cannot detect micrometastases (21). No further studies have been performed to confirm the promising results reported with nanoparticle-enhanced MRI (22), but positron emission tomography (PET/CT) can detect pelvic and distant metastases (23).

7.2.3 Risk factors and metastasis detection

Patients with T1G1 category tumours do not need further therapy after local treatment, but in 13% up to 29% of cases those with intermediate T1G2 tumours can develop lymph node metastases (23,24). The risk for lymph node involvement can be evaluated by T and G categories and from other tumour characteristics.

Risk factors identified from retrospective studies include several pathological parameters, such as: perineural invasion, lymphovascular invasion, tumour depth or thickness, anatomical site, size and growth pattern, infiltrative front of invasion, positive resection margins, and urethral invasion (25). Several large series have identified lymphovascular invasion alone, lymphovascular invasion with absence of koilocytosis, lymphovascular invasion plus palpable inguinal nodes, and high histological grade plus perineural invasion as the most important risk factors (26-28).

Finally, the most adverse pathological prognostic factors appears to be lymphovascular invasion and high histological grade (28).

Nomograms have been used to evaluate the predictive value of clinical and pathological indicators, but pathological parameters and nomograms (23-30) cannot achieve more than 80% prediction (23-30). Only ¹⁸F-fluorodeoxyglucose (FDG) PET/CT can improve the detection of early regional and distant metastases (31).

7.2.4 Palpable nodes

Palpable nodes should be described as follows:

- node consistency;
- node location;
- diameter of nodes or masses;
- unilateral or bilateral location;
- number of nodes identified in each inguinal area;
- mobile or fixed nodes or masses;
- relationship (e.g. infiltration or perforation) to other structures, such as the skin or cooper ligament;
- oedema of leg and/or scrotum.

Palpable lymph node metastases can be diagnosed using percutaneous FNAB (cytology and/or histology

punction). At the time of diagnosis of penile cancer, as many as 50% of palpable inguinal nodes will be reactive for concomitant infection rather than due to lymph node metastasis. In contrast, during follow-up, nearly 100% of enlarged nodes are metastatic (32) (LE: 2b).

Thus, after allowing time for inflammatory reactions to subside, regional nodes should be evaluated within a few weeks after treatment of the primary tumour. Histological diagnosis can be done using fine-needle aspiration, tissue core, or open biopsy, according to the preference of the pathologist (32,33) (LE: 2b). In the case of a negative biopsy and clinically suspicious nodes, a repeat or excisional biopsy should be performed.

7.2.5 Conclusion

Imaging techniques (e.g. CT and MRI) are widely used, but they are only useful for staging patients with centrimetrical, or lymph node metastases ≥ 1 cm. So far, no current imaging modality can identify microscopic invasion. Imaging using ^{18}F FDG-PET/CT have some minor limitations (0.5 cm) (31). The use of molecular biological techniques is experimental (37-41).

7.3 Distant metastases

An assessment of distant metastases should be performed in patients with positive inguinal nodes (23-35) (LE: 2b). PET/CT is reliable for identification of pelvic and distant metastases in patients with positive inguinal nodes (31). Routine blood analysis and plain radiography chest are usually performed, despite the fact that they have limited use and lung metastases are exceptionally rare. The value of SCC antigen determination as a staging tool is unclear and therefore not recommended for routine use (37). Biological studies are investigational (38-41).

A diagnostic schedule is summarised below.

7.4 Guidelines for the diagnosis and staging of penile cancer

Recommendations	GR
Primary tumour	C
Physical examination, recording morphological and physical characteristics of the lesion. Cytological and/or histological diagnosis.	
Inguinal lymph nodes	C
Physical examination of both groins, recording nodal morphological and physical characteristics: - If nodes are non-palpable, DSNB is indicated; if DSNB not available, US-guided FNAC/risk factors. - If nodes are palpable, FNAC for cytological diagnosis.	
Regional metastases (inguinal and pelvic nodes)	C
A pelvic CT/PET/CT is indicated in patients with metastatic inguinal nodes.	
Distant metastases (beside inguinal and pelvic nodes)	C
PET/CT also allows evidence of distant metastasis. If PET/CT is not available, abdominal CT and plain radiography chest are advisable, and in symptomatic M1 patients a bone scan is also advisable.	
Biological laboratory	C
Determinations for penile cancer are investigational and not for clinical use.	

CT = computed tomography; DSNB = dynamic sentinel node biopsy; FNAC = fine-needle aspiration cytology; PET = positron emission tomography.

7.5 References

- Solsona E, Iborra I, Rubio J, et al. Prospective validation of the association of local tumor stage grade as a predictive factor for occult lymph node micrometastasis in patients with penile carcinoma and clinically negative inguinal lymph nodes. J Urol 2001 May;165(5):1506-9.
<http://www.ncbi.nlm.nih.gov/pubmed/11342906>
- Horenblas S. The accuracy of ultrasound in squamous cell carcinoma. In: The Management of Penile Squamous Cell Carcinoma. A Retrospective and Prospective Study. Thesis. Amsterdam Zoetermeer: BV Export drukkerij, 1993, pp. 71-83.
- Kayes O, Minhas S, Allen C, et al. The role of magnetic resonance imaging in the local staging of penile cancer. Eur Urol 2007 May;51(5):1313-8.
<http://www.ncbi.nlm.nih.gov/pubmed/17113213>

4. Lont AP, Besnard AP, Gallee MP, et al. A comparison of physical examination and imaging in determining the extent of primary penile carcinoma. *BJU Int* 2003 Apr;91(6):493-5.
<http://www.ncbi.nlm.nih.gov/pubmed/12656901>
5. Leijte JA, Valdés Olmos RA, Nieweg OE, et al. Anatomical mapping of lymphatic drainage in penile carcinoma with SPECT-CT: implications for the extent of inguinal lymph node dissection. *Eur Urol* 2008 Oct;54(4):885-90.
<http://www.ncbi.nlm.nih.gov/pubmed/18502024>
6. Daseier EH, Anson BJ, Reimann AF. Radical excision of the inguinal and iliac lymph glands: a study based upon 450 anatomical dissections and upon supportive clinical observations. *Surg Gynecol Obstet* 1948 Dec;87(6):679-94. [no abstract available]
<http://www.ncbi.nlm.nih.gov/pubmed/18120502>
7. Cabanas RM. An approach for the treatment of penile carcinoma. *Cancer* 1977 Feb;39(2):456-66.
<http://www.ncbi.nlm.nih.gov/pubmed/837331>
8. Catalona WJ. Modified inguinal lymphadenectomy for carcinoma of the penis with preservation of saphenous veins: technique and preliminary results. *J Urol* 1988 Oct;140(4):306-10.
<http://www.ncbi.nlm.nih.gov/pubmed/3398125>
9. Saisorn I, Lawrentschut N, Leewansangtong S, et al. Fine-needle aspiration cytology predicts inguinal lymph node metastases without antibiotic pretreatment in penile carcinoma. *BJU Int* 2006 Jun;97(6):1125-8.
<http://www.ncbi.nlm.nih.gov/pubmed/16686716>
10. Kroon BK, Horenblas S, Deurloo EE, et al. Ultrasonography-guided fine-needle aspiration cytology before sentinel node biopsy in patients with penile carcinoma. *BJU Int* 2005 Mar;95(4):517-21.
<http://www.ncbi.nlm.nih.gov/pubmed/15705071>
11. Pettaway CA, Pisters LL, Dinney CPN, et al. Sentinel lymph node dissection for penile carcinoma: the MD Anderson Cancer Center Experience. *J Urol* 1995 Dec;154(6):1999-2003.
<http://www.ncbi.nlm.nih.gov/pubmed/7500444>
12. Horenblas S. Surgical management of carcinoma of the penis and scrotum. In: Petrovich Z, Baert L, Brady LW (eds). *Medical Radiology. Diagnostic Imaging and Radiation Oncology. Carcinoma of the Kidney and Testis, and Rare Urologic Malignancies*. Berlin: Springer-Verlag, 1999, pp. 341-54.
13. Pettaway CA, Jularbal FA, Babaian RJ, et al. Intraoperative lymphatic mapping to detect inguinal metastases in penile carcinoma: results of a pilot study. *J Urol* 1999;161:159 (abstr #612).
14. Akduman B, Fleshner NE, Ehrlich L, et al. Early experience in intermediate-risk penile cancer with sentinel node identification using the gamma probe. *Urology* 2001 Jul;58(1):65-8.
<http://www.ncbi.nlm.nih.gov/pubmed/11445481>
15. Perdonà S, Gallo L, Claudio L, et al. [Role of crural inguinal lymphadenectomy and dynamic sentinel lymph node biopsy in lymph node staging in squamous-cell carcinoma of the penis. Our experience.] *Tumori* 2003 Jul-Aug;89(4 Suppl):276-9. [Article in Italian]
<http://www.ncbi.nlm.nih.gov/pubmed/12903620>
16. Tanis PJ, Lont AP, Meinhardt W, et al. Dynamic sentinel node biopsy for penile cancer: reliability of a staging technique. *J Urol* 2002 Jul;168(1):76-80.
<http://www.ncbi.nlm.nih.gov/pubmed/12050496>
17. Wawroschek F, Vogt H, Bachter D, et al. First experience with gamma probe guided sentinel lymph node surgery in penile cancer. *Urol Res* 2000 Aug;28(4):246-9.
<http://www.ncbi.nlm.nih.gov/pubmed/11011963>
18. Lont AP, Horenblas S, Tanis PJ, et al. Management of clinically node negative penile carcinoma: improved survival after the introduction of dynamic sentinel node biopsy. *J Urol* 2003 Sep;170(3):783-6.
<http://www.ncbi.nlm.nih.gov/pubmed/12913697>
19. Leijte JA, Kroon BK, Valdés Olmos RA, et al. Reliability and safety of current dynamic sentinel node biopsy for penile carcinoma. *Eur Urol* 2007 Jul;52(1):170-7.
<http://www.ncbi.nlm.nih.gov/pubmed/17316967>
20. Leijte JA, Hughes B, Graafland NM, et al. Two-center evaluation of dynamic sentinel node biopsy for squamous cell carcinoma of the penis. *J Clin Oncol* 2009 Jul; 27:3325-9.
<http://www.ncbi.nlm.nih.gov/pubmed/19414668>
21. Mueller-Lisse UG, Scher B, Scherr MK, et al. Functional imaging in penile cancer: PET/computed tomography, MRI, and sentinel lymph node biopsy. *Curr Opin Urol* 2008 Jan;18(1):105-10.
<http://www.ncbi.nlm.nih.gov/pubmed/18090498>

22. Tabatabaei S, Harisinghani M, McDougal WS. Regional lymph node staging using lymphotropic nanoparticle enhanced magnetic resonance imaging with ferumoxtran-10 in patients with penile cancer. *J Urol* 2005 Sep;174:923-7; discussion 927.
<http://www.ncbi.nlm.nih.gov/pubmed/16093989>
23. Schelenker B, Tieki A, Gratzke C, et al. Intermediate differentiated invasive (pT1G2) penile cancer oncological outcome and follow-up. *Urol Oncol* 2011 Nov;29(6):782-7.
<http://www.ncbi.nlm.nih.gov/pubmed/19945307>
24. Hughes BE, Leijte JA, Kroon BK, et al. Lymph Node Metastasis in Intermediate-Risk Penile Squamous Cell Cancer: A Two-Centre Experience. *Eur Urol*. 2010 Apr;57(4):688-92.
<http://www.ncbi.nlm.nih.gov/pubmed/19647926>
25. Lopes A, Hidalgo GS, Kowalski LP, et al. Prognostic factors in carcinoma of the penis: multivariate analysis of 145 patients treated with amputation and lymphadenectomy. *J Urol* 1996 Nov;156(5):1637-42.
<http://www.ncbi.nlm.nih.gov/pubmed/8863559>
26. Ornellas AA, Nóbrega BL, Wei Kin Chin E, et al. Prognostic factors in invasive squamous cell carcinoma of the penis: analysis of 196 patients treated at the Brazilian National Cancer Institute. *J Urol* 2008 Oct;180(4):1354-9.
<http://www.ncbi.nlm.nih.gov/pubmed/18707720>
27. Velazquez EF, Ayala G, Liu H, et al. Histologic grade and perineural invasion are more important than tumor thickness as predictor of nodal metastasis in penile squamous cell carcinoma invading 5 to 10 mm. *Am J Surg Pathol* 2008 Jul;32(7):974-9.
<http://www.ncbi.nlm.nih.gov/pubmed/18460979>
28. Cubilla AL. The role of pathologic prognostic factors in squamous cell carcinoma of the penis. *World J Urol* 2009 Apr;27(2):169-77.
<http://www.ncbi.nlm.nih.gov/pubmed/18766352>
29. Chaux A, Caballero C, Soares F, et al. The prognostic index: a useful pathologic guide for prediction of nodal metastases and survival in penile squamous cell carcinoma. *Am J Surg Pathol* 2009 Jul;33(7):1049-57.
<http://www.ncbi.nlm.nih.gov/pubmed/19384188>
30. Ficarra V, Zattoni F, Artibani W, et al; GUONE Penile Cancer Project Members. Nomogram predictive of pathological inguinal lymph nodes involvement in patients with squamous cell carcinoma of the penis. *J Urol* 2006 Jun;175(6):2103-8.
<http://www.ncbi.nlm.nih.gov/pubmed/16697813>
31. Graafland NM, Leijte JA, Valdes Olmos RA, et al. Scanning with 18F-FDG-PET/TC for detection of pelvic nodal involvement in inguinal node positive penile carcinoma. *Eur Urol* 2009 Aug;56(2):339-45.
<http://www.ncbi.nlm.nih.gov/pubmed/19477581>
32. Horenblas S, Van Tinteren H, Delamarre JFM, et al. Squamous cell carcinoma of the penis. III. Treatment of regional lymph nodes. *J Urol* 1993 Mar;149(3):492-7.
<http://www.ncbi.nlm.nih.gov/pubmed/8437253>
33. Ornellas AA, Seixas AL, Marota A, et al. Surgical treatment of invasive squamous cell carcinoma of the penis: retrospective analysis of 350 cases. *J Urol* 1994 May;151(5):1244-9.
<http://www.ncbi.nlm.nih.gov/pubmed/7512656>
34. Pizzocaro G, Piva L, Nicolai N. Treatment of lymphatic metastasis of squamous cell carcinoma of the penis: experience at the National Tumor Institute of Milan. *Arch Ital Urol Androl* 1996 Jun;68(3):169-72. [Article in Italian]
<http://www.ncbi.nlm.nih.gov/pubmed/8767505>
35. Senthil Kumar MP, Ananthkrishnan N, Prema V. Predicting regional node metastasis in carcinoma of the penis: a comparison between fine-needle aspiration cytology, sentinel lymph node biopsy and medial inguinal lymph node biopsy. *Br J Urol* 1998 Mar;81(3):453-7.
<http://www.ncbi.nlm.nih.gov/pubmed/9523669>
36. Skoog L, Collins BT, Tani E, et al. Fine-needle aspiration cytology of penile tumors. *Acta Cytol* 1998 Mar-Apr;42(2):1336-40.
<http://www.ncbi.nlm.nih.gov/pubmed/9850639>
37. Laniado ME, Lowdell C, Mitchell H, et al. Squamous cell carcinoma antigen: a role in the early identification of nodal metastases in men with squamous cell carcinoma of the penis. *BJU Int* 2003 Aug;92(3):248-50.
<http://www.ncbi.nlm.nih.gov/pubmed/12887477>

38. Lopes A, Bezena AL, Pinto CA, et al. p53 as a new prognostic factor for lymph node metastasis in penile carcinoma: analysis of 82 patients treated with amputation and bilateral lymphadenectomy. *J Urol* 2002 Jul;168(1):81-6.
<http://www.ncbi.nlm.nih.gov/pubmed/12050497>
39. Kayes O, Ahmed HU, Arya M, et al. Molecular and genetic pathways in penile cancer. *Lancet Oncol* 2007 May;8(5):420-9.
<http://www.ncbi.nlm.nih.gov/pubmed/17466899>
40. Zhu Y, Zhang SL, Ye DW, et al. Predicting pelvic lymph node metastases in penile cancer patients: a comparison of computed tomography, Cloquet's node, and disease burden of inguinal lymph nodes. *Onkologie* 2008 Feb;31(1-2):37-41.
<http://www.ncbi.nlm.nih.gov/pubmed/18268397>
41. Zhu Y, Zhou XY, Yao XO, et al. The prognostic significance of p53, Ki-67, epithelial cadherin and matrix metallo proteinase-9 in penile squamous cell carcinoma treated with surgery. *BJU Int* 2007 Jul;100(1):204-8.
<http://www.ncbi.nlm.nih.gov/pubmed/17433031>

8. TREATMENT

The primary tumour and regional lymph nodes are usually treated separately. Although it is important to avoid overtreatment, which can lead to loss of penile tissue and adverse effects of an unnecessary lymphadenectomy, it is essential to remove all cancerous tissue with healthy margins.

8.1 Primary tumour

Guidelines on treatment strategies for primary tumour in penile cancer are outlined in Table 6. For small lesions, a penis-preserving strategy is recommended (GR: B). There is a variety of treatment modalities, which have not been compared in a scientifically rigorous manner, and providing recommendations based on published data is therefore difficult. However, treatment choice is influenced by tumour size, its position on the glans or in the corpora cavernosa, and experience of the treating urologist. There are no documented differences in the local recurrence rate between surgery, laser therapy, and radiotherapy. Although conservative surgery improves quality of life, the risk of local recurrence is higher than after ablative surgery (27% vs. 5%). The pathological assessment of surgical margins is essential to guarantee tumour-free margins (1). Tumour-positive margins lead inevitably to local recurrence. Total removal of the glans (glansectomy) and prepuce does have the lowest recurrence rate among the treatment modalities for small penile lesions (2%) (2).

8.1.1 Categories Tis, Ta, and T1a

Superficial lesions can be treated with one of the following penis-sparing techniques:	LE
Local excision with (or without) circumcision.	3
Laser therapy with CO ₂ laser (peniscopically controlled) or neodymium:yttrium-aluminium-garnet (Nd:YAG) laser (3-5). Small recurrences can be retreated in the same way.	2b
Mohs' micrographic surgery (for verrucous carcinoma) (6).	3
Photodynamic and topical therapy with 5-fluorouracil (5-FU) or 5% imiquimod cream and other agents have been reported for superficial lesions with relatively high recurrence rates (7).	4

8.1.2 Category T1b tumours of the glans with deeper infiltration (> 1 mm)

These tumours can be treated with the following techniques:	LE
Wide local (laser) excision plus reconstructive surgery or total glans resurfacing with or without skin transplantation (8).	2b
Neoadjuvant chemotherapy [vinblastine, bleomycin, and methotrexate (VBM)] followed by CO ₂ laser excision and spontaneous glans re-epithelialisation (3).	2b
Radiotherapy (see section 8.1.7).	
Glansectomy (2,8-11).	2b

Conservative treatment may be less suitable in cases of multifocal lesions, which are responsible for 15% of recurrences. Total treatment of the glans surface combined with concomitant circumcision is recommended to avoid multiple recurrences (3) (GR: C).

Negative surgical margins are imperative when using penile-conserving treatments. Pathological assessment of the surgical margins is recommended (GR: C). In general, a margin of 3 mm is considered safe (1).

8.1.3 **Category T2 (limited to the glans)**

Total glansectomy, with or without resurfacing of the corporeal heads, is recommended (8,10) (LE: 2b; GR: B). Radiotherapy is also an option (see section 8.1.7). Partial amputation should be considered in patients who are unfit for more conservative reconstructive surgery (11) (GR: C).

8.1.4 **Local disease recurrence after conservative surgery**

A second conservative procedure is advised if there is no corpus cavernosum invasion (2-8) (GR: C). If there is a large or deep infiltrating recurrence, partial or total amputation is inevitable (11) (GR: B). For those cases a total phallic reconstruction should be considered (12,13).

8.1.5 **Category T2 with invasion into the corpus cavernosum**

Partial amputation with a tumour-free margin is considered standard treatment (11) (GR: B). A surgical margin of 5-10 mm is considered safe (1). Reconstruction may alleviate the mutilation (10,12,13).

8.1.6 **Categories T3 and T4**

These categories of patients are rare (e.g. 5% in Europe and 13% in Brazil) (13). Total penectomy with perineal urethrostomy is standard surgical treatment for T3 tumours (14) (GR: B). Spatulating the urethra is helpful in preventing stenosis. In more advanced disease (T4), neoadjuvant chemotherapy is advised, followed by surgery in responding patients (as for management of patients with fixed or relapsed inguinal nodes (see section 8.2.4) (GR: B). Otherwise, adjuvant chemotherapy or consolidating radiation is advised (GR: C; see sections 8.2.4 and 8.1.7).

8.1.7 **Radiotherapy**

Radiotherapy of the primary tumour is an alternative organ-preserving approach with good results in selected patients with T1-2 lesions < 4 cm in diameter (15-18) (LE: 2b). Best results have been obtained with brachytherapy with local control rates ranging from 70-90% (15,17). Patients with lesions > 4 cm are not candidates for brachytherapy.

A minimum dose of 60 Gy is given for external radiotherapy combined with a brachytherapy boost, or brachytherapy alone (15-18). The penile preservation rate after radiotherapy is approximately 80%. Local failure rates after radiotherapy are higher than after partial penectomy, but salvage surgery can restore local control (16). The following complications are the most prevalent: urethral stenosis (20-35%), glans necrosis (10-20%), and late fibrosis of the corpora cavernosa (18) (LE: 3).

No scientifically sound recommendations can be given regarding surgical procedures versus radiotherapy. Institutional experience and available techniques play an important role in decision making.

8.1.8 **Guidelines for treatment strategies for penile cancer**

Table 6 provides a graded treatment schedule, also including the level of the underlying evidence on which the recommendations are based.

Table 6: Treatment strategies for penile cancer

Primary tumour	Conservative treatment is to be considered whenever possible	LE	GR
Category Tis, Ta, T1a (G1, G2)	CO ₂ or Nd:YAG laser surgery, wide local excision, glans resurfacing, or glans resection, depending on size and location of the tumour.	2b	C
	Mohs' micrographic surgery or photodynamic therapy for well differentiated superficial lesions (Tis, G1 Ta).	3	C
Category: T1b (G3) and T2 (glans only)	Glansectomy, with or without tips amputation or reconstruction.	2b	B
Category T2 (invasion of the corpora)	Partial amputation.	2b	B
Category T3 (invasion of urethra)	Total amputation with perineal urethrostomy.	2b	B

Category T4 (other adj. structures)	Eligible patients: neoadjuvant chemotherapy followed by surgery in responders. Alternative: external radiation.	3	C
Local disease recurrence after conservative therapy	Salvage surgery, consisting of penis-sparing treatment in small recurrences.	2b	B
	Larger recurrence: some form of amputation.	2b	B
Radiotherapy	Organ-preserving treatment in selected patients with T1-T2 of glans or coronal sulcus, lesions < 4 cm.	2b	B
Chemotherapy	Neoadjuvant, before surgery.	3	C
	Palliation in advanced or metastatic disease.	3	C

CO₂ = carbon dioxide; Nd:YAG = neodymium:yttrium-aluminum-garnet.

8.2 Regional lymph nodes

Guidelines on treatment strategies for nodal metastases are presented in section 8.2.7. Lymphadenectomy is the treatment of choice for patients with inguinal lymph node metastases (GR: B). The procedure requires careful skin-flap management, meticulous lymph node dissection, prophylactic antibiotics, compression stockings, and early ambulation. Prolonged lymph leakage, leg and scrotal lymphoedema, skin-flap necrosis, and wound infection can occur in 30-70% of patients (14) (LE: 2b). Recent studies have shown a decrease in complications, which suggests that these procedures should be done by experienced surgeons (19).

8.2.1 Surveillance

Surveillance can be recommended only in patients with Tis, Ta, and T1G1 tumours (14,19,20).

8.2.2 Management of patients with non-palpable inguinal nodes

All non-invasive diagnostic procedures miss approximately 20% of microscopic metastases. Also, the sensitivity of a published nomogram does not exceed 80% (21) (LE: 2b). Various risk factors have been helpful in stratifying node-negative patients for lymph node dissection (14,19-21) (LE: 2b). This approach was the basis for the 2004 guideline recommendations for the management of clinically node-negative patients (22). In centres without sentinel node diagnostics, these recommendations can still be useful. In addition, T1G2 tumours should be considered intermediate risk, based on a recent analysis (23). The experience from Brazil can be used as a gold standard for survival rates that can only be attained by surgery (14,19). Only DSNB has better sensitivity (94%) (24) (LE: 2b).

To identify the sentinel nodes reliably, preoperative mapping is essential. Tc99m nanocolloid is injected the day before surgery, patent blue is injected, and a γ -ray detection probe is used intraoperatively. Complete inguinal LAD is performed only in tumour-positive patients. The current protocol has a sensitivity of 95% (24). The technique is now reproducible with a short learning curve (25) (GR: B).

Considering the rarity of the disease and possible improvements in diagnosis and treatment, centralisation of patients is recommended. Centralisation of patients with penile SCC in 10 centres in the United Kingdom allowed improvement in the cure of the disease within a few years (26).

8.2.3 Management of patients with palpable inguinal nodes

US-guided FNAB provides an excellent, rapid, and easy way to detect metastatic nodal involvement (27) (LE: 3). In suspected cases with tumour-negative findings, various strategies can be followed:

- (1) antibiotics are given;
- (2) FNAB is repeated;
- (3) suspected nodes are surgically removed;
- (4) inguinal LAD is performed. Dynamic sentinel node biopsy is not reliable in patients with palpable suspected nodes and should not be used (28) (LE: 3); DSNB can be used for the clinically uninvolved side and LAD is performed at the tumour-positive sites. Inguinal LAD has been shown to have significant morbidity and it is to be limited to positive sides.

In advanced cases, reconstructive surgery is often necessary for primary wound closure (29).

Modified inguinal LAD is associated with less morbidity, but reducing the field of dissection increases the possibility of false-negative results. Current knowledge on lymphatic drainage of the penis suggests that modified LAD should dissect at least the central and both superior Daseler's zones (30,31) (LE: 3).

There is no direct lymphatic drainage from penile tumours to the pelvic lymph nodes (30), therefore, pelvic LAD is not needed if there is no involvement of inguinal nodes or there is only one intranodal metastasis (14,19) (LE: 3).

In contrast, pelvic LAD is recommended if the node of Cloquet or two or more inguinal nodes

are involved. The rate of positive pelvic nodes was found to be 23% in cases with more than two positive inguinal nodes, and 56% for those with more than three positive inguinal nodes, or if there was extracapsular involvement in at least one inguinal node (14,19) (LE: 2b). Pelvic LAD can be performed as a secondary procedure.

If bilateral dissection is indicated, it can be performed through a midline suprapubic extraperitoneal incision. It is also important to avoid delay for LAD (31). Laparoscopy is not suitable for radical surgery.

8.2.4 **Adjuvant chemotherapy**

Adjuvant chemotherapy after resection of nodal metastases has been reported in a few small heterogeneous series. Nevertheless, at the National Cancer Institute in Milan, Italy, a long-term disease-free survival (DFS) rate of 84% was obtained in 25 consecutive node-positive patients treated with 12 adjuvant weekly courses of VBM during the period 1979-1990 (32,33). This compares with a DFS rate of only 39% for 38 consecutive patients who underwent radical LAD, with or without complementary radiotherapy, in the period 1960-1978 (32).

Since 1991, category pN2-3 patients have received three courses of adjuvant cisplatin and 5-FU, with lower toxicity and even better results compared to VBM (33) (LE: 2b). Category pN1 patients do not need adjuvant chemotherapy (33) (LE: 2b).

8.2.5 **Management of patients with fixed or relapsed inguinal nodes**

Upfront surgery is not recommended (GR: B) because cure is unlikely, survival is short, and the surgery is usually quite destructive. Upfront chemotherapy followed by surgery is promising, and these procedures should be performed by experienced medical oncologists and surgeons (14,32,33).

Multiple regimens have been used in a small number of patients. Cisplatin, methotrexate, and bleomycin (BMP) at Memorial Sloan-Kettering Cancer Center in New York have shown promising results, but a confirmatory study by the Southwest Oncology Group has reported unacceptable toxicity and only modest results (34).

Leijte et al. have reported on 20 patients with five different neoadjuvant chemotherapy regimens in the 1972-2005 period (36). Responders underwent post-chemotherapy surgery and achieved a 37% long-term survival rate. At the MD Anderson Cancer Center, combination therapy with paclitaxel, carboplatin or paclitaxel, cisplatin, and ifosfamide has been used in seven patients, followed by surgery (37). Four patients were long-term survivors (48-84 months) but none of the other three patients treated with BMP achieved significant remission.

A preliminary study on taxol combined with cisplatin and 5-FU has shown significant responses in five of six patients with fixed or relapsed inguinal nodes, but only the three who underwent post-chemotherapy surgery achieved durable complete remission (38).

Conclusions	LE
Adjuvant chemotherapy is recommended in patients with pN2-3 tumours (33).	C
Neoadjuvant chemotherapy followed by radical surgery is advisable in patients with non-resectable or recurrent lymph node metastases (36-38).	C

8.2.6 **The role of radiotherapy**

Prophylactic radiotherapy in patients with N0 tumours is not recommended (39) (GR: C) because of:

- failure to prevent the development of metastatic lymph nodes;
- complications of radiotherapy;
- more difficult follow-up due to fibrotic changes.

Adjuvant radiotherapy may improve locoregional control in patients with extensive metastases and/or extranodal spread, but control is achieved at the cost of severe side effects including severe oedema and pain (GR: C).

8.2.7 **Guidelines for treatment strategies for nodal metastases**

Regional lymph nodes	Management of regional lymph nodes is fundamental in the treatment of penile cancer	LE	GR
No palpable inguinal nodes	Tis, Ta G1, T1G1: surveillance.	2a	B
	> T1G2: DSNB. (NB: Inguinal LAD if histology is positive).	2a	B
	If DSNB not available: risk factors / nomogram decision-making.	3	C

Palpable inguinal nodes	US-guided FNAB (DSNB is unsuitable for palpable nodes).	2a	B
	Negative biopsy: surveillance (repeat biopsy).		
	Positive biopsy: inguinal LAD on positive side.		
	(NB: Modified LAD must include the central zone and both superior Daseler's zones).		
Pelvic nodes	Pelvic LAD if there is: extranodal metastasis; Cloquet node involved; > 2 inguinal node metastases.	2a	B
	Unilateral pelvic LAD if unilateral lymph node metastases with prolonged inguinal incision.	2b	B
	Bilateral pelvic LAD if bilateral inguinal metastases.	2a	B
Adjuvant chemotherapy	In patients with > 1 intranodal metastasis (pN2 pN3) after radical LAD, survival is improved by adjuvant chemotherapy (3 courses of cisplatin, fluorouracil [PF] chemotherapy).	2b	B
Patients with fixed or relapsed inguinal nodes	Neo-adjuvant chemotherapy is strongly recommended in patients with unresectable or recurrent lymph node metastases.	2a	B
	Taxanes seems to improve the efficacy of standard PF chemotherapy (or carboplatin).		
Radiotherapy	Curative radiotherapy may be used for primary tumours of the glans penis and sulcus < 4 cm or for palliation.	2a	B
	Prophylactic radiotherapy in clinical N0 patients is not indicated.	2a	B

DSNB = dynamic sentinel node biopsy; FNAB = fine-needle aspiration biopsy; LAD = lymphadenectomy.

8.3 References

- Minhas S, Kayes O, Hegarty P. What surgical resection margins are required to achieve oncologic control in man with primary penile cancer? BJU Int 2005 Nov;96(7):1040-3.
<http://www.ncbi.nlm.nih.gov/pubmed/16225525>
- Hadway P, Corbishley CM, Watkin NA. Total glans resurfacing for premalignant lesions of the penis: initial outcome data. BJU Int 2006 Sep;98(3):532-6.
<http://www.ncbi.nlm.nih.gov/pubmed/16925748>
- Bandieramonte G, Colecchia M, Mariani L, et al. Penoscopically controlled CO2 laser excision for conservative treatment of in situ and T1 penile carcinoma: report on 224 patients. Eur Urol 2008 Oct;54(4):875-82.
<http://www.ncbi.nlm.nih.gov/pubmed/18243513>
- Windahl T, Andersson SO. Combined laser treatment for penile carcinoma: results after long-term follow up. J Urol 2003 Jun;169(6):2118-21.
<http://www.ncbi.nlm.nih.gov/pubmed/12771731>
- Schlenker B, Tilki D, Seitz M, et al. Organ-preserving neodymium-yttrium-aluminium-garnet laser therapy for penile carcinoma: a long-term follow-up. BJU Int. 2010 Sep;106(6):786-90.
<http://www.ncbi.nlm.nih.gov/pubmed/20089106>
- Shindel AW, Mann MW, Lev RY, et al. Mohs micrographic surgery for penile cancer: management and long-term followup. J Urol 2007 Nov;178(5):1980-5.
<http://www.ncbi.nlm.nih.gov/pubmed/17869306>
- Paoly J, Ternesten Bratel A, Löwhagen GB, et al. Penile intraepithelial neoplasia: results of photodynamic therapy. Acta Derm Venereol 2006;86(5):418-21.
<http://www.ncbi.nlm.nih.gov/pubmed/16955186>
- Smith Y, Hadway P, Biedrzycki O, et al. Reconstructive surgery for invasive squamous cell carcinoma of the glans penis. Eur Urol 2007 Oct;52(4):1179-85.
<http://www.ncbi.nlm.nih.gov/pubmed/17349734>
- Morelli G, Pagni R, Mariani C, et al. Glansectomy with split-thickness skin graft for the treatment of penile cancer. Int J Impot Res 2009 Sep-Oct;21(5):311-4.
<http://www.ncbi.nlm.nih.gov/pubmed/19458620>
- Palminteri E, Berdondini E, Lazzari M, et al. Resurfacing and reconstruction of the glans penis. Eur Urol 2007 Sep;52(3):893-8.
<http://www.ncbi.nlm.nih.gov/pubmed/17275169>
- Gotsadze D, Matveev B, Zak B, et al. Is conservative organsparing treatment of penile carcinoma justified? Eur Urol 2000 Sep; 38(3):306-12.
<http://www.ncbi.nlm.nih.gov/pubmed/10940705>

12. Garaffa G, Raheem AA, Christopher NA, et al. Total phallic reconstruction after penile amputation for carcinoma. *BJU Int* 2009 Sep;104(6):852-6.
<http://www.ncbi.nlm.nih.gov/pubmed/19239449>
13. Salgado CJ, Licata L, Fuller DA, et al. Glans penis coronoplasty with palmaris longus tendon following total penile reconstruction. *Ann Plast Surg* 2009 Jun;62(6):690-2.
<http://www.ncbi.nlm.nih.gov/pubmed/19461287>
14. Ornellas AA, Kinchin EW, No´ brega BL, et al. Surgical treatment of invasive squamous cell carcinoma of the penis: Brazilian National Cancer Institute long-term experience. *J Surg Oncol* 2008 May;97(6):487-95.
<http://www.ncbi.nlm.nih.gov/pubmed/18425779>
15. deCrevoisier R, Slimane K, Sanfilippo N, et al. Long- term results of brachytherapy for carcinoma of the glans (N- or NX). *Int J Radiol Biol Phys* 2009 Jul 15;74(4):1150-6.
<http://www.ncbi.nlm.nih.gov/pubmed/19395183>
16. Azrif M, Logue GP, Swindell R, et al. External-beam radiotherapy in T1-2 N0 penile carcinoma. *Clin Oncol (R Coll Radiol)* 2006 May;18(4):320-5.
<http://www.ncbi.nlm.nih.gov/pubmed/16703750>
17. Crook J, Esche B, Pond G. Penile brachytherapy: results for 60 patients. *Brachytherapy* 2007;6:82-92.
18. Zouhair A, Coucke PA, Jeanneret W, et al. Radiation therapy alone or combined surgery and radiation therapy in squamous-cell carcinoma of the penis? *Eur J Cancer* 2001 Jan;37(2):198-203.
<http://www.ncbi.nlm.nih.gov/pubmed/11166146>
19. Ornellas AA, Seixas AL, Marota A, et al. Surgical treatment of invasive squamous cell carcinoma of the penis: retrospective analysis of 350 cases. *J Urol* 1994 May;151(5):1244-9.
<http://www.ncbi.nlm.nih.gov/pubmed/7512656>
20. Protzel C, Alcatraz A, Horenblas S, et al. Lymphadenectomy in the surgical management of penile cancer. *Eur Urol* 2009 May;55(5):1075-88.
<http://www.ncbi.nlm.nih.gov/pubmed/19264390>
21. Cattan MW, Ficarra V, Artibani W, et al. GUONE Penile Cancer Project Members. Nomogram predictive of cancer specific survival in patients undergoing partial or total amputation for squamous cell carcinoma of the penis. *J Urol* 2006 Jun;175(6):2103-8.
<http://www.ncbi.nlm.nih.gov/pubmed/16697813>
22. Solsona E, Algaba F, Horenblas S, et al. EAU guidelines on penile cancer. *Eur Urol* 2004 Jul;46(1):1-8.
<http://www.ncbi.nlm.nih.gov/pubmed/15183542>
23. Hughes BE, Leijte JAP, Kroon BK, et al. Lymph node metastasis in intermediate-risk penile squamous cell cancer: a two-centre experience. *Eur Urol* 2010 Apr;57(4):688-92.
<http://www.ncbi.nlm.nih.gov/pubmed/19647926>
24. Leijte JAP, Kroon BK, Valde´ s Olmos RA, et al. Reliability and safety of current dynamic sentinel node biopsy for penile carcinoma. *Eur Urol* 2007 Jul;52(1):170-7.
<http://www.ncbi.nlm.nih.gov/pubmed/17316967>
25. Leijte JA, Hughes B, Graafland NM, et al. Two-center evaluation of dynamic sentinel node biopsy for squamous cell carcinoma of the penis. *J Clin Oncol* 2009 Jul;27(20):3325-9.
<http://www.ncbi.nlm.nih.gov/pubmed/19414668>
26. Lucky MA, Rogers B, Parr NJ. Referrals into a dedicated British penile cancer centre and sources of possible delay. *Sex Transm Infect* 2009 Dec;85(7):527-30.
<http://www.ncbi.nlm.nih.gov/pubmed/19584061>
27. Saisorn I, Lawrentschut N, Leewansangtong S, et al. Fine-needle aspiration cytology predicts inguinal lymph node metastases without antibiotic pretreatment in penile carcinoma. *BJU Int* 2006 Jun;97(6):1125-8.
<http://www.ncbi.nlm.nih.gov/pubmed/16686716>
28. Horenblas S. Lymphadenectomy for squamous cell carcinoma of the penis. Part 1: diagnosis of lymph node metastasis. *BJU Int* 2001 Sep;88:467-72.
<http://www.ncbi.nlm.nih.gov/pubmed/11589659>
29. Leijte JAP, Valde´ s Olmos RA, Nieweg OE, et al. Anatomical mapping of lymphatic drainage in penile carcinoma with SPECT-CT: implications for the extent of inguinal lymph node dissection. *Eur Urol* 2008 Oct;54(4):885-90.
<http://www.ncbi.nlm.nih.gov/pubmed/18502024>
30. Daseler EH, Anson BJ, Reimann AF. Radical excision of inguinal and iliac lymph glands: a study based upon 450 anatomical dissections and upon supportive clinical observations. *Surg Gynecol Obstet* 1948 Dec;87(6):679-94. [no abstract available]
<http://www.ncbi.nlm.nih.gov/pubmed/18120502>

31. Horenblas S. Lymphadenectomy for squamous cell carcinoma of the penis. Part 2: the role and technique of lymph node dissection. *BJU Int* 2001 Sep;88(5):473-83.
<http://www.ncbi.nlm.nih.gov/pubmed/11589660>
32. Pizzocaro G, Piva L. Adjuvant and neoadjuvant vincristine, bleomycin, and methotrexate for inguinal metastases from squamous cell carcinoma of the penis. *Acta Oncol* 1988;27(6b):823-4.
<http://www.ncbi.nlm.nih.gov/pubmed/2466471>
33. Pizzocaro G, Piva L, Bandieramonte G, et al. Up-to-date management of carcinoma of the penis. *Eur Urol* 1997;32(1):5-15.
<http://www.ncbi.nlm.nih.gov/pubmed/9266225>
34. Dexeus F, Logothetis C, Sella A, et al. Combination chemotherapy with methotrexate, bleomycin and cisplatin for advanced squamous cell carcinoma of the male genital tract. *J Urol* 1991 Nov;146(5):1284-7.
<http://www.ncbi.nlm.nih.gov/pubmed/1719241>
35. Haas G, Blumenstein B, Gagliano R, et al. Cisplatin, methotrexate and bleomycin for the treatment of carcinoma of the penis: a Southwest Oncology Group study. *J Urol* 1999 Jun;161(6):1823-5.
<http://www.ncbi.nlm.nih.gov/pubmed/10332445>
36. Leijte JAP, Kerst JM, Bais E, et al. Neoadjuvant chemotherapy in advanced penile carcinoma. *Eur Urol* 2007 Aug;52(2):488-94.
<http://www.ncbi.nlm.nih.gov/pubmed/17316964>
37. Barnejo C, Busby JK, Spiess PE, et al. Neoadjuvant chemotherapy followed by aggressive surgical consolidation for metastatic penile squamous cell carcinoma. *J Urol* 2007 Apr;177(4):1335-8.
<http://www.ncbi.nlm.nih.gov/pubmed/17382727>
38. Pizzocaro G, Nicolai N, Milani A. Taxanes in combination with cisplatin and fluorouracil for advanced penile cancer: preliminary results. *Eur Urol* 2009 Mar;55(3):546-51.
<http://www.ncbi.nlm.nih.gov/pubmed/18649992>
39. Kulkarni JN, Kamat MR. Prophylactic bilateral groin node dissection versus prophylactic radiotherapy and surveillance in patients with N0 and N(1-2A) carcinoma of the penis. *Eur Urol* 1994;26(2):123-8.
<http://www.ncbi.nlm.nih.gov/pubmed/7957466>

9. FOLLOW-UP

Follow-up in penile carcinoma is important for several reasons:

- It enables early detection of recurrence, which is important because most local and/or loco-regional recurrences are potentially curable.
- It is the only way to assess treatment and anticipate early and late complications.
- It is important for patient (and physician) education.

A rational follow-up scheme requires an understanding of the patterns of recurrence. Preferably, follow-up should be introduced within the framework of a controlled study. Based on a retrospective study, a follow-up schedule for penile cancer has been published (1).

9.1 How to follow-up

The aim of follow-up is to detect local and/or regional recurrences because they can be cured. In contrast, metastases at distant sites are always fatal (2). Risk stratification for recurrence is also helpful. Traditional follow-up methods are inspection and physical evaluation. Modern US is a useful adjunct, with promising results from new imaging modalities, such as PET/CT (3).

9.2 When to follow-up

The follow-up interval and strategies for patients with penile cancer are directed by the initial treatment of the primary lesion and regional lymph nodes. In the above-mentioned multicentre study (1), during the first 2 years of follow-up, the following occurred:

- 74.3% of all recurrences;
- 66.4% of local recurrences;
- 86.1% of regional recurrences;
- 100% of distant recurrences.

Of all recurrences, 92.2% occurred within the first 5 years (1). All recurrences after 5 years were

local recurrences or new primary lesions. Thus, an intensive programme of follow-up during the first 2 years is rational, with less intensive follow-up needed thereafter. In well-educated and motivated patients, follow-up can stop after 5 years, although they must continue to carry out regular self-examination.

9.3 Primary tumour

Local recurrence has been reported in up to 30% of patients treated with penis-preserving surgery, during the first 2 years following treatment. Local recurrence is more likely with all types of local therapy, that is, local resection, laser therapy, brachytherapy, Mohs' procedure, and associated therapies (1,4). However, in contrast to regional recurrence, local recurrence does not have an impact on survival (1,4).

Local recurrences are easily detected by the patient, his partner or doctor. Patient education is an important part of follow-up and the patient should be urged to visit a specialist if any changes are seen. Despite the fact that late local recurrences are well documented, it is reasonable to stop follow-up after 5 years, provided the patient will report local changes immediately (5). This is possible because life-threatening regional and distant metastases no longer occur, while recurrences that are local only are not life-threatening. The emphasis should be placed on patient self-examination. In patients who are unlikely to self-examine, long-term follow-up may be necessary.

Following penis-preserving treatment, a follow-up visit every 3 months is advised in the first 2 years. We then advise a follow-up visit every 6 months, provided that the patient and his partner have been well instructed to examine the penis regularly and to return if any abnormality is observed. It is important to stress that the patient must continue to carry out regular self-examination even after 5 years' follow-up. After amputation, a less frequent time interval of every 6 months is advised. The risk of local recurrence is no more than 5% (1,4).

9.4 Regional recurrences

Stringent follow-up is advised for the 2 years following surgery. This is because most regional recurrences occur within that time, whether a 'wait-and-see' policy has been followed or the patient has undergone SNB or inguinal LAD.

Previous follow-up recommendations have relied heavily on physical examination of the inguinal regions. However, experience with 'wait and see' and DSNB have shown that, despite intensive follow-up, regional recurrences have shown up unexpectedly (6). US and immediate FNAB have been encouraging in finding occult metastases (6,7), and it seems reasonable to add US to physical examination.

Patients managed with a 'wait-and-see' policy have a higher risk of recurrence (9%) than patients staged surgically (2.3%), irrespective whether staging has been performed by LAD or DSNB. This finding only applies to patients without histopathological evidence of lymph node metastases.

Patients treated surgically because of lymph node metastases have an increased risk of recurrence (19%) (1). Based on these findings, a change in the follow-up scheme is proposed. For patients in a 'wait-and-see' programme and those treated with LAD for proven lymph node metastases, follow-up should be every 3 months and should include US investigation of the groin. This intensive follow-up programme should be observed for 2 years, which is the period when recurrence is most likely. Imaging using CT has been replaced by US scanning with immediate FNAB, and PET/CT is used in patients at risk of regional recurrence and distant metastases. Bone scan and other tests are only recommended in symptomatic patients.

9.5 Guidelines for follow-up in penile cancer

Table 7 provides a follow-up schedule for penile cancer with grades of recommendation.

Table 7: Follow-up schedule for penile cancer

	Interval of follow-up		Examinations and investigations	Maximum duration of follow-up	GR
	Years 1 and 2	Years 3, 4 and 5			
<i>Recommendations for follow-up of the primary tumour</i>					
Penile preserving treatment	3 months	6 months	Regular physician or self-examination	5 years	C
Amputation	6 months	1 year	Regular physician or self-examination	5 years	C
<i>Recommendations for follow-up of the inguinal lymph nodes</i>					
'Wait-and-see'	3 months	6 months	Regular physician or self-examination	5 years	C

pN0	6 months	1 year	Regular physician or self-examination US with FNAB	5 years	C
pN+	3 months	6 months	Regular physician or self-examination US with FNAB	5 years	C

FNAB = *fine-needle aspiration biopsy*.

9.6 References

- Leijte JAP, Kirrander P, Antonini N, et al. Recurrence patterns of squamous cell carcinoma of the penis: recommendations for follow-up based on a two-centre analysis of 700 patients. *Eur Urol* 2008 Jul;54(1):161-8.
<http://www.ncbi.nlm.nih.gov/pubmed/18440124>
- Horenblas S, van Tinteren H, Delamarre JFM, et al. Squamous cell carcinoma of the penis. III. Treatment of regional lymph nodes. *J Urol* 1993 Mar;149(3):492-7.
<http://www.ncbi.nlm.nih.gov/pubmed/8437253>
- Lont AP, Gallee MP, Meinhardt W, et al. Penis conserving treatment for T1 and T2 penile carcinoma: clinical implications of a local recurrence. *J Urol* 2006 Aug;176(2):575-80;discussion 580.
<http://www.ncbi.nlm.nih.gov/pubmed/16813892>
- Horenblas S, Newling DW. Local recurrent tumour after penis-conserving therapy. A plea for long-term follow-up. *Br J Urol* 1993 Dec;72(6):976. [no abstract available]
<http://www.ncbi.nlm.nih.gov/pubmed/8306171>
- Kroon BK, Horenblas S, Lont AP, et al. Patients with penile carcinoma benefit from immediate resection of clinically occult lymph node metastases. *J Urol* 2005 Mar;173(3):816-9.
<http://www.ncbi.nlm.nih.gov/pubmed/15711276>
- Kroon BK, Horenblas S, Deurloo EE, et al. Ultrasonography-guided fine-needle aspiration cytology before sentinel node biopsy in patients with penile carcinoma. *BJU Int* 2005 Mar;95(4):517-21.
<http://www.ncbi.nlm.nih.gov/pubmed/15705071>
- Krishna RP, Sistla SC, Smile R, et al. Sonography: An underutilized diagnostic tool in the assessment of metastatic groin nodes. *J Clin Ultrasound* 2008 May;36(4):212-7.
<http://www.ncbi.nlm.nih.gov/pubmed/17960822>

10. QUALITY OF LIFE

10.1 Sexuality and fertility after cancer

As more people achieve long-term survival after cancer, sexual dysfunction and infertility are increasingly recognised as negative consequences that affect the quality of life (1).

10.1.1 *Sexual activity and quality of life after penile cancer laser treatment*

A retrospective, face-to-face, structured interview study was carried out on Swedish patients treated with laser for localised penile carcinoma during 1986 to 2000 (2). Sixty-seven patients were treated, with 58 of them (mean age 63 years) still alive in 2006. Forty-six (79%) agreed to participate in the interview. Nearly all patients could recall their first symptom, with 37% reporting that they delayed seeking treatment for > 6 months. Patients had a greater lifetime number of sexual partners and a greater lifetime prevalence of sexually transmitted infections than the comparable general Swedish population. Following laser treatment, there was a marked decrease in some sexual practices, such as manual stimulation or caressing and fellatio. Patient satisfaction with life overall was similar to that of the general population.

In conclusion, some patients delayed seeking treatment for a considerable period despite awareness of the first local symptoms. Men with laser-treated localised penile carcinoma resumed their sexual activities to a large extent. Except for satisfaction with somatic health, a similar (or higher) proportion of patients were satisfied with life overall and with other domains of life including their sex life.

10.1.2 *Sexual function after partial penectomy for penile cancer*

To compare sexual function and satisfaction before and after partial penectomy, 18 Brazilian patients were given a personal interview and answered the International Index of Erectile Function questionnaire to determine erectile function, orgasmic function, sexual desire, intercourse satisfaction, and overall satisfaction with sexual activity (3). The median patient age was 52 years. The medium penile length after partial penectomy was

4 cm in the flaccid state, with 55.6% of patients reporting erectile function that allowed sexual intercourse.

The main reason given for not resuming sexual intercourse in 50% of sexually abstinent patients was feeling shame because of a small penis and the absence of the glans penis. Surgical complications also compromised resumption of sexual activity after amputation in 33.3% of these patients. However, 66.7% sustained the same frequency and level of sexual desire prior to surgery, and 72.2% continued to have ejaculation and orgasm every time they had sexual stimulation or intercourse. Nevertheless, only 33.3% maintained their preoperative frequency of sexual intercourse and were satisfied with their sexual relationships with their partners and their overall sex life. In conclusion, the preoperative and postoperative scores were statistically worse for all domains of sexual function after partial penectomy.

10.2 Sexual mutilation, relapse, and death

Today, nearly 80% of penile cancer patients can be cured. Experience in management of this rare tumour is helpful (4). Referral to centres with experience is recommended. Psychological support is very important for these patients. Penis-sparing surgery obviously allows a better quality of life than penile amputation and must be considered whenever feasible.

10.3 References

1. Schover LR. Sexuality and fertility after cancer. Hematology Am Soc Hematol Educ Program 2005;523-7.
<http://www.ncbi.nlm.nih.gov/pubmed/16304430>
2. Skeppner E, Windahl T, Andersson S, et al. Treatment-seeking, aspects of sexual activity and life satisfaction in men with laser-treated penile carcinoma. Eur Urol 2008 Sep;54(3):631-9.
<http://www.ncbi.nlm.nih.gov/pubmed/18788122>
3. Romero FR, Romero KR, Mattos MA, et al. Sexual function after partial penectomy for penile cancer. Urology 2005 Dec;66(6):1292-5.
<http://www.ncbi.nlm.nih.gov/pubmed/16360459>
4. Leijte JA, Gallee M, Antonini N, et al. Evaluation of current TNM classification of penile carcinoma. J Urol 2008 Sep;180(3):933-8.
<http://www.ncbi.nlm.nih.gov/pubmed/18635216>

11. ABBREVIATIONS USED IN THE TEXT

This list is not comprehensive for the most common abbreviations.

5-FU	5-fluorouracil
BMP	cisplatin, methotrexate and bleomycin
CT	computed tomography
DFS	disease-free survival
DSNB	dynamic sentinel node biopsy
EAU	European Association of Urology
FDA	[US] Food and Drug Administration
FDG	fluorodeoxyglucose
FNAB	fine-needle aspiration biopsy
FNAC	fine-needle aspiration cytology
GR	grade of recommendation
HPV	human papillomavirus
LAD	lymphadenectomy
LE	level of evidence
MRI	magnetic resonance imaging
Nd:YAG	neodymium:yttrium-aluminum-garnet
PET	positron emission tomography
PF	cisplatin and fluorouracil
SCC	squamous cell carcinoma
SNB	sentinel node biopsy
TC99m	technetium 99m
TNM	tumour, node, metastasis
VBM	vinblastine, bleomycin, methotrexate

Conflict of interest

All members of the Penile Cancer Guidelines working panel have provided disclosure statements on all relationships that they have that might be perceived to be a potential source of a conflict of interest. This information is publically accessible through the European Association of Urology website. This guidelines document was developed with the financial support of the European Association of Urology. No external sources of funding and support have been involved. The EAU is a non-profit organisation, and funding is limited to administrative assistance and travel and meeting expenses. No honoraria or other reimbursements have been provided.

