

Guidelines on Paediatric Urology

S. Tekgül, H. Riedmiller, H.S. Dogan, P. Hoebeke, R. Kocvara,
R. Nijman, Chr. Radmayr, R. Stein



European Society for Paediatric Urology



European
Association
of Urology

© European Association of Urology 2013

TABLE OF CONTENTS

PAGE

1.	METHODOLOGY	7
1.1	Introduction	7
1.2	Data identification and evidence sources	7
1.3	Level of evidence and grade of recommendation	7
1.4	Publication history	8
1.4.1	Summary of updated and new information	8
1.5	Potential conflict of interest statement	8
1.6	References	9
2.	PHIMOSIS	9
2.1	Background	9
2.2	Diagnosis	9
2.3	Treatment	9
2.4	Conclusions and recommendations on phimosis	10
2.5	References	10
3.	CRYPTORCHIDISM	11
3.1	Background	11
3.2	Diagnosis	11
3.3	Treatment	12
3.3.1	Medical therapy	12
3.3.2	Surgery	12
3.4	Prognosis	12
3.5	Recommendations for cryptorchidism	13
3.6	References	13
4.	HYDROCELE	14
4.1	Background	14
4.2	Diagnosis	15
4.3	Treatment	15
4.4	Recommendations for the management of hydrocele	15
4.5	References	15
5.	ACUTE SCROTUM IN CHILDREN	16
5.1	Background	16
5.2	Diagnosis	16
5.3	Treatment	17
5.3.1	Epididymitis	17
5.3.2	Testicular torsion	17
5.3.3	Surgical treatment	17
5.4	Prognosis	17
5.4.1	Fertility	17
5.4.2	Subfertility	18
5.4.3	Androgen levels	18
5.4.4	Testicular cancer	18
5.4.5	Nitric oxide	18
5.5	Perinatal torsion	18
5.6	Recommendations acute scrotum in children	18
5.7	References	19
6.	Hypospadias	22
6.1	Background	22
6.1.1	Risk factors	22
6.2	Diagnosis	22
6.3	Treatment	22
6.3.1	Age at surgery	23
6.3.2	Penile curvature	23
6.3.3	Preservation of the well-vascularized urethral plate	23
6.3.4	Re-do hypospadias repairs	24
6.3.5	Urethral reconstruction	24

6.3.6	Urine drainage and wound dressing	24
6.3.7	Outcome	24
6.4	Conclusions and recommendations	25
6.5	References	25
7.	CONGENITAL PENILE CURVATURE	28
7.1	Background	28
7.2	Diagnosis	28
7.3	Treatment	28
7.4	References	28
8.	VARICOCELE IN CHILDREN AND ADOLESCENTS	28
8.1	Background	28
8.2	Diagnosis	29
8.3	Therapy	29
8.4	Conclusions and recommendations	30
8.5	References	30
9.	URINARY TRACT INFECTIONS IN CHILDREN	31
9.1	Introduction	31
9.2	Classification	32
9.2.1	Classification according to site	32
9.2.2	Classification according to episode (10)	32
9.2.3	Classification according to severity	32
9.2.4	Classification according to symptoms	32
9.2.5	Classification according to complicating factors (12)	33
9.3	Diagnosis	33
9.3.1	Medical history	33
9.3.2	Clinical signs and symptoms	33
9.3.3	Physical examination	33
9.4	Urine sampling, analysis and culture	33
9.4.1	Urine sampling	33
9.4.2	Urinalysis	34
9.4.3	Urine culture	35
9.5	Therapy	35
9.5.1	Administration route	35
9.5.2	Duration of therapy	35
9.5.3	Antimicrobial agents	36
9.5.4	Chemoprophylaxis	38
9.6	Monitoring of UTI	38
9.7	Imaging	38
9.7.1	Ultrasound	38
9.7.2	Radionuclide scanning	38
9.7.3	Voiding cystourethrography	39
9.8	Bladder and bowel dysfunction	39
9.9	Conclusions and recommendations for UTI in children	39
9.10	References	40
10.	DAYTIME LOWER URINARY TRACT CONDITIONS	44
10.1	Background	44
10.2	Definition	44
10.2.1	Filling-phase dysfunctions	45
10.2.2	Voiding-phase (emptying) dysfunctions	45
10.3	Diagnosis	45
10.4	Treatment	45
10.4.1	Standard therapy	45
10.4.2	Specific interventions	46
10.5	References	46
11.	MONOSYMPTOMATIC ENURESIS	47
11.1	Background	47
11.2	Definition	48

11.3	Diagnosis	48
11.4	Treatment	48
	11.4.1 Supportive treatment measures	48
	11.4.2 Alarm treatment	48
	11.4.3 Medication	49
11.5	References	50
12.	MANAGEMENT OF NEUROGENIC BLADDER IN CHILDREN	50
12.1	Background	50
12.2	Definition	51
12.3	Classification	51
12.4	Urodynamic studies	51
	12.4.1 Method of urodynamic study	52
	12.4.2 Uroflowmetry	52
	12.4.3 Cystometry	52
12.5	Management	53
	12.5.1 Investigations	53
	12.5.2 Early management with intermittent catheterisation	53
	12.5.3 Medical therapy	53
	12.5.3.1 Botulinum toxin injections	53
	12.5.4 Management of bowel incontinence	54
	12.5.5 Urinary tract infection	54
	12.5.6 Sexuality	54
	12.5.7 Bladder augmentation	54
	12.5.8 Bladder outlet procedures	54
	12.5.9 Continent stoma	55
	12.5.10 Total bladder replacement	55
	12.5.11 Lifelong follow-up of neurogenic bladder patients	55
12.6	References	55
13.	DILATATION OF THE UPPER URINARY TRACT (URETEROPELVIC JUNCTION AND URETEROVESICAL JUNCTION OBSTRUCTION)	61
13.1	Background	61
13.2	Diagnosis	61
	13.2.1 Antenatal ultrasound	61
	13.2.2 Postnatal ultrasound	61
	13.2.3 Voiding cystourethrogram (VCUG)	61
	13.2.4 Diuretic renography	61
13.3	Treatment	62
	13.3.1 Prenatal management	62
	13.3.2 UPJ obstruction	62
	13.3.3 Megaureter	62
	13.3.3.1 Conservative management	62
	13.3.3.2 Surgical management	63
13.4	Conclusion	63
13.5	Conclusions and recommendations for UPJ-, UVJ-obstruction	63
13.6	References	63
14.	VESICoureTERIC REFLUX IN CHILDREN	64
14.1	Methodology	64
14.2	Background	64
14.3	Diagnostic work-up	65
	14.3.1 Infants presenting because of prenatally diagnosed hydronephrosis	66
	14.3.2 Siblings and offspring of reflux patients	66
	14.3.3 Children with febrile urinary tract infections	67
	14.3.4 Children with lower urinary tract symptoms and vesicoureteric reflux	67
14.4	Treatment	67
	14.4.1 Conservative therapy	67
	14.4.1.1 Follow-up	68
	14.4.1.2 Continuous antibiotic prophylaxis (CAP)	68
	14.4.2 Surgical treatment	68
	14.4.2.1 Subureteric injection of bulking materials	68

	14.4.2.2 Open surgical techniques	69
	14.4.2.3 Laparoscopy	69
14.5	Recommendations for the management of vesicoureteric reflux in childhood	69
14.6	References	71
15.	URINARY STONE DISEASE	75
15.1	Background	75
15.2	Stone formation mechanisms, diagnosis of causative factors and medical treatment for specific stone types	75
	15.2.1 Calcium stones	76
	15.2.2 Uric acid stones	77
	15.2.3 Cystine stones	77
	15.2.4 Infection stones (struvite stones)	77
15.3	Clinical presentation	78
15.4	Diagnosis	78
	15.4.1 Imaging	78
	15.4.2 Metabolic evaluation	78
15.5	Management	80
	15.5.1 Extracorporeal shock wave lithotripsy (SWL)	80
	15.5.2 Percutaneous nephrolithotomy	80
	15.5.3 Ureterorenoscopy	81
	15.5.4 Open stone surgery	81
15.6	Conclusions and recommendations	82
15.7	References	83
16.	OBSTRUCTIVE PATHOLOGY OF RENAL DUPLICATION: URETEROCELE AND ECTOPIC URETER	87
16.1	Background	87
	16.1.1 Ureterocele	88
	16.1.2 Ectopic ureter	88
16.2	Definition and classification	88
	16.2.1 Ureterocele	88
	16.2.1.1 Ectopic (extravesical) ureterocele	88
	16.2.1.2 Orthotopic (intravesical) ureterocele	88
	16.2.2 Ectopic ureter	88
16.3	Diagnosis	89
	16.3.1 Ureterocele	89
	16.3.2 Ectopic ureter	89
16.4	Treatment	89
	16.4.1 Ureterocele	89
	16.4.1.1 Early treatment	89
	16.4.1.2 Re-evaluation	89
	16.4.2 Ectopic ureter	90
16.5	Conclusions and recommendations for obstructive pathology of renal duplication: ureterocele and ectopic ureter	91
16.6	References	91
17.	DISORDERS OF SEX DEVELOPMENT	94
17.1	Background	94
17.2	Micropenis	94
	17.2.1 Background	94
	17.2.2 Diagnosis	95
	17.2.3 Treatment	95
17.3	The neonatal emergency	95
	17.3.1 Family history and clinical examination	95
	17.3.2 Choice of laboratory investigations	96
17.4	Gender assignment	96
17.5	Role of the paediatric urologist	96
	17.5.1 Diagnosis	97
	17.5.1.1 Clinical examination	97
	17.5.1.2 Investigations	97
17.6	Management	97
	17.6.1 Feminising surgery	98

17.6.2	Masculinising surgery	98
17.7	Guidelines for the treatment of disorders of sex development	98
17.8	References	99
18.	POSTERIOR URETHRAL VALVES	100
18.1	Background	100
18.2	Classification	100
18.2.1	Urethral valve	100
18.3	Diagnosis	100
18.4	Treatment	101
18.4.1	Antenatal treatment	101
18.4.2	Postnatal treatment	101
18.5	Summary	104
18.6	Conclusions and recommendations posterior urethral valves	104
18.7	References	104
19.	PAEDIATRIC UROLOGICAL TRAUMA	106
19.1	Background	106
19.2	Paediatric renal trauma	106
19.2.1	Diagnosis	107
19.2.1.1	Haematuria	107
19.2.1.2	Blood pressure	107
19.2.1.2	Choice of imaging method	107
19.2.2	Treatment	108
19.2.3	Guidelines for the diagnosis and treatment of paediatric renal trauma	108
19.3	Paediatric ureteral trauma	108
19.3.1	Diagnosis	108
19.3.2	Treatment	108
19.3.3	Guidelines for the diagnosis and treatment of paediatric ureteral trauma	109
19.4	Paediatric bladder injuries	109
19.4.1	Diagnosis	109
19.4.2	Treatment	109
19.4.2.1	Intraperitoneal injuries	109
19.4.2.2	Extraperitoneal injuries	109
19.4.3	Guidelines for the diagnosis and treatment of paediatric bladder injuries	110
19.5	Paediatric urethral injuries	110
19.5.1	Diagnosis	110
19.5.2	Treatment	110
19.5.3	Guidelines for the diagnosis and treatment of paediatric trauma	111
19.6	References	111
20.	POST-OPERATIVE FLUID MANAGEMENT	112
20.1	Background	112
20.2	Pre-operative fasting	112
20.3	Maintenance therapy and intra-operative fluid therapy	113
20.4	Post-operative fluid management	114
20.5	Post-operative fasting	114
20.6	Summary conclusions and recommendations	115
20.7	References	115
21.	POST-OPERATIVE PAIN MANAGEMENT IN CHILDREN: GENERAL INFORMATION	116
21.1	Introduction	116
21.2	Assessment of pain	117
21.3	Drugs and route of administration	117
21.4	Circumcision	117
21.5	Penile, inguinal and scrotal surgery	117
21.6	Bladder and kidney surgery	120
21.7	Conclusions and recommendations	120
21.8	References	120
22.	ABBREVIATIONS USED IN THE TEXT	126

1. METHODOLOGY

1.1 Introduction

A collaborative working group consisting of members representing the European Society for Paediatric Urology (ESPU) and the European Association of Urology (EAU) has prepared these guidelines to make a document available that may help to increase the quality of care for children with urological problems.

This compilation document addresses a number of common clinical pathologies in paediatric urological practice, but covering the entire field of paediatric urology in a single guideline document is unattainable, nor practical.

The majority of urological clinical problems in children are distinct and in many ways different to those in adults. This publication intends to outline a practical and preliminary approach to paediatric urological problems. Complex and rare conditions that require special care with experienced doctors should be referred to designated centres where paediatric urology practice has been fully established and a multidisciplinary approach is available.

For quite some time, paediatric urology has informally developed, expanded, matured and established its diverse body of knowledge and expertise and may now be ready to distinguish itself from its parent specialties.

Thus, paediatric urology has recently emerged in many European countries as a distinct subspecialty of both urology and paediatric surgery, and presents a unique challenge in the sense that it covers a large area with many different schools of thought and a huge diversity in management.

Knowledge gained by increasing experience, new technological advances and non-invasive diagnostic screening modalities has had a profound influence on treatment modalities in paediatric urology, a trend that is likely to continue in the years to come. We now have new techniques for the treatment of reflux, our techniques for the treatment of complex congenital anomalies have substantially improved, and totally new technologies for bladder replacement and laparoscopic procedures have been developed.

1.2 Data identification and evidence sources

The guidelines were compiled based on current literature following a systematic review using MEDLINE. Application of a structured analysis of the literature was not possible in many conditions due to a lack of well-designed studies.

Due to the limited availability of large randomised controlled trials (RCTs) - influenced also by the fact that a considerable number of treatment options relate to surgical interventions on a large spectrum of different congenital problems - this document will largely be a consensus document. Also, there is clearly a need for continuous re-evaluation of the information presented in the current document.

It must be emphasised that clinical guidelines present the best evidence available but following the recommendations will not necessarily result in the best outcome. Guidelines can never replace clinical expertise when making treatment decisions for individual patients, also taking individual circumstances and patient and parent preferences into account.

1.3 Level of evidence and grade of recommendation

The level of evidence (LE) and grade of recommendation (GR) provided in this guideline follow the listings in Tables 1 and 2. The aim of grading the recommendations is to provide transparency between the underlying evidence and the recommendation given.

Table 1: Level of evidence*

Level	Type of evidence
1a	Evidence obtained from meta-analysis of randomised trials.
1b	Evidence obtained from at least one randomised trial.
2a	Evidence obtained from one well-designed controlled study without randomisation.
2b	Evidence obtained from at least one other type of well-designed quasi-experimental study.
3	Evidence obtained from well-designed non-experimental studies, such as comparative studies, correlation studies and case reports.
4	Evidence obtained from expert committee reports or opinions or clinical experience of respected authorities.

*Modified from Sackett, et al. (1).

It should be noted that when recommendations are graded, there is not an automatic relationship between the level of evidence and the grade of recommendation. The availability of RCTs may not necessarily translate into a grade A recommendation if there are methodological limitations or disparities in the published results. Conversely, an absence of high-level evidence does not necessarily preclude a grade A recommendation if there is overwhelming clinical experience and consensus. In addition, there may be exceptional situations in which corroborating studies cannot be performed, perhaps for ethical or other reasons. In this case, unequivocal recommendations are considered helpful for the reader. Whenever this occurs, it has been clearly indicated in the text with an asterisk as 'upgraded based on panel consensus'. The quality of the underlying scientific evidence is a very important factor, but it has to be balanced against benefits and burdens, values and preferences and costs when a grade is assigned (2-4).

The EAU Guidelines Office does not perform cost assessments, nor can they address local/national preferences in a systematic fashion. However, whenever such data are available, the expert panels will include the information.

Table 2: Grade of recommendation*

Grade	Nature of recommendations
A	Based on clinical studies of good quality and consistency addressing the specific recommendations and including at least one randomised trial.
B	Based on well-conducted clinical studies, but without randomised clinical trials.
C	Made despite the absence of directly applicable clinical studies of good quality.

*Modified from Sackett, et al. (1).

1.4 Publication history

The Paediatric Urology Guidelines were first published in 2001 with subsequent partial updates achieved in 2005, 2006, 2008, 2009, 2010, 2011, 2012 and this 2013 publication includes a considerable number of updated chapters and sections detailed below.

Standard procedure for EAU publications includes an annual scoping search to guide updates. An ultra-short reference document is being published alongside this publication.

All documents are available, free access, through the EAU website Uroweb <http://www.uroweb.org/guidelines/online-guidelines/>.

1.4.1 Summary of updated and new information

New literature has been included and a limited revision applied for chapters:

Chapter 2: Phimosis

Chapter 4: Hydrocele

Chapter 5: Acute scrotum in children.

Chapter 8: Varicocele in children and adolescents

Chapter 10: Daytime lower urinary tract conditions

Chapter 11: Monosymptomatic enuresis

Chapter 12: Management of neurogenic bladder in children.

Chapter 13: Dilatation of the upper urinary tract (ureteropelvic junction and ureterovesical junction obstruction)

Chapter 14: Vesicoureteral reflux in children

Chapter 15: Urinary stone disease

Chapter 17: Disorders of sex development". Former chapter 9 -"micropenis" has been incorporated.

Chapter 20: Post-operative fluid management in children

Chapter 21: Post-operative pain management in children

A complete update was achieved for chapters:

Chapter 3: Cryptorchidism

Chapter 6: Hypospadias; the management algorithm has been updated.

New topic included in this 2012 print

Paediatric urological Trauma (Chapter 19)

1.5 Potential conflict of interest statement

The expert panel have submitted potential conflict of interest statements which can be viewed on the EAU website: <http://www.uroweb.org/guidelines/online-guidelines/>.

1.6 References

1. Oxford Centre for Evidence-Based Medicine Levels of Evidence (May 2009). Produced by Bob Phillips, Chris Ball, Dave Sackett, Doug Badenoch, Sharon Straus, Brian Haynes, Martin Dawes since November 1998. Updated by Jeremy Howick March 2009.
<http://www.cebm.net/index.aspx?o=1025> [Access date January 2013]
2. Atkins D, Best D, Briss PA, et al; GRADE Working Group. Grading quality of evidence and strength of recommendations. *BMJ* 2004 Jun 19;328(7454):1490.
<http://www.ncbi.nlm.nih.gov/pubmed/15205295>
3. Guyatt GH, Oxman AD, Vist GE, et al. GRADE: an emerging consensus on rating quality of evidence and strength of recommendations. *BMJ* 2008;336(7650):924-6.
<http://www.ncbi.nlm.nih.gov/pubmed/18436948>
4. Guyatt GH, Oxman AD, Kunz R, et al; GRADE Working Group. Going from evidence to recommendations. *BMJ* 2008 May 10;336(7652):1049-51.
<http://www.bmj.com/content/336/7652/1049.long>

2. PHIMOSIS

2.1 Background

At the end of the first year of life, retraction of the foreskin behind the glandular sulcus is possible in only about 50% of boys; this rises to approximately 89% by the age of 3 years. The incidence of phimosis is 8% in 6 to 7-year-olds and just 1% in males aged 16-18 years (1). The phimosis is either primary (physiological) with no sign of scarring, or secondary (pathological) to a scarring such as balanitis xerotica obliterans. Phimosis has to be distinguished from normal agglutination of the foreskin to the glans, which is a physiological phenomenon (2).

The paraphimosis must be regarded as an emergency situation: retraction of a too narrow prepuce behind the glans penis into the glanular sulcus may constrict the shaft and lead to oedema. It interferes with perfusion distally from the constrictive ring and brings a risk of consecutive necrosis.

2.2 Diagnosis

The diagnosis of phimosis and paraphimosis is made by physical examination.

If the prepuce is not retractable or only partly retractable and shows a constrictive ring on drawing back over the glans penis, a disproportion between the width of the foreskin and the diameter of the glans penis has to be assumed. In addition to the constricted foreskin, there may be adhesions between the inner surface of the prepuce and the glanular epithelium and/or a fraenum breve. A fraenum breve leads to a ventral deviation of the glans once the foreskin is retracted. If the tip remains narrow and glanular adhesions were separated, than the space is filled with urine during voiding causing the foreskin to balloon outward.

The paraphimosis is characterised by retracted foreskin with the constrictive ring localised at the level of the sulcus, which prevents replacement of the foreskin over the glans.

2.3 Treatment

Treatment of phimosis in children is dependent on the parents' preferences and can be plastic or radical circumcision after completion of the second year of life. Plastic circumcision has the objective of achieving a wide foreskin circumference with full retractability, while the foreskin is preserved (dorsal incision, partial circumcision). However, this procedure carries the potential for recurrence of the phimosis (3). In the same session, adhesions are released and an associated fraenum breve is corrected by fraenulotomy. Meatoplasty is added if necessary.

An absolute indication for circumcision is secondary phimosis. The indications in primary phimosis are recurrent balanoposthitis and recurrent urinary tract infections in patients with urinary tract abnormalities (4-7) (LE: 2; GR: B). Simple ballooning of the foreskin during micturition is not a strict indication for circumcision.

Routine neonatal circumcision to prevent penile carcinoma is not indicated. A recent metaanalysis could not find any risk in uncircumcised patient without a history of phimosis (8). Contraindications for circumcision are coagulopathy, an acute local infection and congenital anomalies of the penis, particularly hypospadias or buried penis, because the foreskin may be required for a reconstructive procedure (9,10).

Childhood circumcision has an appreciable morbidity and should not be recommended without a medical reason (11-14) (LE: 2; GR B). As a conservative treatment option of the primary phimosis, a corticoid ointment or cream (0.05-0.1%) can be administered twice a day over a period of 20-30 days with a success rate of more than 90 %. (15-18) (LE: 1; GR: A). A recurrence rate up to 17 % can be expected (19). This

treatment has no side effects and the mean bloodspot cortisol levels are not significantly different from an untreated group of patients (20) (LE: 1). The hypothalamic-pituitary-adrenal axis was not influenced by local corticoid treatment (21). Agglutination of the foreskin does not respond to steroid treatment (16) (LE: 2).

Treatment of paraphimosis consists of manual compression of the oedematous tissue with a subsequent attempt to retract the tightened foreskin over the glans penis. Injection of hyaluronidase beneath the narrow band may be helpful to release it (22) (LE: 4; GR: C). If this manoeuvre fails, a dorsal incision of the constrictive ring is required. Depending on the local findings, a circumcision is carried out immediately or can be performed in a second session.

2.4 Conclusions and recommendations on phimosis

Conclusion
Treatment for phimosis usually starts after two years of age or according to parents' preference.

Recommendations	LE	GR
In primary phimosis, conservative treatment with a corticoid ointment or cream has a success rate more than 90%.	1	A
In primary phimosis, recurrent balanoposthitis and recurrent UTI in patients with urinary tract abnormalities are indications for active intervention.	2	A
Secondary phimosis is an absolute indication for circumcision.	2	A
Paraphimosis is an emergency situation and treatment must not be delayed. If manual reposition fails, a dorsal incision of the constrictive ring is required.	4	A
Routine neonatal circumcision to prevent penile carcinoma is not indicated.	2	B

2.5 References

- Gairdner D. The fate of the foreskin: a study of circumcision. *Br Med J* 1949;2(4642):1433-7.
<http://www.ncbi.nlm.nih.gov/pubmed/15408299>
- Oster J. Further fate of the foreskin. Incidence of preputial adhesions, phimosis, and smegma among Danish schoolboys. *Arch Dis Child* 1968;43(288):200-3.
<http://www.ncbi.nlm.nih.gov/pubmed/5689532>
- Miernik A, Hager S, Frankenschmidt A. Complete removal of the foreskin-why? *Urol Int* 2011;86(4):383-7.
<http://www.ncbi.nlm.nih.gov/pubmed/21474914>
- Wiswell TE. The prepuce, urinary tract infections, and the consequences. *Pediatrics* 2000;105(4 Pt 1):860-2. [no abstract available]
<http://www.ncbi.nlm.nih.gov/pubmed/10742334>
- Hiraoka M, Tsukahara H, Ohshima Y, et al. Meatus tightly covered by the prepuce is associated with urinary tract infection. *Pediatr Int* 2002;44(6):658-62.
<http://www.ncbi.nlm.nih.gov/pubmed/12421265>
- To T, Agha M, Dick PT, et al. Cohort study on circumcision of newborn boys and subsequent risk of urinary tract infection. *Lancet* 1998;352(9143):1813-6.
<http://www.ncbi.nlm.nih.gov/pubmed/9851381>
- Herndon CDA, McKenna PH, Kolon TF, et al. A multicenter outcomes analysis of patients with neonatal reflux presenting with prenatal hydronephrosis. *J Urol* 1999;162(3 Pt 2):1203-8.
<http://www.ncbi.nlm.nih.gov/pubmed/10458467>
- Larke NL, Thomas SL, dos Santos Silva I, et al. Male circumcision and penile cancer: a systematic review and meta-analysis. *Cancer Causes Control* 2011 Aug;22(8):1097-110.
<http://www.ncbi.nlm.nih.gov/pubmed/21695385>
- Thompson HC, King LR, Knox E, et al. Report of the ad hoc task force on circumcision. *Pediatrics* 1975;56(4):610-1. [no abstract available]
<http://www.ncbi.nlm.nih.gov/pubmed/1174384>
- [No authors listed] American Academy of Pediatrics: Report of the Task Force on Circumcision. *Pediatrics* 1989 Aug;84(2):388-91. Erratum in *Pediatrics* 1989 Nov;84(5):761.
<http://www.ncbi.nlm.nih.gov/pubmed/2664697>
- Griffiths DM, Atwell JD, Freeman NV. A prospective study of the indications and morbidity of circumcision in children. *Eur Urol* 1985;11(3):184-7.
<http://www.ncbi.nlm.nih.gov/pubmed/4029234>

12. Christakis DA, Harvey E, Zerr DM, et al. A trade-off analysis of routine newborn circumcision. *Pediatrics* 2000;105(1 Pt 3):246-9.
<http://www.ncbi.nlm.nih.gov/pubmed/10617731>
13. Ross JH. Circumcision: Pro and con. In: Elder JS, ed. *Pediatric urology for the general urologist*. New York: Igaku-Shoin, 1996, pp. 49-56.
14. Hutcheson JC. Male neonatal circumcision: indications, controversies and complications. *Urol Clin N Amer* 2004;31(3):461-7.
<http://www.ncbi.nlm.nih.gov/pubmed/15313055>
15. Chu CC, Chen KC, Diau GY. Topical steroid treatment of phimosis in boys. *J Urol* 1999;162(3 Pt 1):861-3.
<http://www.ncbi.nlm.nih.gov/pubmed/10458396>
16. Ter Meulen PH, Delaere KP. A conservative treatment of phimosis on boys. *Eur Urol* 2001;40(2):196-9;discussion 200.
<http://www.ncbi.nlm.nih.gov/pubmed/11528198>
17. Elmore JM, Baker LA, Snodgrass WT. Topical steroid therapy as an alternative to circumcision for phimosis in boys younger than 3 years. *J Urol* 2002;168(4 Pt 2):1746-7; discussion 1747.
<http://www.ncbi.nlm.nih.gov/pubmed/12352350>
18. Zavras N, Christianakis E, Mpourikas D, et al. Conservative treatment of phimosis with fluticasone propionate 0.05%: a clinical study in 1185 boys. *J Pediatr Urol* 2009 Jun;5(3):181-5.
<http://www.ncbi.nlm.nih.gov/pubmed/19097823>
19. Reddy S, Jain V, Dubey M, et al. Local steroid therapy as the first-line treatment for boys with symptomatic phimosis - a long-term prospective study. *Acta Paediatr* 2012 Mar;101(3):e130-3.
<http://www.ncbi.nlm.nih.gov/pubmed/22103624>
20. Golubovic Z, Milanovic D, Vukadinovic V, et al. The conservative treatment of phimosis in boys. *Br J Urol* 1996;78(5):786-8.
<http://www.ncbi.nlm.nih.gov/pubmed/8976781>
21. Pileggi FO, Martinelli CE Jr, Tazima MF, et al. Is suppression of hypothalamic-pituitary-adrenal axis significant during clinical treatment of phimosis? *J Urol* 2010 Jun;183(6): 2327 -31.
<http://www.ncbi.nlm.nih.gov/pubmed/20400146>
22. DeVries CR, Miller AK, Packer MG. Reduction of paraphimosis with hyaluronidase. *Urology* 1996;48(3):464-5.
<http://www.ncbi.nlm.nih.gov/pubmed/8804504>

3. CRYPTORCHIDISM

3.1 Background

At 1 year of age, nearly 1% of all full-term male infants have cryptorchidism, which is the commonest congenital anomaly affecting the genitalia of newborn male infants (1). The most useful classification of cryptorchidism is into palpable and non-palpable testes, and clinical management is decided by the location and presence of the testes.

- Retractable testes require only observation because they may become ascendant. Although they have completed their descent, a strong cremasteric reflex may cause their retention in the groin (2).
- Bilateral, non-palpable testes and any suggestion of sexual differentiation problems (e.g. hypospadias) require urgent, mandatory endocrinological and genetic evaluation (3) (LE: 3; GR: B).

3.2 Diagnosis

Physical examination is the only way of differentiating between palpable or non-palpable testes. There is no benefit in performing ultrasound, computed tomography (CT), magnetic resonance imaging (MRI) or angiography.

Clinical examination includes a visual description of the scrotum and assessment of the child in both the supine and crossed-leg positions. The examiner should inhibit the cremasteric reflex with his/her non-dominant hand, immediately above the symphysis in the groin region, before touching or reaching for the scrotum. The groin region may be “milked” towards the scrotum in an attempt to move the testis into the scrotum. This manoeuvre also allows an inguinal testis to be differentiated from enlarged lymph nodes that could give the impression of an undescended testis. A retractile testis can generally be brought into the scrotum, where it will remain until a cremasteric reflex (touching the inner thigh skin) retracts it into the groin (4).

A unilateral, non-palpable testis and an enlarged contralateral testis suggest testicular absence or

atrophy, but this is not a specific finding and does not preclude surgical exploration. An inguinal, non-palpable testis requires specific visual inspection of the femoral, penile and perineal regions to exclude an ectopic testis. Diagnostic laparoscopy is the only examination that can reliably confirm or exclude an intra-abdominal, inguinal and absent/vanishing testis (non-palpable testis) (5). Before carrying out laparoscopic assessment, examination under general anaesthesia is recommended because some, originally non-palpable, testes become palpable under anaesthetic conditions.

3.3 Treatment

Treatment should be done as early as possible around 1 year of age, starting after 6 months and finishing preferably at 12 months of age, or 18 months at the latest (6-9). This timing is driven by the final adult results on spermatogenesis and hormone production, as well as the risk for tumours.

3.3.1 Medical therapy

Medical therapy using human chorionic gonadotrophin (hCG) or gonadotrophin-releasing hormone (GnRH) is based on the hormonal dependence of testicular descent, with maximum success rates of 20% (10,11). However, it must be taken into account that almost 20% of descended testes have the risk of reascending later.

Hormonal therapy for testicular descent has lower success rates, the higher the undescended testis is located. A total dose of 6000-9000 U hCG is given in four doses over a period of 2-3 weeks, depending on weight and age, along with GnRH, given for 4 weeks as a nasal spray at a dose of 1.2 mg/day, divided into three doses per day.

Medical treatment may be beneficial before surgical orchidolysis and orchidopexy (dosage as described earlier) or afterwards (low intermittent dosages), in terms of increasing the fertility index, which is a predictor for fertility in later life (12). Long-term follow-up data are still awaited. Nonetheless, it has been reported that hCG treatment may be harmful to future spermatogenesis through increased apoptosis of germ cells, including acute inflammatory changes in the testes and reduced testicular volume in adulthood. Therefore, the Nordic Consensus Statement on treatment of undescended testes does not recommend it on a routine basis because there is not sufficient evidence for a beneficial effect of hormonal treatment before or after surgery. However, this statement relied only on data from hormonal treatment using hCG (13).

3.3.2 Surgery

Palpable testis

Surgery for a palpable testis includes orchidofuniculolysis and orchidopexy, via an inguinal approach, with success rates of up to 92% (14). It is important to remove and dissect all cremasteric fibres to prevent secondary retraction. Associated problems, such as an open processus vaginalis, must be carefully dissected and closed. It is recommended that the testis is placed in a subdartos pouch. With regard to sutures, there should be no fixation sutures or they should be made between the tunica vaginalis and the dartos musculature. The lymph drainage of a testis that has undergone surgery for orchidopexy has been changed from iliac drainage to iliac and inguinal drainage (important in the event of later malignancy). Scrotal orchidopexy can also be an option in less-severe cases and when performed by surgeons with experience using that approach.

Non-palpable testis

Inguinal surgical exploration with possible laparoscopy should be attempted for non-palpable testes. There is a significant chance of finding the testis via an inguinal incision. In rare cases, it is necessary to search into the abdomen if there are no vessels or vas deferens in the groin. Laparoscopy is the best way of examining the abdomen for a testis. In addition, either removal or orchidolysis and orchidopexy can be performed via laparoscopic access (15).

For boys aged ≥ 10 years with an intra-abdominal testis, with a normal contralateral testis, removal is an option because of the theoretical risk of later malignancy. In bilateral intra-abdominal testes, or in boys younger than 10 years, a one-stage or two-stage Fowler-Stephens procedure can be performed. In the event of a two-stage procedure, the spermatic vessels are laparoscopically clipped or coagulated proximal to the testis to allow development of collateral vasculature (16). The second-stage procedure, in which the testis is brought directly over the symphysis and next to the bladder into the scrotum, can also be performed by laparoscopy 6 months later. The testicular survival rate in the one-stage procedure varies between 50 and 60%, with success rates increasing up to 90% for the two-stage procedure (17,18). Microvascular autotransplantation can also be performed with a 90% testicular survival rate. However, the procedure requires skilled and experienced surgeons (18).

3.4 Prognosis

Although boys with one undescended testis have a lower fertility rate, they have the same paternity rate as

those with bilateral descended testes. Boys with bilateral undescended testes have lower fertility and paternity rates.

Boys with an undescended testis have an increased risk of developing testicular malignancy. Screening both during and after puberty is therefore recommended for these boys. A Swedish study, with a cohort of almost 17,000 men who were treated surgically for undescended testis and followed for ~210,000 person-years, showed that treatment for undescended testis before puberty decreased the risk of testicular cancer. The relative risk of testicular cancer among those who underwent orchidopexy before 13 years of age was 2.23 when compared with the Swedish general population; this increased to 5.40 for those treated at \geq 13 years (19). A systematic review and meta-analysis of the literature have also concluded that prepubertal orchidopexy may decrease the risk of testicular cancer and that early surgical intervention is indicated in children with cryptorchidism (20).

Boys with retractile testes do not need medical or surgical treatment, but require close follow-up until puberty.

3.5 Recommendations for cryptorchidism

	LE	GR
Boys with retractile testes do not need medical or surgical treatment, but require close follow-up until puberty.	2	A
Surgical orchidolysis and orchidopexy should be concluded at the age of 12 months, or 18 months the latest.	3	B
In case of non-palpable testes and no evidence of disorders of sex development, laparoscopy still represents the gold standard because it has almost 100% sensitivity and specificity in identifying an intra-abdominal testis as well as the possibility for subsequent treatment in the same session.	1a	A
Hormonal therapy, either in an adjuvant or neo-adjuvant setting, is not standard treatment. Patients have to be evaluated on an individual basis.	2	C
For an intra-abdominal testis in a 10-year-old boy or older, with a normal contralateral testis, removal is an option because of the theoretical risk of a later malignancy.	3	B

3.6 References

- Berkowitz GS, Lapinski RH, Dolgin SE, et al. Prevalence and natural history of cryptorchidism. *Pediatrics* 1993 Jul;92(1):44-9.
<http://www.ncbi.nlm.nih.gov/pubmed/8100060>
- Caesar RE, Kaplan GW. The incidence of the cremasteric reflex in normal boys. *J Urol* 1994 Aug;152(2 Pt 2):779-80.
<http://www.ncbi.nlm.nih.gov/pubmed/7912745>
- Rajfer J, Walsh PC. The incidence of intersexuality in patients with hypospadias and cryptorchidism. *J Urol* 1976 Dec;116(6):769-70.
<http://www.ncbi.nlm.nih.gov/pubmed/12377>
- Rabinowitz R, Hulbert WC Jr. Late presentation of cryptorchidism: the etiology of testicular re-ascent. *J Urol* 1997 May;157(5):1892-4.
<http://www.ncbi.nlm.nih.gov/pubmed/9112557>
- Cisek LJ, Peters CA, Atala A, et al. Current findings in diagnostic laparoscopic evaluation of the nonpalpable testis. *J Urol* 1998 Sep;160(3 Pt 2):1145-9; discussion 1150.
<http://www.ncbi.nlm.nih.gov/pubmed/9719296>
- Huff DS, Hadziselimovic F, Snyder HM 3rd, et al. Histologic maldevelopment of unilaterally cryptorchid testes and their descended partners. *Eur J Pediatr* 1993;152 Suppl:S11-S14.
<http://www.ncbi.nlm.nih.gov/pubmed/8101802>
- Hadziselimovic F, Hocht B, Herzog B, et al. Infertility in cryptorchidism is linked to the stage of germ cell development at orchidopexy. *Horm Res* 2007;68(1):46-52.
<http://www.ncbi.nlm.nih.gov/pubmed/17356291>
- Huff DS, Hadziselimovic F, Duckett JW, et al. Germ cell counts in semithin sections of biopsies of 115 unilaterally cryptorchid testes. The experience from the Children's Hospital of Philadelphia. *Eur J Pediatr* 1987;146, Suppl 2:S25-7.
<http://www.ncbi.nlm.nih.gov/pubmed/2891515>

9. Hadziselimovic F, Herzog B. The importance of both an early orchidopexy and germ cell maturation for fertility. *Lancet* 2001 Oct 6;358(9288):1156-7.
<http://www.ncbi.nlm.nih.gov/pubmed/11597673>
10. Rajfer J, Handelsman DJ, Swerdloff RS, et al. Hormonal therapy of cryptorchidism. A randomized, double-blind study comparing human chorionic gonadotropin and gonadotropin-releasing hormone. *N Engl J Med* 1986 Feb;314(8):466-70.
<http://www.ncbi.nlm.nih.gov/pubmed/2868413>
11. Pyorala S, Huttunen NP, Uhari M. A review and meta-analysis of hormonal treatment of cryptorchidism. *J Clin Endocrinol Metab* 1995 Sep;80(9):2795-9.
<http://www.ncbi.nlm.nih.gov/pubmed/7673426>
12. Schwentner C, Oswald J, Kreczy A, et al. Neoadjuvant gonadotropin releasing hormone therapy before surgery may improve the fertility index in undescended testes - a prospective randomized trial. *J Urol* 2005 Mar;173(3):974-7.
<http://www.ncbi.nlm.nih.gov/pubmed/15711353>
13. Ritzén EM. Undescended testes: a consensus on management. *Eur J Endocrinol* 2008 Dec;159 Suppl 1:S87-90.
<http://www.ncbi.nlm.nih.gov/pubmed/18728121>
14. Docimo SG. The results of surgical therapy for cryptorchidism: a literature review and analysis. *J Urol* 1995 Sep;154:1148-52.
<http://www.ncbi.nlm.nih.gov/pubmed/7637073>
15. Jordan GH, Winslow BH. Laparoscopic single stage and staged orchiopexy. *J Urol* 1994 Oct;152(4):1249-52.
<http://www.ncbi.nlm.nih.gov/pubmed/7915336>
16. Bloom DA. Two-step orchiopexy with pelviscopic clip ligation of the spermatic vessels. *J Urol* 1991 May;145(5):1030-3.
<http://www.ncbi.nlm.nih.gov/pubmed/1673160>
17. Radmayr C, Oswald J, Schwentner C, et al. Long-term outcome of laparoscopically managed nonpalpable testes. *J Urol* 2003 Dec;170(6 Pt 1):2409-11.
<http://www.ncbi.nlm.nih.gov/pubmed/14634439>
18. Esposito C, Iacobelli S, Farina A, et al. Exploration of inguinal canal is mandatory in cases of non palpable testis if laparoscopy shows elements entering a closed inguinal ring. *Eur J Pediatr Surg* 2010 Mar;20(2):138-9.
<http://www.ncbi.nlm.nih.gov/pubmed/19746341>
19. Wacksman J, Billmire DA, Lewis AG, et al. Laparoscopically assisted testicular autotransplantation for management of the intraabdominal undescended testis. *J Urol* 1996 Aug;156(2 Pt 2):772-4.
<http://www.ncbi.nlm.nih.gov/pubmed/8683780>
20. Pettersson A, Richiardi L, Nordenskjold A, et al. Age at surgery for undescended testis and risk of testicular cancer. *N Engl J Med* 2007 May;356(18):1835-41.
<http://www.ncbi.nlm.nih.gov/pubmed/17476009>
21. Walsh TJ, Dall'Era MA, Croughan MS, et al. Prepubertal orchiopexy for cryptorchidism may be associated with a lower risk of testicular cancer. *J Urol* 2007 Oct;178(4 Pt 1):1440-6; discussion 1446.
<http://www.ncbi.nlm.nih.gov/pubmed/17706709>

4. HYDROCELE

4.1 Background

Hydrocele is defined as a collection of fluid between the parietal and visceral layer of tunica vaginalis (1). Pathogenesis of hydrocele is based on an imbalance between the secretion and reabsorption of this fluid. This is in contrast with inguinal hernia, which is defined as the protrusion of a portion of organs or tissues through the abdominal wall (2). Incomplete obliteration of the processus vaginalis peritonei results in formation of various types of communicating hydrocele alone or connected with other intrascrotal pathology (hernia). The exact time of spontaneous closure of the processus vaginalis is not known. It persists in approximately 80-94% of newborns and in 20% of adults (3). If complete obliteration of the processus vaginalis occurs with patency of midportion, a hydrocele of the cord occurs. Scrotal hydroceles without associated patency of the processus vaginalis are encountered in newborns as well (4). Non-communicating hydroceles are found secondary to minor trauma, testicular torsion, epididymitis, varicocele operation or may appear as a recurrence after primary repair of a communicating hydrocele.

4.2 Diagnosis

The classic description of a communicating hydrocele is that of a hydrocele that vacillates in size, and is usually related to activity. It may be diagnosed by history and physical investigation. Transillumination of the scrotum makes the diagnosis in the majority of cases, keeping in mind that fluid-filled intestine and some prepubertal tumours such as teratomas may transilluminate as well (5,6). If the diagnosis is that of a hydrocele, there will be no history of reducibility and no associated symptoms; the swelling is translucent, smooth and usually non-tender. If there are any doubts about the character of an intrascrotal mass, scrotal ultrasound should be performed and has nearly 100% sensitivity in detecting intrascrotal lesions. Doppler ultrasound studies help to distinguish hydroceles from varicocele and testicular torsion, although these conditions may also be accompanied by a hydrocele.

4.3 Treatment

In the majority of infants, the surgical treatment of hydrocele is not indicated within the first 12-24 months because of the tendency for spontaneous resolution (LE: 2; GR: B) (7). Little risk is taken by initial observation because progression to hernia is rare and does not result in incarceration (7). Early surgery is indicated if there is suspicion of a concomitant inguinal hernia or underlying testicular pathology (LE: 2; GR: B) (8,9). Persistence of a simple scrotal hydrocele beyond 24 months of age may be an indication for surgical correction. However, there is no evidence that this type of hydrocele risks testicular damage. The question of contralateral disease should be addressed by both history and physical examination at the time of initial consultation (LE: 2) (10). In late-onset hydrocele, suggestive of a non-communicating hydrocele, there is a reasonable chance of spontaneous resolution (75%) and expectant management of 6-9 months is recommended (11). In the paediatric age group, the operation consists of ligation of patent processus vaginalis via inguinal incision and the distal stump is left open, whereas in hydrocele of the cord the cystic mass is excised or unroofed (1,6,8) (LE: 4; GR: C). In expert hands, the incidence of testicular damage during hydrocele or inguinal hernia repair is very low (0.3%) (LE: 3; GR: B). Sclerosing agents should not be used because of the risk of chemical peritonitis in communicating processus vaginalis peritonei (6,8) (LE: 4; GR: C). The scrotal approach (Lord or Jaboulay technique) is used in the treatment of a secondary non-communicating hydrocele.

4.4 Recommendations for the management of hydrocele

Recommendations	LE	GR
In the majority of infants, surgical treatment of hydrocele is not indicated within the first 12-24 months due to the tendency for spontaneous resolution. Little risk is taken by initial observation because progression to hernia is rare.	2	B
Early surgery is indicated if there is suspicion of a concomitant inguinal hernia or underlying testicular pathology.	2	B
In case of doubts about the character of an intrascrotal mass, scrotal ultrasound should be performed.	4	C
In the paediatric age group, an operation would generally involve ligation of the patent processus vaginalis via inguinal incision. Sclerosing agents should not be used because of the risk for chemical peritonitis.	4	C

4.5 References

1. Kapur P, Caty MG, Glick PL. Pediatric hernias and hydroceles. *Pediatric Clin North Am* 1998 Aug;45(4):773-89. [no abstract available]
<http://www.ncbi.nlm.nih.gov/pubmed/9728185>
2. Barthold JS, Kass EJ. Abnormalities of the penis and scrotum. In: Belman AB, King LR, Kramer SA, eds. *Clinical pediatric urology*. 4th edn. London: Martin Dunitz, 2002, pp. 1093-1124.
3. Schneck FX, Bellinger MF. Abnormalities of the testes and scrotum and their surgical management. In: Walsh PC, Retik AB, Vaughan ED, Wein AJ, eds. *Campbell's urology*. 8th edn. Philadelphia: WB Saunders, 2002, pp. 2353-94.
4. Rubenstein RA, Dogra VS, Seftel AD, et al. Benign intrascrotal lesions. *J Urol* 2004 May;171(5): 1765-72.
<http://www.ncbi.nlm.nih.gov/pubmed/15076274>
5. Lin HC, Clark JY. Testicular teratoma presenting as a transilluminating scrotal mass. *Urology* 2006 Jun;67(6):1290.e3-5.
<http://www.ncbi.nlm.nih.gov/pubmed/16750249>

6. Skoog SJ. Benign and malignant pediatric scrotal masses. *Pediatr Clin North Am* 1997 Oct;44(5):1229-50.
<http://www.ncbi.nlm.nih.gov/pubmed/9326960>
7. Koski ME, Makari JH, Adams MC, et al. Infant communicating hydroceles--do they need immediate repair or might some clinically resolve? *J Pediatr Surg* 2010 Mar;45(3):590-3.
<http://www.ncbi.nlm.nih.gov/pubmed/20223325>
8. Stringer MD, Godbole PP. Patent processus vaginalis. In: Gearhart JP, Rink RC, Mouriquand PD, eds. *Pediatric urology*. Philadelphia: WB Saunders, 2001, pp. 755-762.
9. Stylianios S, Jacir NN, Harris BH. Incarceration of inguinal hernia in infants prior to elective repair. *J Pediatr Surg* 1993 Apr;28(4):582-3.
<http://www.ncbi.nlm.nih.gov/pubmed/8483072>
10. Saad S, Mansson J, Saad A, et al. Ten-year review of groin laparoscopy in 1001 pediatric patients with clinical unilateral inguinal hernia: an improved technique with transhernia multiple-channel scope. *J Pediatr Surg* 2011 May;46(5):1011-4.
<http://www.ncbi.nlm.nih.gov/pubmed/21616272>
11. Christensen T, Cartwright PC, DeVries C, et al. New onset of hydroceles in boys over 1 year of age. *Int J Urol* 2006 Nov;13(11):1425-7.
<http://www.ncbi.nlm.nih.gov/pubmed/17083397>

5. ACUTE SCROTUM IN CHILDREN

5.1 Background

Acute scrotum is a paediatric urological emergency, most commonly caused by torsion of the testis or appendix testis, or epididymitis/epididymo-orchitis (1-6). Other causes of acute scrotal pain are idiopathic scrotal oedema, mumps orchitis, varicocele, scrotal haematoma, incarcerated hernia, appendicitis or systemic disease (e.g. Henoch-Schönlein purpura) (7-19).

Torsion of the testis occurs most often in the neonatal period and around puberty, whereas torsion of the appendix testes occurs over a wider age range. Acute epididymitis affects two age groups: < 1 year and 12-15 years (5,20,21). Acute epididymitis is found most often (37-64.6%) in boys with acute scrotum (1-4). One study predicted the annual incidence of epididymitis as about 1.2 per 1,000 children (22).

5.2 Diagnosis

Patients usually present with scrotal pain. The duration of symptoms is shorter in testicular torsion (69% present within 12 h) compared to torsion of the appendix testes (62%) and acute epididymitis (31%) (5,6,20).

In the early phase, location of the pain can lead to diagnosis. Patients with acute epididymitis experience a tender epididymis, whereas patients with testicular torsion are more likely to have a tender testicle, and patients with torsion of the appendix testis feel isolated tenderness of the superior pole of the testis (20).

An abnormal position of the testis is more frequent in testicular torsion than epididymitis (20). Looking for absence of the cremasteric reflex is a simple method with 100% sensitivity and 66% specificity for testicular torsion (21,23) (LE:3; GR: C).

Fever occurs often in epididymitis (11-19%). The classical sign of a "blue dot" was found only in 10-23% of patients with torsion of the appendix testis (4,6,21,24).

In many cases, it is not easy to determine the cause of acute scrotum based on history and physical examination alone (1-6,21,24).

A positive urine culture is only found in a few patients with epididymitis (3,21,24,25). It should be remembered that a normal urinalysis does not exclude epididymitis. Similarly, an abnormal urinalysis does not exclude testicular torsion.

Doppler ultrasound is useful to evaluate acute scrotum, with 63.6-100% sensitivity and 97-100% specificity, and a positive predictive value of 100% and negative predictive value 97.5% (26-31) (LE: 3).

The use of Doppler ultrasound may reduce the number of patients with acute scrotum undergoing scrotal exploration, but it is operator-dependent and can be difficult to perform in prepubertal patients (29,32). It may also show a misleading arterial flow in the early phases of torsion and in partial or intermittent torsion: persistent arterial flow does not exclude testicular torsion. In a multicentre study of 208 boys with torsion of the testis, 24% had normal or increased testicular vascularisation (29). Better results were reported using high-resolution ultrasonography (HRUS) for direct visualisation of the spermatic cord twist with a sensitivity of 97.3% and specificity of 99% (29,33) (LE: 2; GR: C).

Scintigraphy and, more recently, dynamic contrast-enhanced subtraction MRI of the scrotum also provide a comparable sensitivity and specificity to ultrasound (34-37). These investigations may be used when diagnosis is less likely and if torsion of the testis still cannot be excluded from history and physical examination. This should be done without inordinate delays for emergency intervention (24).

The diagnosis of acute epididymitis in boys is mainly based on clinical judgement and adjunctive investigation. However, it should be remembered that findings of secondary inflammatory changes in the absence of evidence of an extra-testicular nodule by Doppler ultrasound might suggest an erroneous diagnosis of epididymitis in children with torsion of appendix testes (38).

Prepubertal boys with acute epididymitis have an incidence of underlying urogenital anomalies of 25-27.6%. Complete urological evaluation in all children with acute epididymitis is still debatable (3,21,22).

5.3 Treatment

5.3.1 Epididymitis

In prepubertal boys, the aetiology is usually unclear, with an underlying pathology of about 25%. A urine culture is usually negative, and unlike in older boys, a sexually transmitted disease is very rare.

Antibiotic treatment, although often started, is not indicated in most cases unless urinalysis and urine culture show a bacterial infection (22,39). Epididymitis is usually self-limiting and with supportive therapy (i.e. minimal physical activity and analgesics) heals without any sequelae (LE: 3; GR: C). However, bacterial epididymitis can be complicated by abscess or necrotic testis and surgical exploration is required (40).

Torsion of the appendix testis can be managed conservatively (LE: 4; GR: C). During the six-week follow-up, clinically and with ultrasound, no testicular atrophy was revealed. Surgical exploration is done in equivocal cases and in patients with persistent pain (27).

5.3.2 Testicular torsion

Manual detorsion of the testis is done without anaesthesia. It should initially be done by outwards rotation of the testis unless the pain increases or if there is obvious resistance. Success is defined as the immediate relief of all symptoms and normal findings at physical examination (41) (LE: 3; GR: C). Doppler ultrasound may be used for guidance (42).

Bilateral orchiopexy is still required after successful detorsion. This should not be done as an elective procedure, but rather immediately following detorsion. One study reported residual torsion during exploration in 17 out of 53 patients, including 11 patients who had reported pain relief after manual detorsion (41,43).

5.3.3 Surgical treatment

Testicular torsion is an urgent condition, which requires prompt surgical treatment. The two most important determinants of early salvage rate of the testis are the time between onset of symptoms and detorsion, and the degree of cord twisting (44). Severe testicular atrophy occurred after torsion for as little as 4 h when the turn was $> 360^\circ$. In cases of incomplete torsion ($180-360^\circ$), with symptom duration up to 12 h, no atrophy was observed. However, an absent or severely atrophied testis was found in all cases of torsion $> 360^\circ$ and symptom duration > 24 h (45).

Early surgical intervention with detorsion (mean torsion time < 13 h) was found to preserve fertility (46). Urgent surgical exploration is mandatory in all cases of testicular torsion within 24 h of symptom onset.

In patients with testicular torsion > 24 h, semi-elective exploration is necessary (44,45) (LE: 3). There is still controversy on whether to carry out detorsion and to preserve the ipsilateral testis, or to perform an orchiectomy, in order to preserve contralateral function and fertility after testicular torsion of long duration (> 24 h).

A recent study in humans found that sperm quality was preserved after orchiectomy and orchidopexy in comparison to normal control men, although orchiectomy resulted in better sperm morphology (47).

During exploration, fixation of the contralateral testis is also performed. Recurrence after orchidopexy is rare (4.5%) and may occur several years later. There is no common recommendation about the preferred type of fixation and suture material; however, many urologists currently use a Dartos pouch orchidopexy (48).

External cooling before exploration and several medical treatments seem effective in reducing ischaemia-reperfusion injury and preserving the viability of the torsed and the contralateral testis (49-53).

5.4 Prognosis

5.4.1 Fertility

The results vary and are conflicting. In one study, unilateral torsion of the testis seriously intervened with subsequent spermatogenesis in about 50% of the patients and produced borderline impairment in another 20%.

5.4.2 **Subfertility**

Subfertility is found in 36-39% of the patients after torsion. Semen analysis may be normal in only 5-50% in long-term follow-up (44). Early surgical intervention (mean torsion time < 13 h) with detorsion was found to preserve fertility, but a prolonged torsion period (mean 70 h) followed by orchiectomy jeopardised fertility (46).

One study identified sperm antibodies in the semen of patients with testicular torsion and correlated antibody levels with infertility, while others have failed to confirm these results (44,47).

Anderson, et al. found pre-existing contralateral testis abnormalities in biopsies performed at the time of surgery and did not detect any case of sperm antibodies after testicular torsion (46).

5.4.3 **Androgen levels**

A study in rats showed a long-term reduction in testicular androgen production after testicular torsion. This effect was considered to be caused by reperfusion/oxidative stress in the testis (45). Even though the levels of FSH, LH and testosterone are higher in patients after testicular torsion compared to normal controls, endocrine testicular function remains in the normal range after testicular torsion (47).

5.4.4 **Testicular cancer**

There may be a 3.2-fold increased risk of developing a testis tumour 6-13 years after torsion. However, two of nine reported cases had torsion of a tumour-bearing testis and four had a tumour in the contralateral testis (44).

5.4.5 **Nitric oxide**

A study in rats found that spermatic cord torsion did not lead to impairment in nitric oxide (NO)-mediated relaxant responses of the isolated penile bulb (54).

5.5 **Perinatal torsion**

Perinatal torsion of the testis most often occurs prenatally. After birth, perinatal torsion occurs in 25%. Bilateral torsion comprises 11-21% of all perinatal cases (55). Most cases are extravaginal in contrast to the usual intravaginal torsion, which occurs during puberty.

Intrauterine torsion may present as:

- testicular nubbin;
- small and hard testis;
- normal-sized and hard testis;
- acute scrotum.

Torsion occurring in the first postnatal month presents with signs of acute scrotum. The clinical signs correlate well with surgical and histological findings and thus define the need and urgency to explore the history (56).

Doppler ultrasound can be an additional diagnostic tool. The diagnostic sensitivity for testicular torsion is high, although the specificity is unknown for neonates. Doppler ultrasound may also be used to exclude congenital testicular neoplasm (57). Neonates with acute scrotal signs as well as bilateral cases should be treated as surgical emergencies (56,58).

In cases of postnatal torsion, one study reported 40% of testes were salvaged with emergency exploration (59). The contralateral scrotum should also be explored because of the risk of asynchronous contralateral testicular torsion in as many as 33% of cases (58).

5.6 **Recommendations acute scrotum in children**

	LE	GR
Acute scrotum is a paediatric urological emergency and intervention should not be delayed.		
Neonates with acute scrotum, and bilateral cases, should be treated as surgical emergencies. In neonates, the contralateral scrotum should also be explored.	3	C
Doppler ultrasound is a highly effective imaging tool to evaluate acute scrotum and comparable to scintigraphy and dynamic contrast-enhanced subtraction MRI.		
High-resolution ultrasonography is better for direct visualisation of spermatic cord twisting.	3	C
Torsion of the appendix testis can be managed conservatively but in equivocal cases and in patients with persistent pain, surgical exploration is indicated.		
Urgent surgical exploration is mandatory in all cases of testicular torsion within 24 h of symptom onset.	3	C

5.7 References

1. Varga J, Zivkovic D, Grebeldinger S, et al. Acute scrotal pain in children-ten years' experience. *Urol Int* 2007;78(1):73-7.
<http://www.ncbi.nlm.nih.gov/pubmed/17192737>
2. Cavusoglu YH, Karaman A, Karaman I, et al. Acute scrotum-etiology and management. *Indian J Pediatr* 2005 Mar;72(3):201-3.
<http://www.ncbi.nlm.nih.gov/pubmed/15812112>
3. Sakellaris GS, Charissis GC. Acute epididymitis in Greek children: a 3-year retrospective study. *Eur J Pediatr* 2008 Jul;167(7):765-9.
<http://www.ncbi.nlm.nih.gov/pubmed/17786475>
4. Klin B, Zlotkevich L, Horne T, et al. Epididymitis in childhood: a clinical retrospective study over 5 years. *Isr Med Assoc J* 2001 Nov;3(11):833-5.
<http://www.ncbi.nlm.nih.gov/pubmed/11729579>
5. McAndrew HF, Pemberton R, Kikiros CS, et al. The incidence and investigation of acute scrotal problems in children. *Pediatr Surg Int* 2002 Sep;18(5-6): 435-7.
<http://www.ncbi.nlm.nih.gov/pubmed/12415374>
6. Makela E, Lahdes-Vasama T, Rajakorpi H, et al. A 19-year review of paediatric patients with acute scrotum. *Scan J Surg* 2007;96(1):62-6.
<http://www.ncbi.nlm.nih.gov/pubmed/17461315>
7. Klin B, Lotan G, Efrati Y, et al. Acute idiopathic scrotal edema in children-revisited. *J Pediatr Surg* 2002 Aug;37(8):1200-2.
<http://www.ncbi.nlm.nih.gov/pubmed/12149702>
8. Van Langen AM, Gal S, Hulsmann AR, et al. Acute idiopathic scrotal oedema: four cases and short review. *Eur J Pediatr* 2001 Jul;160(7):455-6.
<http://www.ncbi.nlm.nih.gov/pubmed/11475590>
9. Hara Y, Tajiri T, Matsuura K, et al. Acute scrotum caused by Henoch-Schonlein purpura. *Int J Urology* 2004 Jul;11(7):578-80.
<http://www.ncbi.nlm.nih.gov/pubmed/15242376>
10. Singh S, Adivarekar P, Karmarkar SJ. Acute scrotum in children: a rare presentation of acute, nonperforated appendicitis. *Pediatr Surg Int* 2003 Jun;19(4):298-9.
<http://www.ncbi.nlm.nih.gov/pubmed/12682749>
11. Bingol-Kologlu M, Fedakar M, Yagmurlu A, et al. An exceptional complication following appendectomy: acute inguinal and scrotal suppuration. *Int Urol Nephrol* 2006;38(3-4):663-5.
<http://www.ncbi.nlm.nih.gov/pubmed/17160451>
12. Ng KH, Chung YFA, Wilde CC, et al. An unusual presentation of acute scrotum after appendicitis. *Singapore Med J* 2002 Jul;43(7):365-6.
<http://www.ncbi.nlm.nih.gov/pubmed/12437045>
13. Dayanir YO, Akdilli A, Karaman CZ, et al. Epididymoorchitis mimicking testicular torsion in Henoch-Schonlein purpura. *Eur Radiol* 2001;11(11):2267-9.
<http://www.ncbi.nlm.nih.gov/pubmed/11702171>
14. Krause W. Is acute idiopathic scrotal edema in children a special feature of neutrophilic eccrine hidradenitis? *Dermatology* 2004;208(1):86.
<http://www.ncbi.nlm.nih.gov/pubmed/14730248>
15. Diamond DA, Borer JG, Peters CA, et al. Neonatal scrotal haematoma: mimicker of neonatal testicular torsion. *BJU Int* 2003 May;91:675-7.
<http://www.ncbi.nlm.nih.gov/pubmed/12699483>
16. Vlazakis S, Vlahakis I, Kakavelakis KN, et al. Right acute hemiscrotum caused by insertion of an inflamed appendix. *BJU Int* 2002 Jun;89(9):967-8. [no abstract available]
<http://www.ncbi.nlm.nih.gov/pubmed/12010250>
17. Ha TS, Lee JS. Scrotal involvement in childhood Henoch-Schonlein purpura. *Acta Paediatr* 2007 Apr;96(4):552-5.
<http://www.ncbi.nlm.nih.gov/pubmed/17306010>
18. Myers JB, Lovell MA, Lee RS, et al. Torsion of an indirect hernia sac causing acute scrotum. *J Pediatr Surg* 2004 Jan;39(1):122-3.
<http://www.ncbi.nlm.nih.gov/pubmed/14694389>
19. Matsumoto A, Nagatomi Y, Sakai M, et al. Torsion of the hernia sac within a hydrocele of the scrotum in a child. *Int J Urol* 2004 Sep;11(9):789-91.
<http://www.ncbi.nlm.nih.gov/pubmed/15379947>

20. Sauvat F, Hennequin S, Slimane MAA, et al. [Age for testicular torsion?] Arch Pediatr 2002 Dec;9(12):1226-9. [article in French]
<http://www.ncbi.nlm.nih.gov/pubmed/12536102>
21. Kadish HA, Bolte RG. A retrospective review of pediatric patients with epididymitis, testicular torsion, and torsion of testicular appendages. Pediatrics 1998 Jul;102(1 Pt 1):73-6.
<http://www.ncbi.nlm.nih.gov/pubmed/9651416>
22. Somekh E, Gorenstein A, Serour F. Acute epididymitis in boys: evidence of a post-infectious etiology. J Urol 2004 Jan;171(1):391-4.
<http://www.ncbi.nlm.nih.gov/pubmed/14665940>
23. Nelson CP, Williams JF, Bloom DA. The cremaster reflex: a useful but imperfect sign in testicular torsion. J Pediatr Surg 2003 Aug;38(8):1248-9.
<http://www.ncbi.nlm.nih.gov/pubmed/12891505>
24. Mushtaq I, Fung M, Glasson MJ. Retrospective review of pediatric patients with acute scrotum. ANZ J Surg 2003 Jan-Feb;73(1-2):55-8.
<http://www.ncbi.nlm.nih.gov/pubmed/12534742>
25. Murphy FL, Fletcher L, Pease P. Early scrotal exploration in all cases is the investigation and intervention of choice in the acute paediatric scrotum. Pediatr Surg Int 2006 may;22(5):413-6.
<http://www.ncbi.nlm.nih.gov/pubmed/16602024>
26. Baker LA, Sigman D, Mathews RI, et al. An analysis of clinical outcomes using color doppler testicular ultrasound for testicular torsion. Pediatrics 2000 Mar;105(3 Pt 1):604-7.
<http://www.ncbi.nlm.nih.gov/pubmed/10699116>
27. Schalamon J, Ainoedhofer H, Schleef J, et al. Management of acute scrotum in children-the impact of Doppler ultrasound. J Pediatr Surg 2006 Aug;41(8):1377-80.
<http://www.ncbi.nlm.nih.gov/pubmed/16863840>
28. Gunther P, Schenk JP, Wunsch R, et al. Acute testicular torsion in children: the role of sonography in the diagnostic workup. Eur Radiol 2006 Nov;16(11):2527-32.
<http://www.ncbi.nlm.nih.gov/pubmed/16724203>
29. Kalfa N, Veyrac C, Lopez M, et al. Multicenter assessment of ultrasound of the spermatic cord in children with acute scrotum. J Urol 2007 Jan;177(1):297-301.
<http://www.ncbi.nlm.nih.gov/pubmed/17162068>
30. Karmazyn B, Steinberg R, Kornreich L, et al. Clinical and sonographic criteria of acute scrotum in children: a retrospective study of 172 boys. Pediatr Radiol 2005 Mar;35(3):35:302-10.
<http://www.ncbi.nlm.nih.gov/pubmed/15503003>
31. Lam WW, Yap TL, Jacobsen AS, et al. Colour Doppler ultrasonography replacing surgical exploration for acute scrotum: myth or reality? Pediatr Radiol 2005 Jun;35(6):597-600.
<http://www.ncbi.nlm.nih.gov/pubmed/15761770>
32. Pepe P, Panella P, Pennisi M, et al. Does color Doppler sonography improve the clinical assessment of patients with acute scrotum? Eur J Radiol 2006 Oct;60(1):120-4.
<http://www.ncbi.nlm.nih.gov/pubmed/16730939>
33. Kalfa N, Veyrac C, Baud C, et al. Ultrasonography of the spermatic cord in children with testicular torsion: impact on the surgical strategy. J Urol 2004 Oct;172(4 Pt 2):1692-5.
<http://www.ncbi.nlm.nih.gov/pubmed/15371792>
34. Yuan Z, Luo Q, Chen L, et al. Clinical study of scrotum scintigraphy in 49 patients with acute scrotal pain: a comparison with ultrasonography. Ann Nucl Med 2001 Jun;15(3):225-9.
<http://www.ncbi.nlm.nih.gov/pubmed/11545192>
35. Nussbaum Blask, Bulas D, Shalaby-Rana E, et al. Color Doppler sonography and scintigraphy of the testis: a prospective, comparative analysis in children with acute scrotal pain. Pediatr Emerg Care 2002 Apr;18(2):67-71.
<http://www.ncbi.nlm.nih.gov/pubmed/11973493>
36. Paltiel HJ, Connolly LP, Atala A, et al. Acute scrotal symptoms in boys with an indeterminate clinical presentation: comparison of color Doppler sonography and scintigraphy. Radiology 1998 Apr;207:223-31.
<http://radiology.rsnajnl.org/cgi/content/abstract/207/1/223>
37. Terai A, Yoshimura K, Ichioka K, et al. Dynamic contrast-enhanced subtraction magnetic resonance imaging in diagnostics of testicular torsion. Urology 2006 Jun;67(6):1278-82.
<http://www.ncbi.nlm.nih.gov/pubmed/16765192>
38. Karmazyn B, Steinberg R, Livne P, et al. Duplex sonographic findings in children with torsion of the testicular appendages: overlap with epididymitis and epididymoorchitis. J Pediatr Surg 2006 Mar;41(3):500-4.
<http://www.ncbi.nlm.nih.gov/pubmed/16516624>

39. Lau P, Anderson PA, Giacomantonio JM, et al. Acute epididymitis in boys: are antibiotics indicated? *Br J Urol* 1997 May;79(5):797-800.
<http://www.ncbi.nlm.nih.gov/pubmed/9158522>
40. Abul F, Al-Sayer H, Arun N. The acute scrotum: a review of 40 cases. *Med Princ Pract* 2005 May-Jun;14(3):177-81.
<http://www.ncbi.nlm.nih.gov/pubmed/15863992>
41. Cornel EB, Karthaus HF. Manual derotation of the twisted spermatic cord. *BJU Int* 1999 Apr;83(6):672-4.
<http://www.ncbi.nlm.nih.gov/pubmed/10233577>
42. Garel L, Dubois J, Azzie G, et al. Preoperative manual detorsion of the spermatic cord with Doppler ultrasound monitoring in patients with intravaginal acute testicular torsion. *Pediatr Radiol* 2000 Jan;30(1):41-4.
<http://www.ncbi.nlm.nih.gov/pubmed/10663509>
43. Sessions AE, Rabinowitz R, Hulbert WC, et al. Testicular torsion: direction, degree, duration and disinformation. *J Urol* 2003 Feb;169(2):663-5.
<http://www.ncbi.nlm.nih.gov/pubmed/12544339>
44. Visser AJ, Heyns CF. Testicular function after torsion of the spermatic cord. *BJU Int* 2003 Aug;92(3):200-3.
<http://www.ncbi.nlm.nih.gov/pubmed/12887467>
45. Tryfonas G, Violaki A, Tsikopoulos G, et al. Late postoperative results in males treated for testicular torsion during childhood. *J Pediatr Surg* 1994 Apr;29(4):553-6.
<http://www.ncbi.nlm.nih.gov/pubmed/8014814>
46. Anderson MJ, Dunn JK, Lishultz LI, et al. Semen quality and endocrine parameters after acute testicular torsion. *J Urol* 1992 Jun;147(6):1545-50.
<http://www.ncbi.nlm.nih.gov/pubmed/1593686>
47. Arap MA, Vicentini FC, Cocuzza M, et al. Late hormonal levels, semen parameters, and presence of antisperm antibodies in patients treated for testicular torsion. *J Androl* 2007 Jul-Aug;28(4):528-32.
<http://www.ncbi.nlm.nih.gov/pubmed/17287456>
48. Mor Y, Pinthus JH, Nadu A, et al. Testicular fixation following torsion of the spermatic cord- does it guarantee prevention of recurrent torsion events? *J Urol* 2006 Jan;175(1):171-4.
<http://www.ncbi.nlm.nih.gov/pubmed/16406900>
49. Haj M, Shasha SM, Loberant N, et al. Effect of external scrotal cooling on the viability of the testis with torsion in rats. *Eur Surg Res* 2007;39(3):160-9.
<http://www.ncbi.nlm.nih.gov/pubmed/17341878>
50. Aksoy H, Yapanoglu T, Aksoy Y, et al. Dehydroepiandrosterone treatment attenuates reperfusion injury after testicular torsion and detorsion in rats. *J Pediatr Surg* 2007 Oct;42(10):1740-4.
<http://www.ncbi.nlm.nih.gov/pubmed/17923206>
51. Akcora B, Altug ME, Kontas T, et al. The protective effect of darbepoetin alfa on experimental testicular torsion and detorsion injury. *Int J Urol* 2007 Sep;14(9):846-50.
<http://www.ncbi.nlm.nih.gov/pubmed/17760753>
52. Yazihan N, Ataoglu H, Koku N, et al. Protective role of erythropoietin during testicular torsion of the rats. *World J Urol* 2007 Oct;25(5):531-6.
<http://www.ncbi.nlm.nih.gov/pubmed/17690891>
53. Unal D, Karatas OF, Savas M, et al. Protective effects of trimetazidine on testicular ischemiareperfusion injury in rats. *Urol Int* 2007;78(4):356-62.
<http://www.ncbi.nlm.nih.gov/pubmed/17495496>
54. Ozkan MH, Vural IM, Moralioglu S, et al. Torsion/detorsion of the testis does not modify responses to nitric oxide in rat isolated penile bulb. *Basic Clin Pharmacol Toxicol* 2007 Aug;101(2):117-20.
<http://www.ncbi.nlm.nih.gov/pubmed/17651313>
55. Yerkes EB, Robertson FM, Gitlin J, et al. Management of perinatal torsion: today, tomorrow or never? *J Urol* 2005 Oct;174(4 Pt 2):1579-83.
<http://www.ncbi.nlm.nih.gov/pubmed/16148656>
56. Cuervo JL, Grillo A, Vecchiarelli C, et al. Perinatal testicular torsion: a unique strategy. *J Pediatr Surg* 2007 Apr;42:699-703.
<http://www.ncbi.nlm.nih.gov/pubmed/17448769>
57. Van der Sluijs JW, Den Hollander JC, Lequin MH, et al. Prenatal testicular torsion: diagnosis and natural course. An ultrasonographic study. *Eur Radiol* 2004 Feb;14(2):250-5.
<http://www.ncbi.nlm.nih.gov/pubmed/12955451>

58. Baglaj M, Carachi R. Neonatal bilateral testicular torsion: a plea for emergency exploration. *J Urol* 2007 Jun;177(6):2296-9.
<http://www.ncbi.nlm.nih.gov/pubmed/17509343>
59. Sorensen MD, Galansky SH, Striegl AM, et al. Perinatal extravaginal torsion of the testis in the first month of life is a salvageable event. *Urology* 2003 Jul;62(1):132-4.
<http://www.ncbi.nlm.nih.gov/pubmed/12837441>

6. HYPOSPADIAS

6.1 Background

Hypospadias can be defined as hypoplasia of the tissues forming the ventral aspect of the penis beyond the division of the corpus spongiosum. Hypospadias is usually classified based on the anatomical location of the proximally displaced urethral orifice:

- Distal-anterior hypospadias (located on the glans or distal shaft of the penis and the most common type of hypospadias)
- Intermediate-middle (penile).
- Proximal-posterior (penoscrotal, scrotal, perineal).

The pathology may be much more severe after skin release.

6.1.1 Risk factors

Risk factors associated with hypospadias are likely to be genetic, placental and/or environmental (1) (LE: 2b):

- An additional member with hypospadias is found in 7% of families (2).
- Endocrine disorders can be detected in a very few cases.
- Babies of young or old mothers and babies with a low birth weight have a higher risk of hypospadias (2).
- A significant increase in the incidence of hypospadias over the last 20 years suggests a role for environmental factors (hormonal disruptors and pesticides) (3-6). This information has been questioned recently (7).
- The use of oral contraceptives prior to pregnancy has not been associated with an increased risk of hypospadias in the offspring (8) (LE: 2a).

6.2 Diagnosis

Patients with hypospadias should be diagnosed at birth (except for the megameatus intact prepuce variant).

Diagnosis includes a description of the local findings:

- Position, shape and width of the orifice
- Presence of atretic urethra and division of corpus spongiosum
- Appearance of the preputial hood and scrotum
- Size of the penis
- Curvature of the penis on erection.

The diagnostic evaluation also includes an assessment of associated anomalies, which are:

- Cryptorchidism (in up to 10% of cases of hypospadias)
- Open processus vaginalis or inguinal hernia (in 9-15%).

Severe hypospadias with unilaterally or bilaterally impalpable testis, or with ambiguous genitalia, requires a complete genetic and endocrine work-up immediately after birth to exclude intersexuality, especially congenital adrenal hyperplasia.

Urine trickling and ballooning of the urethra require exclusion of meatal stenosis.

The incidence of anomalies of the upper urinary tract does not differ from the general population, except in very severe forms of hypospadias (3,4).

6.3 Treatment

Differentiation between functionally necessary and aesthetically feasible operative procedures is important for therapeutic decision-making.

The functional indications for surgery are:

- Proximally located meatus
- Ventrally deflected urinary stream
- Meatal stenosis
- Curved penis.

The cosmetic indications, which are strongly linked to the psychology of the parent or the patient's future psychology, are:

- Abnormally located meatus
- Cleft glans
- Rotated penis with abnormal cutaneous raphe
- Preputial hood
- Penoscrotal transposition
- Split scrotum.

As all surgical procedures carry the risk of complications, thorough pre-operative counselling of the parents is crucial.

The therapeutic objectives are to correct the penile curvature, to form a neo-urethra of an adequate size, to bring the neomeatus to the tip of the glans, if possible, and to achieve an overall acceptable cosmetic appearance of the boy's genitalia (3,4) (LE: 4) (Figure 1).

The use of magnifying spectacles and special fine synthetic absorbable suture materials (6/0-7/0) are required. As in any penile surgery, an exceptional prudence should be adopted with the use of cautery. Knowledge of a variety of surgical reconstructive techniques, wound care and post-operative treatment are essential for a satisfactory outcome. Pre-operative hormonal treatment with local or parenteral application of testosterone, dihydrotestosterone or beta-chorionic gonadotropin can be helpful in patients with a small penis or for repeat surgery. In order to prevent healing complications, it is recommended to postpone the surgery for 3 months after completion of hormonal therapy (9) (LE: 2b).

6.3.1 Age at surgery

The age at surgery for primary hypospadias repair is usually 6-18 (24) months (3) (LE: 4). However, earlier repair between 4 and 6 months of age has been reported recently (LE: 3) (10).

6.3.2 Penile curvature

If present, penile curvature is often released by degloving the penis (skin chordee) and by excision of the connective tissue of the genuine chordee on the ventral aspect of the penis in up to 70% of patients (11). The urethral plate has well vascularized connective tissue and does not cause curvature in most cases. The residual curvature is caused by corporeal disproportion and requires straightening of the penis, mostly using dorsal midline plication or orthoplasty or ventral corporotomies with or without grafting (12,13) (LE: 2b).

6.3.3 Preservation of the well-vascularized urethral plate

The mainstay of hypospadias repair is preservation of the well-vascularized urethral plate and its use for urethral reconstruction has become the mainstay of hypospadias repair (14). Mobilization of the corpus spongiosum /urethral plate and the bulbar urethra decreases the need for urethral plate transection (11,13,15) (LE: 2b).

If the urethral plate is wide, it can be tubularised following the Thiersch-Duplay technique. If the plate is too narrow to be simply tubularised, it is recommended that a midline-relaxing incision of the plate, followed by reconstruction according to the Snodgrass-Orkiszewski technique, is performed in distal hypospadias, as well as in proximal hypospadias (although the complication rate is higher) (16-21).

The onlay technique is preferred in proximal hypospadias and in cases with a plate that is unhealthy or too narrow (11). For distal forms of hypospadias, a range of other techniques is available (e.g. Mathieu, urethral advancement, etc.) (22) (LE: 2b).

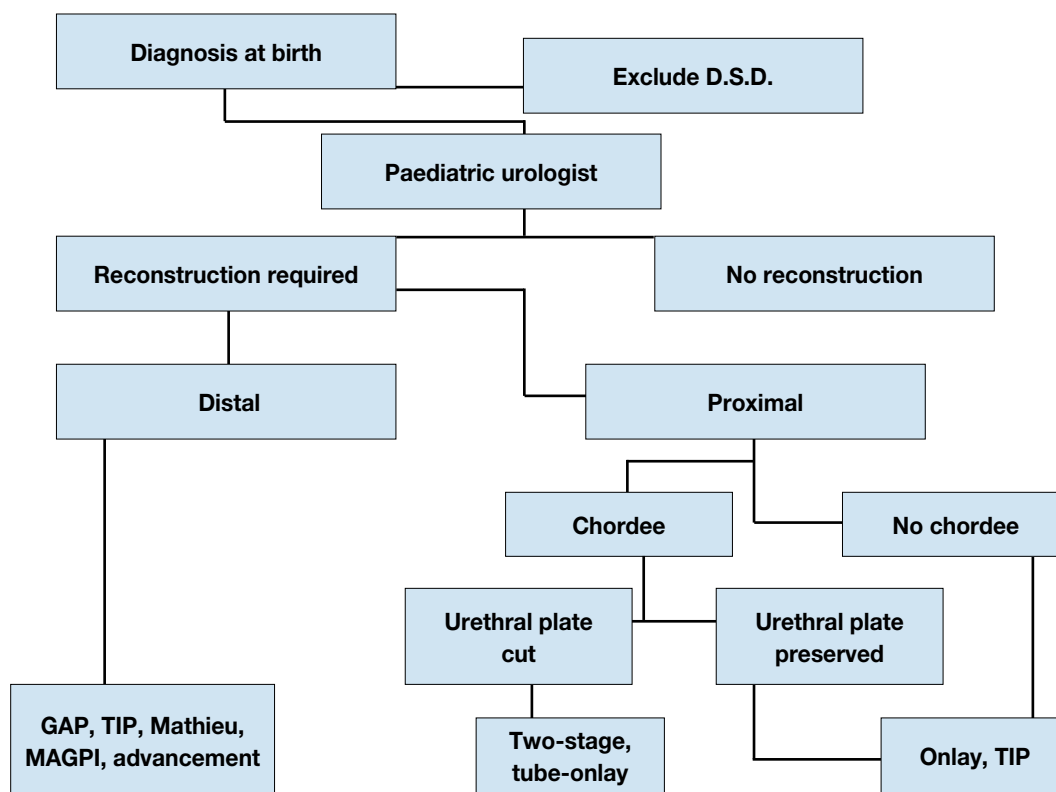
If the continuity of the urethral plate cannot be preserved, a modification of the tubularised flap, such as a tube-onlay or an inlay-onlay flap, is used to prevent urethral stricture (23,24) (LE: 3). In this situation, as well as in severe scrotal or penoscrotal hypospadias, the Koyanagi technique or two-stage procedure may be preferable (25-28).

If preputial or penile skin is not available, or has signs of balanitis xerotica obliterans, a buccal mucosa graft is used in an onlay or two-stage repair (29-31) (LE: 3). The use of inlay skin grafts may allow an increased number of single-stage repairs to be performed (32).

6.3.4 Re-do hypospadias repairs

For re-do hypospadias repairs, no definitive guidelines can be given. All the above-mentioned procedures are used in different ways and are often modified according to the individual needs of the patient.

Figure 1: Algorithm for the management of hypospadias



D.S.D. = disorders of sexual differentiation; GAP = glans approximation procedure; TIP = tubularized incised plate urethroplasty; MAGPI = meatal advancement and glanuloplasty incorporated.

6.3.5 Urethral reconstruction

Following formation of the neo-urethra, the procedure is completed by glansplasty and by reconstruction of the penile skin. If there is a shortage of skin covering, the preputial double-face technique or placement of the suture line into the scrotum may be used. In countries where circumcision is not routinely performed, preputial reconstruction can be considered. However, in the TIP repair, the parents should be advised that the use of a preputial dartos flap reduces the fistula rate (17,21) (LE: 2).

6.3.6 Urine drainage and wound dressing

Urine is drained with a transurethral dripping stent, or with a suprapubic tube. Some surgeons use no drainage after distal hypospadias repair. A circular dressing with slight compression, as well as prophylactic antibiotics during surgery, are established procedures (33) (LE: 4). Postoperative prophylaxis is associated with a lower complication rate (34) (LE: 1b).

A large variation in the duration of stenting and dressing is described. No recommendation can be given due to the low level of evidence.

6.3.7 Outcome

A literature review on distal TIP urethroplasty found significant clinical heterogeneity with some limitations in the comparability of the data; one should expect a predictable outcome with complication rates below 10% (fistula, meatal stenosis, dehiscence, recurrent ventral curvature, and haematoma) (35). A systematic review of the Mathieu and TIP repairs of distal hypospadias found a similar incidence of fistula (3.4-3.6%), and a higher incidence of meatal stenosis in TIP (30% versus 0.6% in Mathieu) after 6-12 months follow-up (36).

The complication rate of TIP and onlay repairs of primary severe hypospadias is similar, 24% and 27%, respectively. It is higher in free graft and in preputial island tube urethroplasty (11). A staged buccal mucosa graft requires redo grafting in 13% of patients, after the second stage more than one third of patients have

complications, most of these with some degree of graft fibrosis (37).

Ventral corporeal grafting for severe penile curvature gives good long-term results and safety for erectile function is reported (LE 2) (38,39).

Long-term follow-up is necessary up to adolescence to detect urethral stricture, voiding dysfunctions and recurrent penile curvature.

Overall, between 7% and 67% of patients operated on for hypospadias end up with an obstructive flow (24.6% in TIP). These children should be followed until adulthood to clarify the clinical significance of this obstructive flow. Spontaneous improvement has been described (40,41) (LE: 2a).

Adolescents and adults, who have undergone hypospadias repair in childhood, have a slightly higher rate of dissatisfaction with penile size, especially proximal hypospadias patients, but their sexual behaviour is not different from that in control subjects (42,43) (LE: 2a/2b). The later corrective surgery is completed, the more likely the patients may become insecure with regard to gender-role behaviour (44,45) (LE: 2b).

6.4 Conclusions and recommendations

Conclusions	LE
The age at surgery for primary hypospadias repair is usually 6-18 (24) months.	4
The therapeutic objectives are to correct the penile curvature, to form a neo-urethra of an adequate size, to bring the neomeatus to the tip of the glans, if possible, and to achieve an overall acceptable cosmetic appearance.	4
After hypospadias repair, sexual functions are usually well preserved.	2

Recommendations	GR
At birth, isolated hypospadias has to be differentiated from disorders of sex development which are mostly associated with cryptorchidism or micropenis.	A
Differentiation between functionally necessary (functional indications) and aesthetically feasible operative procedures (psychological, cosmetic indications) is important for therapeutic decision-making. As all surgical procedures carry the risk of complications and thorough pre-operative counselling of the parents is crucial.	
Original and modified tubularised incised plate urethroplasty has become the most popular type of surgery for distal hypospadias; the onlay urethroplasty or two-stage procedures are used in more severe hypospadias. For the algorithm see Fig. 1.	B
After hypospadias repairs, long-term follow-up is necessary, up to adolescence, to detect urethral stricture, voiding dysfunction and recurrent penile curvature.	A

6.5 References

- Morera A, Valmalle A, Asensio M, et al. A study of risk factors for hypospadias in the Rhône-Alpes region (France). *J Ped Urol* 2006 Jun;2(3):169-77.
<http://www.ncbi.nlm.nih.gov/pubmed/18947603>
- Fredell L, Kockum I, Hansson E, et al. Heredity of hypospadias and the significance of low birth weight. *J Urol* 2002 Mar;167(3):1423-7.
<http://www.ncbi.nlm.nih.gov/pubmed/11832761>
- Belman AB. Hypospadias and chordee. In: Belman AB, King LR, Kramer SA, eds. *Clinical Pediatric Urology*. 4th edn. London, Martin Dunitz, 2002, pp. 1061-1092.
- Mouriquand OD, Mure PY. Hypospadias. In: Gearhart J, Rink R, Mouriquand PDE, eds. *Pediatric Urology*, Philadelphia, WB Saunders, 2001, pp. 713-728.
- Lund L, Engebjerg MC, Pedersen L, et al. Prevalence of hypospadias in Danish boys: a longitudinal study, 1977-2005. *Eur Urol* 2009 May;55(5):1022-6.
<http://www.ncbi.nlm.nih.gov/pubmed/19155122>
- Weidner IS, Møller H, Jensen TK, et al. Risk factors for cryptorchidism and hypospadias. *J Urol* 1999 May;161(5):1606-9.
<http://www.ncbi.nlm.nih.gov/pubmed/10210427>
- Fisch H, Hyun G, Hensle TW. Rising hypospadias rates: disproving a myth. *J Pediatr Urol* 2010 Feb;6(1):37-9.
<http://www.ncbi.nlm.nih.gov/pubmed/20022563>
- Nørgaard M, Wogelius P, Pedersen L, et al. Maternal use of oral contraceptives during early pregnancy and risk of hypospadias in male offspring. *Urology* 2009 Sept;74(3):583-7.
<http://www.ncbi.nlm.nih.gov/pubmed/19592074>

9. Gorduzi DB, Gay CL, de Mattos E, et al. Does androgen stimulation prior to hypospadias surgery increase the rate of healing complications? - A preliminary report. *J Pediatr Urol* 2011 Apr;7(2):158-61. <http://www.ncbi.nlm.nih.gov/pubmed/20570565>
10. Perlmutter AE, Morabito R, Tarry WF. Impact of patient age on distal hypospadias repair: a surgical perspective. *Urology* 2006 Sep;68(3):648-51. <http://www.ncbi.nlm.nih.gov/pubmed/16979730>
11. Castagnetti M, El-Ghoneimi A. Surgical management of primary severe hypospadias in children: systematic 20-year review. *J Urol* 2010 Oct;184(4):1469-74. <http://www.ncbi.nlm.nih.gov/pubmed/20727541>
12. Baskin LS, Duckett JW, Ueoka K, et al. Changing concepts of hypospadias curvature lead to more onlay island flap procedures. *J Urol* 1994;151(1):191-6. <http://www.ncbi.nlm.nih.gov/pubmed/8254812>
13. Snodgrass W, Prieto J. Straightening ventral curvature while preserving the urethral plate in proximal hypospadias repair. *J Urol* 2009 Oct;182(4 Suppl):1720-5. <http://www.ncbi.nlm.nih.gov/pubmed/19692004>
14. Hollowell JG, Keating MA, Snyder HM 3rd, et al. Preservation of the urethral plate in hypospadias repair: extended applications and further experience with the onlay island flap urethroplasty. *J Urol* 1990 Jan;143(1): 98-100; discussion 100-1. <http://www.ncbi.nlm.nih.gov/pubmed/2294275>
15. Mollard P, Castagnola C. Hypospadias: the release of chordee without dividing the urethral plate and onlay island flap (92 cases). *J Urol* 1994 Oct;152(4):1238-40. <http://www.ncbi.nlm.nih.gov/pubmed/8072112>
16. Snodgrass WT, Yucel S. Tubularized incised plate for mid shaft and proximal hypospadias repair. *J Urol* 2007 Feb;177(2):698-702. <http://www.ncbi.nlm.nih.gov/pubmed/17222659>
17. El-Sherbiny MT, Hafez AT, Dawaba MS, et al. Comprehensive analysis of tubularized incised-plate urethroplasty in primary and re-operative hypospadias. *BJU Int* 2004 May;93(7):1057-61. <http://www.ncbi.nlm.nih.gov/pubmed/15142164>
18. Orkiszewski M, Leszniewski J. Morphology and urodynamics after longitudinal urethral plate incision in proximal hypospadias repairs: long-term results. *Eur J Pediatr Surg* 2004 Feb;14(1):35-8. <http://www.ncbi.nlm.nih.gov/pubmed/15024677>
19. Riccabona M, Oswald J, Koen M, et al. Comprehensive analysis of six years experience in tubularized incised plate urethroplasty and its extended application in primary and secondary hypospadias repair. *Eur Urol* 2003 Dec;44(6):714-9. <http://www.ncbi.nlm.nih.gov/pubmed/14644125>
20. Snodgrass W, Bush N, Cost N. Tubularized incised plate hypospadias repair for distal hypospadias. *J Pediatr Urol* 2010 Aug;6(4):408-13. <http://www.ncbi.nlm.nih.gov/pubmed/19837000>
21. El Kassaby AW, Al-Kandari AM, Elzayat T, et al. Modified tubularized incised plate urethroplasty for hypospadias repair: a long term results of 764 patients. *Urology* 2008 Apr;71(4): 611-5. <http://www.ncbi.nlm.nih.gov/pubmed/18295308>
22. Meyer-Junghänel L, Petersen C, Mildenerberger H. Experience with repair of 120 hypospadias using Mathieu's procedure. *Eur J Pediatr Surg* 1995 Dec;5(6):355-7. <http://www.ncbi.nlm.nih.gov/pubmed/8773227>
23. Kocvara R, Dvoráček J. Inlay-onlay flap urethroplasty for hypospadias and urethral stricture repair. *J Urol* 1997 Dec;158(6):2142-5. <http://www.ncbi.nlm.nih.gov/pubmed/9366331>
24. Perovic S, Vukadinovic V. Onlay island flap urethroplasty for severe hypospadias: a variant of the technique. *J Urol* 1994 Mar;151(3):711-4. <http://www.ncbi.nlm.nih.gov/pubmed/8308994>
25. Bracka A. Hypospadias repair: the two-stage alternative. *Br J Urol* 1995 Dec;76 (Suppl 3):31-41. <http://www.ncbi.nlm.nih.gov/pubmed/8535768>
26. Hayashi Y, Kojima Y, Mizuno K, et al. Neo-modified Koyanagi technique for the single-stage repair of proximal hypospadias. *J Pediatr Urol* 2007 Jun;3(3):239-42. <http://www.ncbi.nlm.nih.gov/pubmed/18947743>

27. Lam PN, Greenfield SP, Williot P. 2-stage repair in infancy for severe hypospadias with chordee: long-term results after puberty. *J Urol* 2005 Oct;174(4 Pt 2):1567-72; discussion 1572.
<http://www.ncbi.nlm.nih.gov/pubmed/16148653>
28. Moursy EE. Outcome of proximal hypospadias repair using three different techniques. *J Pediatr Urol* 2010 Feb; 6(1): 45-53.
<http://www.ncbi.nlm.nih.gov/pubmed/19515615>
29. Ahmed S, Gough DC. Buccal mucosal graft for secondary hypospadias repair and urethral replacement. *Br J Urol* 1997 Aug;80(2):328-30.
<http://www.ncbi.nlm.nih.gov/pubmed/9284210>
30. Amukele SA, Stock JA, Hanna MK. Management and outcome of complex hypospadias repairs. *J Urol* 2005 Oct;174(4 Pt 2):1540-2; discussion 1542-3.
<http://www.ncbi.nlm.nih.gov/pubmed/16148648>
31. Mokhless IA, Kader MA, Fahmy N, et al. The multistage use of buccal mucosa grafts for complex hypospadias: histological changes. *J Urol* 2007 Apr;177(4):1496-9; discussion 1499-500.
<http://www.ncbi.nlm.nih.gov/pubmed/17382762>
32. Schwentner C, Gozzi C, Lunacek A, et al. Interim outcome of the single stage dorsal inlay skin graft for complex hypospadias reoperations. *J Urol* 2006 May;175(5):1872-1876; discussion 1876-7.
<http://www.ncbi.nlm.nih.gov/pubmed/16600785>
33. Hsieh MH, Wildenfelds P, Gonzales ET Jr. Surgical antibiotic practices among pediatric urologists in the United States. *J Pediatr Urol* 2011 Apr; 7(2): 192-7.
<http://www.ncbi.nlm.nih.gov/pubmed/20537590>
34. Meir DB, Livne PM. Is prophylactic antimicrobial treatment necessary after hypospadias repair? *J Urol* 2004 Jun; 171(6 Pt2):2621-2.
<http://www.ncbi.nlm.nih.gov/pubmed/15118434>
35. Braga LHP, Lorenzo AJ, Pippi Salle JL. Tubularized incised plate urethroplasty for distal hypospadias: A literature review. *Indian J Urol* 2008 Apr; 24(2):219-25.
<http://www.ncbi.nlm.nih.gov/pubmed/19468401>
36. Wilkinson DJ, Farrelly P, Kenny SE. Outcomes in distal hypospadias: a systematic review of the Mathieu and tubularized incised plate repairs. *J Pediatr Urol* 2012 Jun; 8(3): 307-12.
<http://www.ncbi.nlm.nih.gov/pubmed/21159560>
37. Leslie B, Lorenzo AJ, Figueroa V, et al. Critical outcome analysis of staged buccal mucosa graft urethroplasty for prior failed hypospadias repair in children. *J Urol* 2011 Mar; 185(3):1077-82.
<http://www.ncbi.nlm.nih.gov/pubmed/21256520>
38. Braga LHP, Lorenzo AJ, DJ Bagli, et al. Ventral lengthening versus dorsal plication for severe ventral curvature in children with proximal hypospadias. *J Urol* 2008 Oct; 180(4 Suppl):1743-8.
<http://www.ncbi.nlm.nih.gov/pubmed/18721961>
39. Badawy H, Morsi H. Long-term followup of dermal grafts for repair of severe penile curvature *J Urol* 2008 Oct; 180(4 Suppl):1842-5.
<http://www.ncbi.nlm.nih.gov/pubmed/18721971>
40. Andersson M, Doroszkiewicz M, Arfwidsson CH, et al. Hypospadias repair with tubularized incised plate: Does the obstructive flow pattern resolve spontaneously? *J Pediatr Urol* 2011 Aug;7(4):441-5.
<http://www.ncbi.nlm.nih.gov/pubmed/20630805>
41. Gonzáles R, Ludwikowski BM. Importance of urinary flow studies after hypospadias repair: a systematic review. *Int J Urol* 2011 Nov;18(11): 757-61.
<http://www.ncbi.nlm.nih.gov/pubmed/21883491>
42. Moriya K, Kakizaki H, Tanaka H, et al. Long-term cosmetic and sexual outcome of hypospadias surgery: norm related study in adolescence. *J Urol* 2006 Oct;176(4 Pt 2):1889-92; discussion 1892-3.
<http://www.ncbi.nlm.nih.gov/pubmed/16945681>
43. Rynja SP, de Jong T, Bosch, et al. Functional, cosmetic and psychosexual results in adult men who underwent hypospadias correction in childhood. *J Pediatr Urol* 2011 Oct;7(5):504-15.
<http://www.ncbi.nlm.nih.gov/pubmed/21429804>
44. Schönbacher V, Landolt M, Gobet R, et al. Psychosexual development of children and adolescents with hypospadias. *J Sex Med* 2008 Jun;5(6):1365-73.
<http://www.ncbi.nlm.nih.gov/pubmed/18194175>
45. Jones B, O'Brien M, Chase J, et al. Early hypospadias surgery may lead to a better long-term psychosexual outcome. *J Urol* 2009 Oct;182(4 Suppl):1744-9.
<http://www.ncbi.nlm.nih.gov/pubmed/19692053>

7. CONGENITAL PENILE CURVATURE

7.1 Background

Penile curvature may be ventral, dorsal or lateral. Most of ventral curvatures are associated with hypospadias due to chordee or ventral dysplasia of cavernous bodies (1). Similarly, the dorsal curvature is mostly associated with epispadias (2). Isolated penile curvature is not frequent with an incidence of 0.6 % (3) (LE: 2). The curvature is caused by asymmetry of the cavernous bodies (1,4).

Curvature over 30 degrees is considered clinically significant; curvature over 60 degrees may interfere with satisfactory sexual intercourse in adulthood (5) (LE: 4).

7.2 Diagnosis

Diagnosis is made during hypospadias or epispadias repair using an artificial erection (6). The isolated anomaly is usually not recognised until later in childhood because the appearance of the penis is normal. The curvature is only observed during erections.

7.3 Treatment

The treatment is surgical. An artificial erection is used to determine the degree of curvature and to check the symmetry after the repair (6).

In hypospadias, chordee related to the tethering of the ventral skin and to the spongiosal pillars is first released. Only in a few cases the penile curvature is caused by a short urethral plate, which should be cut. To repair the corporeal angulation in the isolated curvature or curvature associated with hypospadias, different techniques of plication of corpora cavernosa (orthoplasty) are used (5).

In epispadias, a combination of complete release of the urethral body from the corpora and a different kind of corporoplasty with or without corporotomy is usually necessary to achieve a straight penis (7,8).

7.4 References

1. Baskin LS, Duckett JW, Lue TF. Penile curvature. *Urology* 1996 Sep;48(3):347-56. [no abstract available]
<http://www.ncbi.nlm.nih.gov/pubmed/8804484>
2. Baka-Jakubiak M. Combined bladder neck, urethral and penile reconstruction in boys with the exstrophy-epispadias complex. *BJU Int* 2000 Sep;86(4):513-8.
<http://www.ncbi.nlm.nih.gov/pubmed/10971283>
3. Yachia D, Beyar M, Aridogan IA, et al. The incidence of congenital penile curvature. *J Urol* 1993 Nov;150(5 Pt 1):1478-9.
<http://www.ncbi.nlm.nih.gov/pubmed/8411431>
4. Cendron M. Disorders of the penis and scrotum. In: Gearhart JP, Rink RC, Mouriquand PDE, eds. *Pediatric urology*. Philadelphia: WB Saunders, Philadelphia, 2001, pp. 729-37
5. Ebbehoj J, Metz P. Congenital penile angulation. *Br J Urol* 1987 Sep;60(3):264-6.
<http://www.ncbi.nlm.nih.gov/pubmed/3676675>
6. Gittes RF, McLaughlin AP 3rd. Injection technique to induce penile erection. *Urology* 1974 Oct;4(4):473-4. [no abstract available]
<http://www.ncbi.nlm.nih.gov/pubmed/4418594>
7. Woodhouse CRJ. The genitalia in exstrophy and epispadias. In: Gearhart JP, Rink RC, Mouriquand PDE, eds. *Pediatric urology*. Philadelphia: WB Saunders 2001, pp. 557-64.
8. Zaontz MR, Steckler RE, Shortliffe LM, et al. Multicenter experience with the Mitchell technique for epispadias repair. *J Urol* 1998 Jul;160(1):172-6.
<http://www.ncbi.nlm.nih.gov/pubmed/9628644>

8. VARICOCELE IN CHILDREN AND ADOLESCENTS

8.1 Background

Varicocele is defined as an abnormal dilatation of testicular veins in the pampiniformis plexus caused by venous reflux. It is unusual in boys under 10 years of age and becomes more frequent at the beginning of puberty. It is found in 14-20% of adolescents, with a similar incidence during adulthood. It appears mostly on the left side (78-93% of cases). Right-sided varicoceles are least common; they are usually noted only when

bilateral varicoceles are present and seldom occur as an isolated finding (1-3).

Varicocele develops during accelerated body growth by a mechanism that is not clearly understood. Varicocele can induce apoptotic pathways because of heat stress, androgen deprivation and accumulation of toxic materials. Severe damage is found in 20% of adolescents affected, with abnormal findings in 46% of affected adolescents. Histological findings are similar in children or adolescents and in infertile men. In 70% of patients with grade II and III varicocele, left testicular volume loss was found. However, studies correlating a hypoplastic testicle with poor sperm quality reported controversial results (4,5). A recent study has shown that in late adolescence the contralateral right testis is smaller in boys with varicocele than in boys that are not affected, and comparison of testicle sizes may not reflect long-term testicular well-being (6) (LE: 2).

Several authors reported on reversal of testicular growth after varicocelectomy in adolescents (7,8) (LE: 2). However, this may partly be attributable to testicular oedema associated with the division of lymphatic vessels (9) (LE: 2).

In about 20% of adolescents with varicocele, fertility problems will arise (10). The adverse influence of varicocele increases with time. Improvement in sperm parameters has been demonstrated after adolescent varicocelectomy (4,5,11) (LE: 1).

8.2 Diagnosis

Varicocele is mostly asymptomatic, rarely causing pain at this age. It may be noticed by the patient or parents, or discovered by the paediatrician at a routine visit. The diagnosis depends upon the clinical finding of a collection of dilated and tortuous veins in the upright posture; the veins are more pronounced when the patient performs the Valsalva manoeuvre.

Varicocele is classified into 3 grades:

Grade I - Valsalva positive (palpable at Valsalva manoeuvre only);

Grade II - palpable (palpable without the Valsalva manoeuvre);

Grade III - visible (visible at distance) (12).

The size of both testicles should be evaluated during palpation to detect a smaller testis.

Venous reflux into the plexus pampiniformis is diagnosed using Doppler colour flow mapping in the supine and upright position (13). Venous reflux detected on ultrasound only is classified as subclinical varicocele. The ultrasound examination includes assessment of the testicular volume to discriminate testicular hypoplasia. In adolescents, a testis that is smaller by more than 2 mL or 20% compared to the other testis is considered to be hypoplastic (14) (LE: 2).

In order to assess testicular injury in adolescents with varicocele, supranormal follicle-stimulating hormone (FSH) and luteinizing hormone (LH) responses to the luteinizing hormone-releasing hormone (LHRH) stimulation test are considered reliable, because histopathological testicular changes have been found in these patients (11,15).

8.3 Therapy

Surgical intervention is based on ligation or occlusion of the internal spermatic veins. Ligation is performed at different levels:

- inguinal (or subinguinal) microsurgical ligation;
- suprainguinal ligation, using open or laparoscopic techniques (16-19).

The advantage of the former is the lower invasiveness of the procedure, while the advantage of the latter is a considerably lower number of veins to be ligated and safety of the incidental division of the internal spermatic artery at the suprainguinal level.

For surgical ligation, some form of optical magnification (microscopic or laparoscopic magnification) should be used because the internal spermatic artery is 0.5 mm in diameter at the level of the internal ring (16-18,20). The recurrence rate is usually less than 10%.

Lymphatic-sparing varicocelectomy is preferred to prevent hydrocele formation and testicular hypertrophy development and to achieve a better testicular function according to the LHRH stimulation test (9,16,17,20) (LE: 2). The methods of choice are subinguinal or inguinal microsurgical (microscopic) repairs, or suprainguinal open or laparoscopic lymphatic-sparing repairs (16,18,21,22). Angiographic occlusion of the internal spermatic veins also meets these requirements. It is based on retrograde or antegrade sclerotisation of the internal spermatic veins (23-25). However, although this method is less invasive and may not require general anaesthesia, it is associated with radiation burden, which is less controllable in the antegrade technique. Available data on failure rates combine anatomical inaccessibility and recurrence (1,24-25) (LE: 2).

There is no evidence that treatment of varicocele at paediatric age will offer a better andrological outcome than an operation performed later. The recommended indication criteria for varicocelectomy in children and adolescents are (1):

- varicocele associated with a small testis;

- additional testicular condition affecting fertility;
- bilateral palpable varicocele;
- pathological sperm quality (in older adolescents);
- symptomatic varicocele.

Testicular (left + right) volume loss in comparison with normal testes is a promising indication criterion, once the normal values are available (6).

Repair of a large varicocele, physically or psychologically causing discomfort, may be also considered. Other varicoceles should be followed-up until a reliable sperm analysis can be performed (LE: 4).

8.4 Conclusions and recommendations

Varicocele becomes more frequent at the beginning of puberty and is found in 14-20% of adolescents. Fertility problems are expected in 20% of them.

Varicocele is examined in the standing position and classified into 3 grades. Venous reflux is diagnosed using Doppler colour flow mapping in the supine and upright position. In up to 70% of patients with grade II and III varicocele, left testicular volume loss was found; in late adolescence the contralateral right testis may become smaller as well.

Recommendations	LE	GR
Surgery is recommended for: - varicocele associated with a small testis - additional testicular condition affecting fertility - pathological sperm quality (in older adolescents); - bilateral palpable varicocele; - symptomatic varicocele.	2	B
For surgical ligation, some form of optical magnification (microscopic or laparoscopic magnification) should be used.	2	B
Lymphatic-sparing varicocelectomy is preferred to prevent hydrocele formation and testicular hypertrophy.	2	A

8.5 References

1. Kogan SJ. The pediatric varicocele. In: Gearhart JP, Rink RC, Mouriquand PDE, eds. *Pediatric urology*. Philadelphia: WB Saunders, 2001, pp. 763-773.
2. Oster J. Varicocele in children and adolescents. An investigation of the incidence among Danish school children. *Scand J Urol Nephrol*;1971;5(1):27-32. [no abstract available]
<http://www.ncbi.nlm.nih.gov/pubmed/5093090>
3. Akbay E, Cayan S, Doruk E, et al. The prevalence of varicocele and varicocele-related testicular atrophy in Turkish children and adolescents. *BJU Int* 2000 Sep;86(4):490-3.
<http://www.ncbi.nlm.nih.gov/pubmed/10971279>
4. Laven JS, Haans LC, Mali WP, et al. Effects of varicocele treatment in adolescents: a randomized study. *Fertil Steril* 1992 Oct;58(4):756-62.
<http://www.ncbi.nlm.nih.gov/pubmed/1426322>
5. Pinto KJ, Kroovand RL, Jarow JP. Varicocele related testicular atrophy and its predictive effect upon fertility. *J Urol* 1994 Aug;152(2 Pt 2):788-90.
<http://www.ncbi.nlm.nih.gov/pubmed/80220155>
6. Chen JJ, Ahn HJ, Junewick J, et al. Is the comparison of a left varicocele testis to its contralateral normal testis sufficient in determining its well-being? *Urology* 2011 Nov;78(5):1167-72.
<http://www.ncbi.nlm.nih.gov/pubmed/21782220>
7. Kass EJ, Belman AB. Reversal of testicular growth failure by varicocele ligation. *J Urol* 1987 Mar;137(3):475-6.
<http://www.ncbi.nlm.nih.gov/pubmed/3820376>
8. Paduch DA, Niedzielski J. Repair versus observation in adolescent varicocele: a prospective study. *J Urol* 1997 Sep;158(3 Pt 2):1128-32.
<http://www.ncbi.nlm.nih.gov/pubmed/9258155>
9. Kocvara R, Dolezal J, Hampl R, et al. Division of lymphatic vessels at varicocelectomy leads to testicular oedema and decline in testicular function according to the LH-RH analogue stimulation test. *Eur Urol* 2003 Apr;43(4):430-5.
<http://www.ncbi.nlm.nih.gov/pubmed/12667726>

10. World Health Organization. The influence of varicocele on parameters of fertility in a large group of men presenting to infertility clinics. *Fertil Steril* 1992 Jun;57(6):1289-93.
<http://www.ncbi.nlm.nih.gov/pubmed/1601152>
11. Okuyama A, Nakamura M, Namiki M, et al. Surgical repair of varicocele at puberty: preventive treatment for fertility improvement. *J Urol* 1988 Mar;139(3):562-4.
<http://www.ncbi.nlm.nih.gov/pubmed/3343743>
12. Dubin L, Amelar RD. Varicocele size and results of varicocelectomy in selected subfertile men with a varicocele. *Fertil Steril* 1970 Aug;21(8):606-9. [no abstract available]
<http://www.ncbi.nlm.nih.gov/pubmed/5433164>
13. Tasci AI, Resim S, Caskurlu T, et al. Color Doppler ultrasonography and spectral analysis of venous flow in diagnosis of varicocele. *Eur Urol* 2001 Mar;39(3):316-21.
<http://www.ncbi.nlm.nih.gov/pubmed/11275726>
14. Diamond DA, Zurakowski D, Bauer SB, et al. Relationship of varicocele grade and testicular hypotrophy to semen parameters in adolescents. *J Urol* 2007 Oct;178(4 Pt 2):1584-8.
<http://www.ncbi.nlm.nih.gov/pubmed/17707046>
15. Aragona F, Ragazzi R, Pozzan GB, et al. Correlation of testicular volume, histology and LHRH test in adolescents with idiopathic varicocele. *Eur Urol* 1994;26(1):61-6.
<http://www.ncbi.nlm.nih.gov/pubmed/7925532%2C7925635>
16. Goldstein M, Gilbert BR, Dicker AP, et al. Microsurgical inguinal varicocelectomy with delivery of the testis: an artery and lymphatic sparing technique. *J Urol* 1992 Dec;148(6):1808-11.
<http://www.ncbi.nlm.nih.gov/pubmed/1433614>
17. Hopps CV, Lemer ML, Schlegel PN, et al. Intraoperative varicocele anatomy: a microscopic study of the inguinal versus subinguinal approach. *J Urol* 2003 Dec;170(6 Pt 1):2366-70.
<http://www.ncbi.nlm.nih.gov/pubmed/14634418>
18. Kocvara R, Dvoracek J, Sedlacek J, et al. Lymphatic-sparing laparoscopic varicocelectomy: a microsurgical repair. *J Urol* 2005 May;173(5):1751-4.
<http://www.ncbi.nlm.nih.gov/pubmed/15821575>
19. Riccabona M, Oswald J, Koen M, et al. Optimizing the operative treatment of boys with varicocele: sequential comparison of 4 techniques. *J Urol* 2003 Feb;169(2):666-8.
<http://www.ncbi.nlm.nih.gov/pubmed/12544340>
20. Marmar J, Benoff S. New scientific information related to varicoceles. (Editorial). *J Urol* 2003 Dec;170(6 Pt 1):2371-3.
<http://www.ncbi.nlm.nih.gov/pubmed/14634419>
21. Mirilas P, Mentessidou A. Microsurgical subinguinal varicocelectomy in children, adolescents, and adults: surgical anatomy and anatomically justified technique. *J Androl* 2012 May-Jun; 33(3):338-49.
<http://www.ncbi.nlm.nih.gov/pubmed/21835913>
22. Minevich E, Wacksman J, Lewis AG, et al. Inguinal microsurgical varicocelectomy in the adolescent: technique and preliminary results. *J Urol* 1998 Mar; 159(3):1022-4.
<http://www.ncbi.nlm.nih.gov/pubmed/9474223>
23. Mazzoni G, Minucci S, Gentile V. Recurrent varicocele: role of antegrade sclerotherapy as first choice treatment. *Eur Urol* 2002 Jun;41(6):614-8; discussion 618.
<http://www.ncbi.nlm.nih.gov/pubmed/12074778>
24. Thon WF, Gall H, Danz B, et al. Percutaneous sclerotherapy of idiopathic varicocele in childhood: a preliminary report. *J Urol* 1989 Apr;141(4):913-5:
<http://www.ncbi.nlm.nih.gov/pubmed/2926889>
25. Fayad F, Sellier N, Chabaud M, et al. Percutaneous retrograde endovascular occlusion for pediatric varicocele. *J Pediatr Surg* 2011 Mar; 46(3):525-9.
<http://www.ncbi.nlm.nih.gov/pubmed/21376204>

9. URINARY TRACT INFECTIONS IN CHILDREN

9.1 Introduction

Urinary tract infection (UTI) represents the most common bacterial infection in children < 2 years of age. In neonates, the symptoms differ in many aspects from those in UTIs in infants and children. The prevalence is higher; there is a male predominance; infections not caused by *Escherichia coli* are more frequent; and there is a higher risk of urosepsis (1-4).

The incidence of UTIs varies depending on age and sex. One meta-analysis showed that, in the first

3 months of life, UTIs were present in 7.5% of girls, 2.4% (CI: 1.4-3.5) of circumcised boys, and 20.1% (CI: 16.8-23.4) of uncircumcised boys, who presented with fever (2). In the first year of life, UTIs are more common in boys (3.7%) than in girls (2%). Later, the incidence changes and ~3% of pre-pubertal girls and 1% of pre-pubertal boys are diagnosed with UTIs (2-7).

E. coli is found in ~75% of UTIs and is more frequent in community-acquired than nosocomial. In the latter, *Klebsiella pneumoniae*, *Enterobacter* spp., *Enterococcus* spp., *Pseudomonas* spp. and *Candida* spp. are more frequent than in community-acquired UTIs. Neonatal UTI is frequently complicated by bacteraemia. In a retrospective study, 12.4% of blood cultures from neonates admitted for UTI were positive for bacteraemia in around 12% (8), however, it is less frequent in community-acquired than in nosocomial UTI (8,9).

9.2 Classification

There are five widely used classification systems according to the site, episode, severity, symptoms and complicating factors. For acute treatment, site and severity are most important.

9.2.1 Classification according to site

Lower urinary tract (cystitis) is an inflammatory condition of the urinary bladder with general signs and symptoms including dysuria, frequency, urgency, malodorous urine, enuresis, haematuria, and suprapubic pain.

Upper urinary tract (pyelonephritis) is a diffuse pyogenic infection of the renal pelvis and parenchyma. The onset of pyelonephritis is generally abrupt. Clinical signs and symptoms include fever ($\geq 38^\circ\text{C}$), chills, costovertebral angle or flank pain, and tenderness. Older children may report cystitis symptoms along with fever/flank pain. Infants and children may have non-specific signs such as poor appetite, failure to thrive, lethargy, irritability, vomiting or diarrhoea.

9.2.2 Classification according to episode (10)

First infection: the first UTI may be a sign of anatomical anomalies that may predispose to complications of UTI and potential renal damage (11). Anatomical evaluation is recommended (see below). Recurrent infection can be divided into unresolved and persistent infection.

In unresolved infection, initial therapy is inadequate for elimination of bacterial growth in the urinary tract [inadequate therapy, inadequate antimicrobial urinary concentration (poor renal concentration/gastrointestinal malabsorption), and infection involving multiple organisms with differing antimicrobial susceptibilities].

Persistent infection is caused by re-emergence of bacteria from a site within the urinary tract coming from a nidus for persistent infection that cannot be eradicated (e.g. infected stones, non-functioning or poorly functioning kidneys/renal segments, ureteral stumps after nephrectomy, necrotic papillae in papillary necrosis, urachal cyst, urethral diverticulum, periurethral gland, vesicointestinal, rectourethral or vesicovaginal fistulas). The same pathogen is identified in recurrent infections, but episodes of sterile urine may occur during and shortly following antimicrobial treatment.

Reinfection: each episode can be caused by a variety of new infecting organisms, in contrast to bacterial persistence in which the same infecting organism is always isolated. However, the most common general pathogenic species is *E. coli*, which occurs in many different serotypes. Therefore, recurrent *E. coli* UTI does not equate to infection with the same organism.

9.2.3 Classification according to severity

In simple UTI, children may have only mild pyrexia; are able to take fluids and oral medication; are only slightly or not dehydrated; and have a good expected level of compliance. When a low level of compliance is expected, such children should be managed as those with severe UTI.

In severe UTI, infection is related to the presence of fever of $> 39^\circ\text{C}$, the feeling of being ill, persistent vomiting, and moderate or severe dehydration.

9.2.4 Classification according to symptoms

Asymptomatic bacteriuria indicates attenuation of uropathogenic bacteria by the host, or colonisation of the bladder by non-virulent bacteria that are incapable of activating a symptomatic response.

In symptomatic bacteriuria, symptoms associated with UTI include irritative voiding symptoms, suprapubic pain (cystitis), fever and malaise (pyelonephritis). Cystitis may represent early recognition of an infection destined to become pyelonephritis, or bacterial growth controlled by a balance of virulence and host response.

9.2.5 **Classification according to complicating factors (12)**

In uncomplicated UTI, infection occurs in a patient with a morphologically and functionally normal urinary tract. This category includes mostly isolated or recurrent bacterial cystitis and is usually associated with a narrow spectrum of infecting pathogens that are easily eradicated by a short course of oral antimicrobial agents. Patients can be managed on an outpatient basis, with an emphasis on documenting resolution of their bacteriuria, followed by elective evaluation for potential anatomical or functional abnormalities of the urinary tract.

In complicated UTI, all neonates, most patients with clinical evidence of pyelonephritis, and all children with known mechanical or functional obstructions of the urinary tract are considered to have complicated UTI. Mechanical obstruction is commonly due to the presence of posterior urethral valves, strictures or stones, independent from their location. Functional obstruction often results from lower urinary tract dysfunction of either neurogenic or non-neurogenic origin and dilating vesicoureteral reflux. Patients with complicated UTI require hospitalisation and parenteral antibiotics. Prompt anatomical evaluation of the urinary tract is critical to exclude the presence of significant abnormalities (13). If mechanical or functional abnormalities are present, adequate drainage of the infected urinary tract is necessary.

9.3 **Diagnosis**

9.3.1 **Medical history**

Medical history includes the question of a primary (first) or secondary (recurring) infection; possible malformations of the urinary tract (e.g. pre- or postnatal ultrasound screening); family history; and whether there is constipation or presence of lower urinary tract symptoms.

9.3.2 **Clinical signs and symptoms**

Neonates with pyelonephritis or urosepsis can present with non-specific symptoms (failure to thrive, jaundice, hyperexcitability and without any fever). UTI is the cause of fever in 4.1-7.5% of children who present to a paediatric clinic (14,15). Septic shock is unusual, even with very high fever. Signs of a UTI may be vague and unspecific in small children, but later on, when they are > 2 years old, frequent voiding, dysuria and suprapubic, abdominal or lumbar pain can be detected.

9.3.3 **Physical examination**

Physical examination includes a general examination of the throat, lymph nodes, abdomen (constipation, palpable and painful kidney, or palpable bladder), flank, the back (stigmata of spina bifida or sacral agenesis), genitalia (phimosis, labial adhesion, vulvitis, epididymo-orchitis), and temperature.

9.4 **Urine sampling, analysis and culture**

Urine sampling should be performed before any antimicrobial agent is administered. The technique for obtaining urine for urinalysis as well as culture affects the rate of contamination, which influences interpretation of the results. Especially in early infancy it can be challenging and depends on the mode of urine sampling (16,17).

9.4.1 **Urine sampling**

Urine must be collected under defined conditions and investigated as soon as possible to confirm or exclude UTI, especially in children with fever.

In neonates, infants and non-toilet-trained children, there are four main methods with varying contamination rates and invasiveness to obtain urine in this age group:

(1) Plastic bag attached to the cleaned genitalia.

This technique is most often used in daily practice. It is helpful when the culture result is negative. Also, if the dipstick is negative for both leukocyte esterase and nitrite, or microscopic analysis is negative for both pyuria and bacteriuria, UTI can be excluded without the need for confirmatory culture (18). However, if the genitalia are not cleaned and culture is delayed, a high incidence of false-positive results (85-99%) can be found (19,20).

(2) Clean-catch urine collection.

The infant is placed in the lap of a parent or member of the nursing staff, who holds a sterile foil bowl underneath the infant's genitalia. The infant is offered oral fluids and urine collection is awaited (21). This is time consuming and requires proper instruction of the parents. However, there seems to be a good correlation between the results of urine culture obtained by this method and suprapubic aspiration (SPA), with a false-positive rate of 5% and false-negative rate of 12% (21,22).

(3) Bladder catheterisation.

Especially in boys, transurethral catheterisation is traumatic and bears the risk of nosocomial infection, but in experienced hands, this technique may be an alternative to SPA (23). In a prospective study using bladder catheterisation in febrile children aged ≤ 36 months, contamination was defined by multiple pathogens, non-pathogens, or colony counts $< 10,000$ cfu/mL. Ten percent of the children had true UTI and 14% of the cultures were contaminated. Univariate analysis of potential predictors identified age < 6 months, difficult catheterisation, and uncircumcised boys (24).

(4) Suprapubic bladder aspiration.

This is the most sensitive method to obtain an uncontaminated urine sample in this age group (24-26). Using ultrasound to assess bladder filling simplifies SPA and improves the diagnostic yield of obtaining a urine specimen from 60% to $\sim 97\%$ (25,26). Complications are rare and have been reported in only 0.22% of cases, ranging from transient haematuria to bowel perforation (27). However, bladder puncture causes more pain than catheterisation in infants < 2 months old (28).

In older, toilet-trained children, who can void on command, after carefully retracting the foreskin and cleaning the glans penis in boys and spreading the labia and cleaning the periurethral area in girls, the use of clean catch, especially midstream urine, could be an acceptable technique for obtaining urine. After cleaning the urethral meatus and perineum with gauze and liquid soap twice, the risk of contamination was reduced from 23.9% (41/171) to 7.8% (14/171) in a randomised trial (29).

If the clinical situation necessitates, and for differential diagnosis of sepsis, it is most appropriate to obtain an adequate urine sample by catheterisation or SPA (22). In infants, a bag can only be used if the dipstick is negative, otherwise the urine should be obtained through catheterisation or SPA. This is also recommended in children, who are severely ill and a UTI needs to be excluded or confirmed. Blood sampling is dependent on the clinical situation.

9.4.2 Urinalysis

There are three methods that are commonly used for urinalysis:

(1) Dipsticks.

These are appealing because they provide rapid results, do not require microscopy, and are ready to use. Leukocyte esterase (as a surrogate marker for pyuria) and nitrite (which is converted from dietary nitrates by most Gram-negative enteric bacteria in the urine) are the most frequent markers, and are usually combined in a dipstick test. The conversion of dietary nitrates to nitrites by bacteria requires approximately 4 h in the bladder (22,30). However, nitrite is not a very sensitive marker for infants, who empty their bladder frequently, and not all urinary pathogens reduce nitrate to nitrite. The test is helpful when the result is positive, because it is highly specific (i.e. there are few false-positive results) (1,22).

Table 3: Sensitivity and specificity of component of urinalysis, alone and in combination (22)*

Test	Sensitivity (Range), %	Specificity (Range), %
Leukocyte esterase test	83 (67-94)	78 (64-92)
Nitrite test	53 (15-82)	98 (90-100)
Leukocyte esterase or nitrite test positive	93 (90-100)	72 (58-91)
Microscopy, WBCs	73 (32-100)	81 (45-98)
Microscopy, bacteria	81 (16-99)	83 (11-100)
Leucocyte esterase test, nitrite test or microscopy positive	99.8 (99-100)	70 (60-92)

*Reproduced with permission from *Pediatrics* 2011 Sep;128(3):595-610, Copyright © 2011 by the AAP (22).

(2) Microscopy.

This is the standard method of assessing pyuria after centrifugation of the urine with a threshold of 5 white blood cells (WBCs) per high-power field (25 WBC/ μ L) (27). In uncentrifuged urine, ≥ 10 WBC/ μ L has been demonstrated to be sensitive for UTI (31) and this could perform well in clinical situations (32). However, this is rarely done in an outpatient setting.

(3) Flow imaging analysis technology.

This is being used increasingly to classify particles in uncentrifuged urine specimens (33). The numbers of WBCs, squamous epithelial cells and red cells correlate well with those found by manual methods (22).

9.4.3 Urine culture

After negative results for dipstick, microscopic or automated urinalysis, urine culture is generally not necessary, especially if there is an alternative source of fever. If the dipstick result is positive, confirmation by urine culture is recommended.

It is unclear what represents a significant UTI. In severe UTI, $> 10^5$ cfu/mL can be expected. However, the count can vary and be related to the method of specimen collection, diuresis, and time and temperature of storage until cultivation occurs (34). The classical definition of $> 10^5$ cfu/mL of voided urine is still used to define a significant UTI (35,36). The recent American Academy of Pediatric Guidelines on Urinary tract infection suggest that the diagnosis should be on the basis of the presence of both pyuria and at least 50 000 cfu. However, some studies have shown that, in voided specimens, $\leq 10^4$ organisms may indicate a significant UTI (37,38). If urine is obtained by catheterisation, 1,000–50,000 cfu/mL is considered to be positive, and any counts obtained after SPA should be considered as significant. Mixed cultures are indicative of contamination.

Table 4: Criteria for UTI in children (adapted from the EAU Guideline on Urological Infections [39])

Urine specimen from suprapubic bladder puncture	Urine specimen from bladder catheterisation	Urine specimen from midstream void
Any number of cfu/mL (at least 10 identical colonies)	$\geq 1,000$ –50,000 cfu/mL	$\geq 10^4$ cfu/mL with symptoms $\geq 10^5$ cfu/mL without symptoms

Pyuria without bacteriuria (sterile pyuria) may be due to incomplete antibiotic treatment, urolithiasis, or foreign bodies in the urinary tract, and infections caused by *Mycobacterium tuberculosis* or *Chlamydia trachomatis*.

9.5 Therapy

9.5.1 Administration route

The choice between oral and parenteral therapy should be based on patient age; clinical suspicion of urosepsis; illness severity; refusal of fluids, food and/or oral medication; vomiting; diarrhoea; non-compliance; and complicated pyelonephritis (e.g. urinary obstruction). As a result of the increased incidence of urosepsis and severe pyelonephritis in newborns and infants aged < 2 months, parenteral antibiotic therapy is recommended. Electrolyte disorders with hyponatremia and hyperkalaemia can occur in these cases (13). Combination treatment with ampicillin and an aminoglycoside (e.g. tobramycin or gentamicin) or respectively a third-generation cephalosporin achieves excellent therapeutic results (high efficacy of aminoglycosides, respectively cephalosporines against common uropathogens; enterococcus gap is closed with Ampicillin). Compared to the division in two doses, a daily single dose of aminoglycosides is safe and effective (13,40,41).

The choice of agent is also based on local antimicrobial sensitivity patterns, and should later be adjusted according to sensitivity testing of the isolated uropathogen (22). Especially in infancy, not all available antibiotics are approved by the national health authorities. In uncomplicated nephritis, both oral and parenteral treatment can be considered, because both are equally effective in children without urinary tract abnormalities. Some studies have demonstrated that once daily parenteral administration of gentamicin or ceftriaxone in a day treatment centre is safe, effective and cost-effective in children with UTI (41–43).

9.5.2 Duration of therapy

Adequate treatment of UTI can prevent the spread of infection and renal scarring. Outcomes of short courses (1–3 days) are inferior to those of 7–4-day courses (22). In newborns and young infants with a febrile UTI, up to 20% may have a positive blood culture (8,13). In late infancy, there are no differences between strategies regarding the incidence of parenchymal scars, as diagnosed with DMSA (dimercaptosuccinic acid) scan (44). Some recent studies using exclusively oral therapy with a third-generation cephalosporin (e.g. cefixime or cefixime) have demonstrated that this is equivalent to the usual 2–4 days intravenous therapy followed by oral treatment (40,45–47). Similar data have been shown for amoxicillin-clavulanate (48), however, these antibiotics are associated with increasing rates of resistance. If ambulatory therapy is chosen, adequate surveillance, medical supervision and, if necessary, adjustment of therapy must be guaranteed. In the initial phase of therapy, a close ambulant contact to the family is advised (49).

In complicated UTI, uropathogens other than *E. coli*, such as *Proteus mirabilis*, *Klebsiella* spp., *Pseudomonas aeruginosa*, enterococci and staphylococci, are more often to be anticipated (13). Parenteral treatment with broad-spectrum antibiotics is preferred. A temporary urinary diversion (suprapubic cystostomy or percutaneous nephrostomy) might be required in case of failure of conservative treatment in obstructive uropathy.

Acute focal bacterial nephritis (lobar nephronia) is a localised bacterial infection of the kidney that presents as an inflammatory mass without abscess formation. This may represent a relatively early stage of renal abscess. For the majority of children, the pathogenesis is related to ascending infection due to pre-existing uropathy, especially vesicorenal reflux or urinary obstruction (megaureter). Prolonged intravenous antibiotic treatment is sufficient in most cases (50), and intravenous and oral therapy tailored to the pathogen identified in culture is recommended (51).

9.5.3 Antimicrobial agents

Table 5: Frequently used antibacterial substances for the therapy of urinary tract infections in infants and children*

Chemotherapeutics	Daily dosage	Application	Comments
Parenteral cephalosporins			
Group 3a, e.g. cefotaxime	100-200 mg/kg (Adolesc.: 3-6 g)	i.v. in 2-3 D	
Group 3b, e.g. ceftazidime	100-150 mg/kg (Adolesc.: 2-6 g)	i.v. in 2-3 D	
Ceftriaxone	75 mg/kg,	i.v. in 1 D	
Oral cephalosporins			
Group 3, e.g. ceftibuten	9 mg/kg (Adolesc.: 0,4 g)	p.o. in 1-2 D p.o. in 1-2 D	
Group 3, e.g. cefixime	8-12 mg/kg (Adolesc.: 0,4 g)	p.o. in 1-2 D	
Group 2, e.g. cefpodoxime proxetil	8-10 mg/kg (Adolesc.: 0,4 g)	p.o. in 2D	
Group 2, e.g. cefuroximaxetil	20-30 mg/kg (Adolesc.: 0,5-1 g)	p.o. in 3 D	
Group 1, e.g. cefaclor	50 -100 mg/kg (Adolesc.: 1,5-4 g)	p.o. in 2-3 D	
Trimethoprim or Trimethoprim/sulfamethoxazole	5-6 mg/kg 5-6 mg/kg (TMP-Anteil) (Adolesc.: 320 mg)	p.o. in 2 D p.o. in 2 D	
Ampicillin	100-200 mg/kgKG (Adolesc.: 3-6 g)	i.v. in 3 D i.v. in 3-4 D	Ampicillin and Amoxicillin are not eligible for calculated therapy
Amoxicillin	50-100 mg/kg (Adolesc.: 1,5-6 g)	p.o. in 2-3 D ¹ p.o. in 2-3 D	
Amoxicillin/clavulanic acid (parenteral)	60-100 mg/kg (Adolesc.: 3,6-6,6 g)	i.v. in 3 D i.v. in 3 D	
Amoxicillin/clavulanic acid (oral)	45-60 mg/kg (Amoxicillin-fraction) (Adolesc.: 1500 + 375 mg)	p.o. in 3 D p.o.in 3 D	
Piperacillin	300 mg/kg	i.v. in 3-4 D	
Tobramycin	5 mg/kg (Adolesc.: 3-5 mg/kg, max. 0,4 g)	i.v. in 1 D	Drug monitoring
Gentamicin	5 mg/kg (Adolesc.: 3-5 mg/kg, max. 0,4g)	i.v. in 1 D	

Ciprofloxacin	Children and adolesc. (1-17 years of age): 20-30 mg/kg (max. D: 400 mg) (parenterally) Children and adolesc. (1-17 years of age): 20-40 mg/kg (max. D 750 mg) (orally)	i.v. in 3 D p.o. in 2 D	Approved in most European countries as second- or third line medication for complicated UTIs, „reserve-antibiotic“ !
Nitrofurantoin	3-5 mg	p.o. in 2 D	Contraindicated in the case of renal insufficiency

* Reproduced with permission from the International Consultation on Urological Diseases (ICUD), International Consultation on Urogenital Infections, 2009. Copyright © by the European Association of Urology (52).

Dosage for adolescents in paracentesis, if differing.

¹ Infants 2 D, children 1-12 ys. 3 D.

Table 6: Recommendations for calculated antibacterial therapy of pyelonephritis dependent on age and severity of the infection*

Diagnosis	Proposal	Application	Duration of therapy	LE
Pyelonephritis during the first 0-6 months of life	Ceftazidime + Ampicillin ¹ or Aminoglycoside + Ampicillin ¹	3-7 days parenterally, for at least 2 days after defervescence, then oral therapy ² In newborns: parenteral therapy for 7-14 days, then oral therapy ²	10 (-14) days Newborns 14-21 days	4
Uncomplicated pyelonephritis after 6 months of age	Cephalosporin group 3 ²	Orally (initially parenterally, if necessary)	(7-)10 days	1
Complicated pyelonephritis/ urosepsis (all ages)	Ceftazidime + Ampicillin ¹ or Aminoglycoside + Ampicillin ¹	7 days parenterally, then oral therapy ²	10-14 days	4

* Reproduced with permission from the International Consultation on Urological Diseases (ICUD), International Consultation on Urogenital Infections, 2009. Copyright © by the European Association of Urology (52).

¹ after receipt of microbiological findings (pathogen, resistance) adaptation of therapy.

² i.v.: e.g. cefotaxime; orally: e.g. cefpodoxime proxetil, ceftibuten, cefixime.

Table 7: Recommendations for antibacterial treatment in cystitis und cystourethritis
(Dosages for children up to 12 years of age)*

Chemotherapeutics	Daily dosage	Application
Oral cephalosporins		
Group 1, e.g. cefaclor	50 (-100) mg/kgbw	p.o. in 2-3 D
Group 1, e.g. cefalexin	50 mg/kgbw	p.o. in 3-4 D
Group 2, e.g. cefuroximaxetil	20-30 mg/kgbw	p.o. in 2 D
Group 2, e.g. cefpodoxime proxetil	8-10 mg/kgbw	p.o. in 2 D
Group 3, e.g. ceftibuten	9 mg/kgbw	p.o. in 1 D
Trimethoprim	5-6 mg/kgbw	p.o. in 2 D

Trimethoprim/sulfamethoxazole	5-6 mg/kgbw /TMP-fraction)	p.p. in 3 D
Amoxicillin/clavulanic acid	37.5-75 mg/kgbw (Amoxicillin-fraction)	p.o. in 3 D
Nitrofurantoin	3-5 mg/kgbw	p.o. in 2 D

* Reproduced with permission from the International Consultation on Urological Diseases (ICUD), International Consultation on Urogenital Infections, 2009. Copyright © by the European Association of Urology (52).

9.5.4 Chemoprophylaxis

Long-term antibacterial prophylaxis should be considered in cases of high susceptibility to UTI and risk of acquired renal damage. Some recently published prospective, randomised studies do not support the efficacy of antibacterial prophylaxis (53-56). The Australian PRIVENT study demonstrated risk reduction using trimethoprim-sulfamethoxazole in children from birth to 18 years of age who had at least one symptomatic UTI (19% of the placebo group and 13% of the antibiotic group) (46) (see also Chapter 15).

Table 8: Drugs for antibacterial prophylaxis*

Substance**	Prophylactic dosage (mg/kgbw/d)	Limitations in young infants
Trimethoprim	1	until 6 weeks of age
Nitrofurantoin	1	Until 3 months of age
Cefaclor	10	No age limitations
Cefixim	2	Preterms and newborns
Ceftibuten	2	***
Cefuroximaxetil	5	***

* Reproduced with permission from the International Consultation on Urological Diseases (ICUD), International Consultation on Urogenital Infections, 2009. Copyright © by the European Association of Urology.

** Substances of first choice are nitrofurantoin and trimethoprim. In exceptional cases, oral cephalosporin can be used.

*** In Germany, ceftibuten is not approved for infants < 3 months old.

9.6 Monitoring of UTI

With successful treatment, urine usually becomes sterile after 24 h, and leukocyturia normally disappears within 3-4 days. Normalisation of body temperature can be expected within 24-48 h after the start of therapy in 90% of cases. In patients with prolonged fever and failing recovery, treatment-resistant uropathogens or the presence of congenital uropathy or acute urinary obstruction should be considered. Immediate ultrasound examination is recommended in these cases.

Procalcitonin (among other laboratory inflammatory parameters such as C-reactive protein and leukocyte count) can be used as reliable serum marker for early prediction of renal parenchymal inflammation with first febrile UTI (57). In patients with febrile UTI, serum electrolytes and blood cell counts should be obtained.

9.7 Imaging

9.7.1 Ultrasound

Renal and bladder ultrasonography is strongly recommended in infants with febrile UTI to exclude obstruction of the upper and lower urinary tract. Abnormal results are found in ~15% of cases, and 1-2% have abnormalities that require prompt action (e.g., additional evaluation, referral, or surgery) (22). In other studies, renal ultrasound revealed abnormalities in up to 37% of cases, whereas voiding cystourethrography (VCUG) showed vesicoureteral reflux (VUR) in 27% of cases (9). Dilating VUR is missed by ultrasound in around one third of cases (58). Post-void residual urine should be measured in toilet-trained children to exclude voiding abnormalities as a cause of UTI.

9.7.2 Radionuclide scanning

Changes in DMSA clearance during acute UTI indicate pyelonephritis or parenchymal damage, correlated well with the presence of dilating reflux and the risk of further pyelonephritis episodes, break-through-infections

(59) and future renal scarring. DMSA scanning may be used as a first-line diagnostic procedure based on observations that dilating VUR occurs in almost all children with abnormal DMSA scan (58,60). These findings are different in neonates. After the first symptomatic, community-acquired UTI, the majority of renal units with VUR grade III or higher had normal early DMSA scanning (61).

9.7.3 Voiding cystourethrography

Voiding cystourethrography is still the gold standard to exclude or confirm VUR. Due to the risk of renal scarring, VCUG is recommended after the first episode of febrile UTI in boys and girls. The timing of VCUG does not influence the presence or severity of VUR (62,63). Performance of early VCUG in patients with proven sterile urine does not cause any significant morbidity (64). Another option is doing DMSA first, followed by VCUG if there is renal cortical uptake deficiency after urinary tract infection (see Chapter 15).

9.8 Bladder and bowel dysfunction

Bladder and bowel dysfunction are risk factors for which each child with UTI should be screened upon presentation. Normalisation of micturition disorders or bladder overactivity is important to lower the rate of UTI recurrence. If there are signs of bladder and/or bowel dysfunction at infection-free intervals, further diagnosis and effective treatment are strongly recommended (65-68). Treatment of constipation leads to a decrease in UTI recurrence (69-71). Therefore, exclusion of bladder and bowel dysfunction is strongly recommended in any child with febrile and/or recurrent UTI, and it should be treated if there is evidence of a dysfunctional elimination syndrome.

9.9 Conclusions and recommendations for UTI in children

Conclusions
Urinary tract infection represents the most common bacterial infection in children < 2 years of age. The incidence varies depending on age and sex.
Classifications can be made according to the site, episode, severity, symptoms and complicating factors. For acute treatment, site and severity are most important.
The number of colony forming units (cfu) in the urine culture can vary and be related to the method of specimen collection, diuresis, and time and temperature of storage until cultivation occurs. The classical definition of > 10 ⁵ cfu/mL of voided urine is still used to define a significant UTI.

Recommendations		LE	GR
Diagnosis includes medical history, clinical signs and symptoms (signs of a UTI may be vague and unspecific in small children) as well as a physical examination (including a general examination as well as the genitalia).			
Exclusion of bladder and bowel dysfunction is strongly recommended in any child with febrile and/or recurrent UTI, and it should be treated if there is evidence of a dysfunctional elimination syndrome.			
Urine sampling	Urine sampling with plastic bags are commonly used in daily practice. They are helpful only when the dipstick and / or the culture result are negative. There is high risk of false positive results.	3	B
	Clean-catch of urine could be an acceptable technique for obtaining urine only in toilet-trained children.	2b	B
	Bladder catheterisation is traumatic especially in boys. It may be an alternative to suprapubic bladder aspiration.	2b	B
	Suprapubic bladder aspiration is the most sensitive method to obtain an uncontaminated urine sample in an infant.	2a	B
Urinalysis	Dipsticks yield rapid results, but should be used with caution in infants who empty their bladder frequently as conversion of nitrates to nitrites by bacteria requires approximately 4 h.	2a	B
	Microscopic investigation is the standard method of assessing pyuria after centrifugation, but it is rarely done in an outpatient setting.	2a	B
	Flow imaging analysis is increasingly used to classify particles in uncentrifuged urine, The numbers of WBCs, squamous epithelial cells and red cells correlate well with manual methods.	3	B

Treatment	The choice between oral and parenteral therapy should be based on patient age; clinical suspicion of urosepsis; illness severity; refusal of fluids, food and/or oral medication; vomiting; diarrhoea; non-compliance; and complicated pyelonephritis (e.g., urinary obstruction).		
	Long-term antibacterial prophylaxis should be considered in cases of high susceptibility to UTI and risk of acquired renal damage.		
	Parenteral therapy is advised when there is clinical suspicion of urosepsis; illness severity; refusal of fluids, food and/or oral medication; vomiting; diarrhoea; non-compliance; and complicated UTI. As a result of the increased incidence of urosepsis and severe pyelonephritis in newborns and infants aged < 2 months, parenteral antibiotic therapy is recommended. In an emergency setting, i.v. fluid replacement is necessary.	2a	B
	Outcomes of short courses (1-3 days) are inferior to those of 7-4-day courses. Oral therapy with a third-generation cephalosporin (e.g., cefixime or ceftibuten) may be equivalent to the usual 2-4 days intravenous therapy followed by oral treatment. In complicated UTI, parenteral treatment with broad-spectrum antibiotics is indicated.	1b	B
Imaging	Renal and bladder ultrasonography is strongly recommended in infants with febrile UTI to exclude obstruction of the upper and lower urinary tract.	3	B
	Changes in DMSA clearance during acute UTI indicate pyelonephritis or parenchymal damage. If it is positive, reflux may be present.	2b	B
	VCUG is the gold standard to exclude or confirm VUR. Due to the risk of renal scarring, it is recommended after the first episode of febrile UTI in boys and girls. The timing of VCUG does not influence the presence or severity of VUR.	2a	B

9.10 References

1. Kunin CM, DeGroot JE. Sensitivity of a nitrite indicator strip method in detecting bacteriuria in preschool girls. *Pediatrics* 1977 Aug;60(2):244-5.
<http://www.ncbi.nlm.nih.gov/pubmed/887340>
2. Shaikh N, Morone NE, Bost JE, Farrell MH. Prevalence of urinary tract infection in childhood: a meta-analysis. *Pediatr Infect Dis J* 2008 Apr;27(4):302-8.
<http://www.ncbi.nlm.nih.gov/pubmed/18316994>
3. Winberg J, Andersen HJ, Bergstrom T, et al. Epidemiology of symptomatic urinary tract infection in childhood. *Acta Paediatrica Scandinavica Supplement* 1974(252):1-20.
<http://www.ncbi.nlm.nih.gov/pubmed/4618418>
4. Zorc JJ, Levine DA, Platt SL, et al. Clinical and demographic factors associated with urinary tract infection in young febrile infants. *Pediatrics* 2005 Sep;116(3):644-8.
<http://www.ncbi.nlm.nih.gov/pubmed/16140703>
5. Kanellopoulos TA, Salakos C, Spiliopoulou I, et al. First urinary tract infection in neonates, infants and young children: a comparative study. *Pediatr Nephrol* 2006 Aug;21(8):1131-7.
<http://www.ncbi.nlm.nih.gov/pubmed/16810514>
6. Kunin CM, Deutscher R, Paquin A Jr. Urinary Tract Infection in School Children: An Epidemiologic, Clinical and Laboratory Study. *Medicine (Baltimore)* 1964 Mar;43:91-130.
<http://www.ncbi.nlm.nih.gov/pubmed/14129871>
7. Rushton HG, Majd M. Pyelonephritis in male infants: how important is the foreskin? *J Urol* 1992 Aug;148(2 Pt 2):733-6.
<http://www.ncbi.nlm.nih.gov/pubmed/1640557>
8. Magin EC, Garcia-Garcia JJ, Sert SZ, et al. Efficacy of short-term intravenous antibiotic in neonates with urinary tract infection. *Pediatr Emerg Care* 2007 Feb;23(2):83-6.
<http://www.ncbi.nlm.nih.gov/pubmed/17351406>

9. Sastre JB, Aparicio AR, Cotallo GD, et al. Urinary tract infection in the newborn: clinical and radio imaging studies. *Pediatr Nephrol* 2007 Oct;22(10):1735-41.
<http://www.ncbi.nlm.nih.gov/pubmed/17665222>
10. Shortliffe LMD. Infection and inflammation of the pediatric genitourinary tract In: Wein AJ, Kavoussi LR, Novick AC, Partin AW, Peters CA, editors. *Campbell-Walsh Urology*. 9th ed. Philadelphia: Saunders; 2007. p.p. 3232-68.
11. Shortliffe LMD, Shinghal R, Seto EH. Pediatric urinary tract infections. In: Gearhart JP, Rink RC, Mouriquand PDE, editors. *Pediatric urology*. 1st edn. Philadelphia: Saunders; 2001. p.p. 237-58.
12. Burns MW, Burns JL, Krieger JN. Pediatric urinary tract infection. Diagnosis, classification, and significance. *Pediatr Clin North Am* 1987 Oct;34(5):1111-20.
<http://www.ncbi.nlm.nih.gov/pubmed/3658502>
13. Beetz R, Bachmann H, Gatermann S, et al. [Urinary tract infections in infants and children -- a consensus on diagnostic, therapy and prophylaxis]. *Urologe A* 2007 Feb;46(2):112,114-8,120-3. [Article in German]
<http://www.ncbi.nlm.nih.gov/pubmed/17225140>
14. American Academy Pediatrics CoQlaSoUTI. Practice parameter: The diagnosis, treatment, and evaluation of the initial urinary tract infection in febrile infants and young children. *Pediatrics* 1999 Apr;103(4 Pt 1):843-52.
<http://www.ncbi.nlm.nih.gov/pubmed/10103321>
15. Lin DS, Huang SH, Lin CC, et al. Urinary tract infection in febrile infants younger than eight weeks of Age. *Pediatrics* 2000 Feb;105(2):E20.
<http://www.ncbi.nlm.nih.gov/pubmed/10654980>
16. Tullus K. Difficulties in diagnosing urinary tract infections in small children. *Pediatr Nephrol* 2011 Nov;26(11):1923-6.
<http://www.ncbi.nlm.nih.gov/pubmed/21773821>
17. Craig JC, Williams GJ, Jones M, et al. The accuracy of clinical symptoms and signs for the diagnosis of serious bacterial infection in young febrile children: prospective cohort study of 15 781 febrile illnesses. *BMJ* 2010 Apr;340:c1594.
<http://www.ncbi.nlm.nih.gov/pubmed/20406860>
18. Whiting P, Westwood M, Watt I, et al. Rapid tests and urine sampling techniques for the diagnosis of urinary tract infection (UTI) in children under five years: a systematic review. *BMC Pediatr* 2005;5(1):4.
<http://www.ncbi.nlm.nih.gov/pubmed/15811182>
19. Ma JF, Shortliffe LM. Urinary tract infection in children: etiology and epidemiology. *Urol Clin North Am* 2004 Aug;31(3):517-26.
<http://www.ncbi.nlm.nih.gov/pubmed/15313061>
20. Koch VH, Zuccolotto SM. [Urinary tract infection: a search for evidence]. *J Pediatr (Rio J)* 2003 May;79 Suppl 1:S97-106.
<http://www.ncbi.nlm.nih.gov/pubmed/14506522>
21. Ramage IJ, Chapman JP, Hollman AS, et al. Accuracy of clean-catch urine collection in infancy. *J Pediatr*. 1999 Dec;135(6):765-7.
<http://www.ncbi.nlm.nih.gov/pubmed/10586183>
22. Subcommittee On Urinary Tract I, Steering Committee On Quality I, Management. Urinary Tract Infection: Clinical Practice Guideline for the Diagnosis and Management of the Initial UTI in Febrile Infants and Children 2 to 24 Months. *Pediatrics* 2011 Aug 28. [Epub ahead of print]
<http://www.ncbi.nlm.nih.gov/pubmed/21873693>
23. Austin BJ, Bollard C, Gunn TR. Is urethral catheterization a successful alternative to suprapubic aspiration in neonates? *J Paediatr Child Health* 1999 Feb;35(1):34-6.
<http://www.ncbi.nlm.nih.gov/pubmed/10234632>
24. Wingerter S, Bachur R. Risk factors for contamination of catheterized urine specimens in febrile children. *Pediatr Emerg Care* 2011 Jan;27(1):1-4.
<http://www.ncbi.nlm.nih.gov/pubmed/21178815>
25. Buys H, Pead L, Hallett R, et al. Suprapubic aspiration under ultrasound guidance in children with fever of undiagnosed cause. *BMJ* 1994 Mar 12;308(6930):690-2.
<http://www.ncbi.nlm.nih.gov/pubmed/8142792>
26. Kiernan SC, Pinckert TL, Keszler M. Ultrasound guidance of suprapubic bladder aspiration in neonates. *J Pediatr* 1993 Nov;123(5):789-91.
<http://www.ncbi.nlm.nih.gov/pubmed/8229492>
27. Hildebrand WL, Schreiner RL, Stevens DC, et al. Suprapubic bladder aspiration in infants. *Am Fam Physician* 1981 May;23(5):115-8.
<http://www.ncbi.nlm.nih.gov/pubmed/7234629>

28. Kozer E, Rosenbloom E, Goldman D, et al. Pain in infants who are younger than 2 months during suprapubic aspiration and transurethral bladder catheterization: a randomized, controlled study. *Pediatrics* 2006 Jul;118(1):e51-6.
<http://www.ncbi.nlm.nih.gov/pubmed/16818537>
29. Vaillancourt S, McGillivray D, Zhang X, et al. To clean or not to clean: effect on contamination rates in midstream urine collections in toilet-trained children. *Pediatrics* 2007 Jun;119(6):e1288-93.
<http://www.ncbi.nlm.nih.gov/pubmed/17502345>
30. Powell HR, McCredie DA, Ritchie MA. Urinary nitrite in symptomatic and asymptomatic urinary infection. *Arch Dis Child* 1987 Feb;62(2):138-40.
<http://www.ncbi.nlm.nih.gov/pubmed/3548604>
31. Hoberman A, Wald ER, Reynolds EA, et al. Is urine culture necessary to rule out urinary tract infection in young febrile children? *Pediatr Infect Dis J* 1996 Apr;15(4):304-9.
<http://www.ncbi.nlm.nih.gov/pubmed/8866798>
32. Herr SM, Wald ER, Pitetti RD, et al. Enhanced urinalysis improves identification of febrile infants ages 60 days and younger at low risk for serious bacterial illness. *Pediatrics* 2001 Oct;108(4):866-71.
<http://www.ncbi.nlm.nih.gov/pubmed/11581437>
33. Mayo S, Acevedo D, Quinones-Torrel C, et al. Clinical laboratory automated urinalysis: comparison among automated microscopy, flow cytometry, two test strips analyzers, and manual microscopic examination of the urine sediments. *J Clin Lab Anal* 2008;22(4):262-70.
<http://www.ncbi.nlm.nih.gov/pubmed/18623125>
34. Zorc JJ, Kiddoo DA, Shaw KN. Diagnosis and management of pediatric urinary tract infections. *Clin Microbiol Rev* 2005 Apr;18(2):417-22.
<http://www.ncbi.nlm.nih.gov/pubmed/15831830>
35. Kass EH. Asymptomatic infections of the urinary tract. *Transactions of the Association of American Physicians* 1956;69:56-64.
<http://www.ncbi.nlm.nih.gov/pubmed/13380946>
36. Lohr JA. Use of routine urinalysis in making a presumptive diagnosis of urinary tract infection in children. *Pediatr Infect Dis J* 1991 Sep;10(9):646-50.
<http://www.ncbi.nlm.nih.gov/pubmed/1923675>
37. Bollgren I, Engstrom CF, Hammarlind M, et al. Low urinary counts of P-fimbriated *Escherichia coli* in presumed acute pyelonephritis. *Arch Dis Child* 1984 Feb;59(2):102-6.
<http://www.ncbi.nlm.nih.gov/pubmed/61426977>
38. Stamm WE. Measurement of pyuria and its relation to bacteriuria. *Am J Med* 1983 Jul 28;75(1B):53-8.
<http://www.ncbi.nlm.nih.gov/pubmed/6349345>
39. Grabe M, Bjerklund-Johansen T-E, Botto H, et al; EAU working group on Urological Infections. EAU Guidelines on Urological Infections, edn. Presented at the EAU Annual Congress 2011, ISBN 978-90-79754-96-0. European Association of Urology, Arnhem, The Netherlands
40. Hodson EM, Willis NS, Craig JC. Antibiotics for acute pyelonephritis in children. *Cochrane Database Syst Rev* 2007(4):CD003772.
<http://www.ncbi.nlm.nih.gov/pubmed/17943796>
41. Contopoulos-Ioannidis DG, Giotis ND, Baliatsa DV, et al. Extended-interval aminoglycoside administration for children: a meta-analysis. *Pediatrics* 2004 Jul;114(1):e111-8.
<http://www.ncbi.nlm.nih.gov/pubmed/15231982>
42. Dore-Bergeron MJ, Gauthier M, Chevalier I, et al. Urinary tract infections in 1- to 3-month-old infants: ambulatory treatment with intravenous antibiotics. *Pediatrics* 2009 Jul;124(1):16-22.
<http://www.ncbi.nlm.nih.gov/pubmed/19564278>
43. Gauthier M, Chevalier I, Sterescu A, et al. Treatment of urinary tract infections among febrile young children with daily intravenous antibiotic therapy at a day treatment center. *Pediatrics* 2004 Oct;114(4):e469-76.
<http://www.ncbi.nlm.nih.gov/pubmed/15466073>
44. Bouissou F, Munzer C, Decramer S, et al. Prospective, randomized trial comparing short and long intravenous antibiotic treatment of acute pyelonephritis in children: dimercaptosuccinic acid scintigraphic evaluation at 9 months. *Pediatrics* 2008 Mar;121(3):e553-60.
<http://www.ncbi.nlm.nih.gov/pubmed/18267977>
45. Hoberman A, Wald ER, Hickey RW, et al. Oral versus initial intravenous therapy for urinary tract infections in young febrile children. *Pediatrics* 1999 Jul;104(1 Pt 1):79-86.
<http://www.ncbi.nlm.nih.gov/pubmed/10390264>
46. Craig JC, Simpson JM, Williams GJ, et al. Antibiotic prophylaxis and recurrent urinary tract infection in children. *N Engl J Med* 2009 Oct 29;361(18):1748-59.
<http://www.ncbi.nlm.nih.gov/pubmed/19864673>

47. Neuhaus TJ, Berger C, Buechner K, et al. Randomised trial of oral versus sequential intravenous/oral cephalosporins in children with pyelonephritis. *Eur J Pediatr* 2008 Sep;167(9):1037-47.
<http://www.ncbi.nlm.nih.gov/pubmed/18074149>
48. Montini G, Toffolo A, Zucchetto P, et al. Antibiotic treatment for pyelonephritis in children: multicentre randomised controlled non-inferiority trial. *BMJ* 2007 Aug 25;335(7616):386.
<http://www.ncbi.nlm.nih.gov/pubmed/17611232>
49. Mak RH, Wong JH. Are oral antibiotics alone efficacious for the treatment of a first episode of acute pyelonephritis in children? *Nat Clin Pract Nephrol* 2008 Jan;4(1):10-1.
<http://www.ncbi.nlm.nih.gov/pubmed/17971799>
50. Klar A, Hurvitz H, Berkun Y, et al. Focal bacterial nephritis (lobar nephronia) in children. *J Pediatr* 1996 Jun;128(6):850-3.
<http://www.ncbi.nlm.nih.gov/pubmed/8648547>
51. Cheng CH, Tsau YK, Lin TY. Effective duration of antimicrobial therapy for the treatment of acute lobar nephronia. *Pediatrics* 2006 Jan;117(1):e84-9.
<http://www.ncbi.nlm.nih.gov/pubmed/16326693>
52. Naber KG (chair), Schaeffer AJ, Hynes CF, et al (Eds) (2010). *EAU/International Consultation on Urological Infections*. The Netherlands, European Association of Urology.
53. Montini G, Rigon L, Zucchetto P, et al. Prophylaxis after first febrile urinary tract infection in children? A multicenter, randomized, controlled, noninferiority trial. *Pediatrics* 2008 Nov;122(5):1064-71.
<http://www.ncbi.nlm.nih.gov/pubmed/18977988>
54. Garin EH, Olavarria F, Garcia Nieto V, et al. Clinical significance of primary vesicoureteral reflux and urinary antibiotic prophylaxis after acute pyelonephritis: a multicenter, randomized, controlled study. *Pediatrics* 2006 Mar;117(3):626-32.
<http://www.ncbi.nlm.nih.gov/pubmed/16510640>
55. Pennesi M, Travan L, Peratoner L, et al. Is antibiotic prophylaxis in children with vesicoureteral reflux effective in preventing pyelonephritis and renal scars? A randomized, controlled trial. *Pediatrics* 2008 Jun;121(6):e1489-94.
<http://www.ncbi.nlm.nih.gov/pubmed/18490378>
56. Roussey-Kesler G, Gadjos V, Idres N, et al. Antibiotic prophylaxis for the prevention of recurrent urinary tract infection in children with low grade vesicoureteral reflux: results from a prospective randomized study. *J Urol* 2008 Feb;179(2):674-9.
<http://www.ncbi.nlm.nih.gov/pubmed/18082208>
57. Kotoula A, Gardikis S, Tsalkidis A, et al. Comparative efficacies of procalcitonin and conventional inflammatory markers for prediction of renal parenchymal inflammation in pediatric first urinary tract infection. *Urology* 2009 Apr;73(4):782-6.
<http://www.ncbi.nlm.nih.gov/pubmed/19152962>
58. Preda I, Jodal U, Sixt R, et al. Value of ultrasound in evaluation of infants with first urinary tract infection. *J Urol* 2010 May;183(5):1984-8.
<http://www.ncbi.nlm.nih.gov/pubmed/20303537>
59. Shiraishi K, Yoshino K, Watanabe M, et al. Risk factors for breakthrough infection in children with primary vesicoureteral reflux. *J Urol* 2010 Apr;183(4):1527-31.
<http://www.ncbi.nlm.nih.gov/pubmed/20172558>
60. Quirino IG, Silva JM, Diniz JS, et al. Combined use of late phase dimercapto-succinic acid renal scintigraphy and ultrasound as first line screening after urinary tract infection in children. *J Urol* 2011 Jan;185(1):258-63.
<http://www.ncbi.nlm.nih.gov/pubmed/21074813>
61. Siomou E, Giapros V, Fotopoulos A, et al. Implications of 99mTc-DMSA scintigraphy performed during urinary tract infection in neonates. *Pediatrics* 2009 Sep;124(3):881-7.
<http://www.ncbi.nlm.nih.gov/pubmed/19661052>
62. Doganis D, Mavrikou M, Delis D, et al. Timing of voiding cystourethrography in infants with first time urinary infection. *Pediatr Nephrol* 2009 Feb;24(2):319-22.
<http://www.ncbi.nlm.nih.gov/pubmed/18853200>
63. Sathapornwajana P, Dissaneewate P, McNeil E, et al. Timing of voiding cystourethrogram after urinary tract infection. *Arch Dis Child* 2008 Mar;93(3):229-31.
<http://www.ncbi.nlm.nih.gov/pubmed/17626141>
64. Spencer JD, Bates CM, Mahan JD, et al. The accuracy and health risks of a voiding cystourethrogram after a febrile urinary tract infection. *J Pediatr Urol* 2010 Dec 1.
<http://www.ncbi.nlm.nih.gov/pubmed/21126919>

65. Koff SA, Wagner TT, Jayanthi VR. The relationship among dysfunctional elimination syndromes, primary vesicoureteral reflux and urinary tract infections in children. *J Urol* 1998 Sep;160(3 Pt 2): 1019-22.
<http://www.ncbi.nlm.nih.gov/pubmed/9719268>
66. Hoebeke P, Vande Walle J, Everaert K, et al. Assessment of lower urinary tract dysfunction in children with non-neuropathic bladder sphincter dysfunction. *Eur Urol* 1999 Jan;35(1):57-69.
<http://www.ncbi.nlm.nih.gov/pubmed/9933796>
67. van Gool JD. Dysfunctional voiding: a complex of bladder/sphincter dysfunction, urinary tract infections and vesicoureteral reflux. *Acta Urol Belg* 1995 Sep;63(3):27-33.
<http://www.ncbi.nlm.nih.gov/pubmed/7484519>
68. van Gool JD, Kuitjen RH, Donckerwolcke RA, et al. Bladder-sphincter dysfunction, urinary infection and vesico-ureteral reflux with special reference to cognitive bladder training. *Contrib Nephrol* 1984;39:190-210.
<http://www.ncbi.nlm.nih.gov/pubmed/6744871>
69. De Paepe H, Renson C, Van Laecke E, et al. Pelvic-floor therapy and toilet training in young children with dysfunctional voiding and obstipation. *BJU Int* 2000 May;85(7):889-93.
<http://www.ncbi.nlm.nih.gov/pubmed/10792172>
70. Loening-Baucke V. Urinary incontinence and urinary tract infection and their resolution with treatment of chronic constipation of childhood. *Pediatrics* 1997 Aug;100(2 Pt 1):228-32.
<http://www.ncbi.nlm.nih.gov/pubmed/9240804>
71. O'Regan S, Yazbeck S, Schick E. Constipation, bladder instability, urinary tract infection syndrome. *Clin Nephrol* 1985 Mar;23(3):152-4.
<http://www.ncbi.nlm.nih.gov/pubmed/3987104>

10. DAYTIME LOWER URINARY TRACT CONDITIONS

10.1 Background

Following the new terminology document by the International Children's Continence Society (ICCS), 'daytime lower urinary tract (LUT) conditions' is the new term used to group together functional incontinence problems in children (1). After any possible underlying uropathy or neuropathy has been excluded, a problem of incontinence in children is grouped into the category of 'daytime LUT conditions'. Night-time wetting is known as 'enuresis'.

Although exact data are unavailable, it is clear that the incidence of daytime LUT conditions is increasing. The changes in toilet training and toilet habits associated with a modern lifestyle have been blamed for the increase in incidence, but with little evidence. Rather, it is that modern life and higher hygiene standards have probably resulted in incontinence problems receiving more attention, so that an increase in prevalence could probably be attributed to an increased awareness. There exists a wide variation in reported prevalence ranging from 2% to 20% (2-6). This wide variation might reflect the variation in definitions used.

10.2 Definition

Daytime LUT conditions are conditions that present with lower urinary tract symptoms (LUTS), including urge, incontinence, weak stream, hesitancy, frequency and urinary tract infections, but without overt uropathy or neuropathy.

Normal bladder storage and voiding involves low pressure and adequate bladder volume filling. This is followed by a continuous detrusor contraction, which results in complete bladder emptying, associated with an adequate relaxation of the sphincter complex. Normal urine storage by the bladder and evacuation are controlled by a complex interaction between the spinal cord, brain stem, midbrain and higher cortical structures, associated with a complex integration of sympathetic, parasympathetic and somatic innervations (7).

It is understandable that this complex control mechanism is likely to be susceptible to developing different types of dysfunction. Various functional disorders of the detrusor-sphincter complex may occur during the sophisticated early development of normal mechanisms of micturition control. Voiding dysfunction is therefore thought to be the expression of incomplete or delayed maturation of the bladder sphincter complex.

Normal daytime control of bladder function matures between 2 and 3 years of age, while nighttime control is normally achieved between 3 and 7 years of age (8). There are two main groups of voiding

dysfunction, namely, filling-phase dysfunctions and voiding-phase dysfunctions.

10.2.1 *Filling-phase dysfunctions*

In filling-phase dysfunctions, the detrusor can be overactive, as in **overactive bladder (OAB) and urge syndrome**, or underactive, as in **underactive or highly compliant bladder (UAB)**. Some children habitually postpone micturition leading to **voiding postponement**.

10.2.2 *Voiding-phase (emptying) dysfunctions*

In voiding-phase (emptying) dysfunctions, interference with the sphincter and pelvic floor during detrusor contraction is the main dysfunction. The general term for this condition is dysfunctional voiding. Different degrees of dysfunction are described, depending on the strength of interference with the sphincter and pelvic floor. Weak interference results in staccato voiding, while stronger interference results in interrupted voiding and straining, due to an inability to relax during voiding.

Bladder sphincter dysfunction is often associated with bowel dysfunction such as obstipation and soiling. Sometimes, secondary anatomical changes are observed, such as trabeculation, diverticulae and vesicoureteral reflux.

10.3 **Diagnosis**

A non-invasive screening, consisting of history-taking, clinical examination, uroflow, ultrasound and voiding diary, is essential to reach a diagnosis. The ICCS published a standardisation document for the diagnosis of LUTS (9).

In the paediatric age group, where the history is taken from both the parents and child together, a structured approach is recommended using a questionnaire. Many signs and symptoms related to voiding and wetting will be unknown to the parents and should be specifically requested, using the questionnaire as a checklist. A voiding diary is mandatory to determine the child's voiding frequency and voided volumes as well as the child's drinking habits. History-taking should also include assessment of bowel function. Some dysfunctional voiding scores have recently been developed and validated (10,11). For evaluation of bowel function in children, the Bristol Stool Scale is an easy-to-use tool (12).

Upon clinical examination, genital inspection and observation of the lumbosacral spine and the lower extremities is necessary to exclude obvious uropathy and neuropathy. Uroflow with post-void residual evaluates the emptying ability, while an upper urinary tract ultrasound screens for secondary anatomical changes. A voiding diary provides information about storage function and incontinence frequency, while a pad test can help to quantify the urine loss.

In the case of resistance to initial treatment, or in the case of former failed treatment, re-evaluation is warranted and further video-urodynamic studies may be considered. Sometimes, there are minor, underlying, urological or neurological problems, which can only be suspected using video-urodynamics.

In the case of anatomical problems, such as urethral valve problems, syringocoeles, congenital obstructive posterior urethral membrane (COPUM) or Moormann's ring, it may be necessary to perform further cystoscopy with treatment. If neuropathic disease is suspected, MRI of the lumbosacral spine and medulla can help to exclude tethered cord, lipoma or other rare conditions.

Psychological screening may be useful for children or families with major psychological problems associated with the voiding dysfunction.

10.4 **Treatment**

Treatment of voiding dysfunction consists of lower urinary tract rehabilitation, mostly referred to as urotherapy. Urotherapy means non-surgical, non-pharmacological, treatment of lower urinary tract (LUT) function. It is a very broad therapy field, incorporating many treatments used by urotherapists and other healthcare professionals (13). In case of comorbidity due to bowel problems it is advised to treat the bowel first since bowel problems may sustain any bladder problems (12). Urotherapy can be divided into standard therapy and specific interventions.

10.4.1 *Standard therapy*

Standard urotherapy is defined as non-surgical, non-pharmacological, treatment for LUT malfunction. It includes the following components:

- Information and demystification, which includes explanation about normal LUT function and how a particular child deviates from normal function.
- Instruction about what to do about the problem, i.e. regular voiding habits, sound voiding posture, avoiding holding manoeuvres, etc.
- Lifestyle advice, regarding fluid intake, prevention of constipation, etc
- Registration of symptoms and voiding habits using bladder diaries or frequency-volume charts

- Support and encouragement via regular follow-up by the caregiver.

A success rate of 80% has been described for urotherapy programmes, independent of the components of the programme. However, the evidence level is low as most studies of urotherapy programmes are retrospective and non-controlled.

10.4.2 Specific interventions

As well as urotherapy, there are some specific interventions, including physiotherapy (e.g. pelvic floor exercises), biofeedback, alarm therapy and neurostimulation. Although good results with these treatment modalities have been reported, the level of evidence remains low, since only one RCT was published (13-19).

In some cases, pharmacotherapy may be added. Antispasmodics and anticholinergics have been shown to be effective, though the level of evidence was low. More recently, a few RCTs have been published. One trial on tolterodine showed safety but not efficacy (20), while another RCT on propiverine showed both safety and efficacy (21) (LE: 1). The difference in results is probably due to study design.

Despite the low level of evidence for the use of anticholinergics and antimuscarinics, their use is recommended (GR: B) because of the large number of studies reporting a positive effect on OAB symptoms.

Although alpha-blocking agents are used occasionally, an RCT showed no benefit (22). Botulinum toxin injection seems promising, but can only be used off-label (23). Other new treatment modalities such as sacral nerve stimulation are described in case series only and there is no evidence to whether they prove useful. These new treatment modalities can only be recommended for standard therapy resistant cases (24).

Recommendations for the treatment of daytime lower urinary tract conditions	LE	GR
Daytime LUTS in children are common and a stepwise treatment approach is recommended, starting with the least invasive approach.	4	B
Initial management consists of urotherapy. Urotherapy includes non-invasive training and reeducation, as well as non-invasive neurostimulation.	2	B
Pharmacotherapy (mainly antispasmodics and anticholinergics) would be the next step.	1	C
In case of therapy resistance, re-evaluation will be required which may consist of video-urodynamics and MRI of LS spine which can guide to off-label treatment like some of the non-licensed drugs in children, botulinum toxin injection and sacral nerve stimulation. Such treatment should only be offered in highly experienced centres.	3	C

10.5 References

1. Neveus T, von Gontard A, Hoebeke P, et al. The standardization of terminology of lower urinary tract function in children and adolescents: report from the Standardisation Committee of the International Children's Continence Society. *J Urol* 2006 Jul;176(1):314-24.
<http://www.ncbi.nlm.nih.gov/pubmed/16753432>
2. Hellström AL, Hanson E, Hansson S, et al. Micturition habits and incontinence in 7-year-old Swedish school entrants. *Eur J Pediatr* 1990 Mar;149(6):434-7.
<http://www.ncbi.nlm.nih.gov/pubmed/2332015>
3. Bakker E, van Sprundel M, van der Auwera JC, et al. Voiding habits and wetting in a population of 4,332 Belgian schoolchildren aged between 10 and 14 years. *Scand J Urol Nephrol* 2002;36(5):354-62.
<http://www.ncbi.nlm.nih.gov/pubmed/12487740>
4. Söderstrom U, Hoelcke M, Alenius L, et al. Urinary and faecal incontinence: a population-based study. *Acta Paediatr* 2004 Mar;93(3):386-9.
<http://www.ncbi.nlm.nih.gov/pubmed/15124844>
5. Sureshkumar P, Jones M, Cumming R, et al. A population based study of 2,856 school-age children with urinary incontinence. *J Urol* 2009 Feb;181(2):808-15; discussion 815-6.
<http://www.ncbi.nlm.nih.gov/pubmed/19110268>
6. Sureshkumar P, Craig JC, Roy LP, et al. Daytime urinary incontinence in primary school children: a population-based survey. *J Pediatr* 2000 Dec;137(6):814-8.
<http://www.ncbi.nlm.nih.gov/pubmed/11113838>
7. Franco I. Overactive bladder in children. Part 1: Pathophysiology. *J Urol* 2007 Sep;178(3 Pt 1):761-8; discussion 768.
<http://www.ncbi.nlm.nih.gov/pubmed/17631323>
8. Hellstrom AL, Hanson E, Hansson S, et al. Micturition habits and incontinence in 7-year-old Swedish school entrants. *Eur J Pediatr* 1990 Mar;149(6):434-7.
<http://www.ncbi.nlm.nih.gov/pubmed/2332015>

9. Hoebeke P, Bower W, Combs A, et al. Diagnostic evaluation of children with daytime incontinence. *J Urol* 2010 Feb;183(2):699-703.
<http://www.ncbi.nlm.nih.gov/pubmed/20022025>
10. Akbal C, Genc Y, Burgu B, et al. Dysfunctional voiding and incontinence scoring system: quantitative evaluation of incontinence symptoms in pediatric population. *J Urol* 2005 Mar;173(3):969-73.
<http://www.ncbi.nlm.nih.gov/pubmed/15711352>
11. Farhat W, Bägli DJ, Capolicchio G, et al. The dysfunctional voiding scoring system: quantitative standardization of dysfunctional voiding symptoms in children. *J Urol* 2000 Sep;164(3 Pt 2):1011-5.
<http://www.ncbi.nlm.nih.gov/pubmed/10958730>
12. Chang SJ, Hsieh CH, Yang SS. Constipation is associated with incomplete bladder emptying in healthy children. *NeuroUrol Urodyn* 2012 Jan;31(1):105-8.
<http://www.ncbi.nlm.nih.gov/pubmed/22038844>
13. Hellstrom AL. Urotherapy in children with dysfunctional bladder. *Scand J Urol Nephrol Suppl* 1992;141:106-7. [no abstract available]
<http://www.ncbi.nlm.nih.gov/pubmed/1609245>
14. Vijverberg MA, Elzinga-Plomp A, Messer AP, et al. Bladder rehabilitation, the effect of a cognitive training programme on urge incontinence. *Eur Urol* 1997;31(1):68-72.
<http://www.ncbi.nlm.nih.gov/pubmed/9032538>
15. De Paepe H, Hoebeke P, Renson C, Van Laecke E, et al. Pelvic-floor therapy in girls with recurrent urinary tract infections and dysfunctional voiding. *Br J Urol* 1998 May;81(Suppl 3):109-13.
<http://www.ncbi.nlm.nih.gov/pubmed/9634033>
16. De Paepe H, Renson C, Van Laecke E, et al. Pelvic-floor therapy and toilet training in young children with dysfunctional voiding and obstipation. *BJU Int* 2000 May;85(7):889-93.
<http://www.ncbi.nlm.nih.gov/pubmed/10792172>
17. Bower WF, Yeung CK. A review of non-invasive electro neuromodulation as an intervention for nonneurogenic bladder dysfunction in children. *NeuroUrol Urodyn* 2004;23(1):63-7.
<http://www.ncbi.nlm.nih.gov/pubmed/14694460>
18. Barroso U Jr, Tourinho R, Lordêlo P, et al. Electrical stimulation for lower urinary tract dysfunction in children: a systematic review of the literature. *NeuroUrol Urodyn* 2011 Nov;30(8):1429-36.
<http://www.ncbi.nlm.nih.gov/pubmed/21717502>
19. Lordêlo P, Soares PV, Maciel I, et al. Prospective study of transcutaneous parasacral electrical stimulation for overactive bladder in children: long-term results. *J Urol* 2009 Dec;182(6):2900-4.
<http://www.ncbi.nlm.nih.gov/pubmed/19846164>
20. Nijman RJ, Borgstein NG, Ellsworth P, et al. Tolterodine treatment for children with symptoms of urinary urge incontinence suggestive of detrusor overactivity: results from 2 randomized, placebo controlled trials. *J Urol* 2005 Apr;173(4):1334-9.
<http://www.ncbi.nlm.nih.gov/pubmed/15758796>
21. Marschall-Kehrel D, Feustel C, Persson de Geeter C, et al. Treatment with propiverine in children suffering from nonneurogenic overactive bladder and urinary incontinence: results of a randomized placebo-controlled phase 3 clinical trial. *Eur Urol* 2009 Mar;55(3):729-36.
<http://www.ncbi.nlm.nih.gov/pubmed/18502028>
22. Kramer SA, Rathbun SR, Elkins D, et al. Double-blind placebo controlled study of alpha-adrenergic receptor antagonists (doxazosin) for treatment of voiding dysfunction in the pediatric population. *J Urol* 2005 Jun;173(6):2121-4; discussion 2124.
<http://www.ncbi.nlm.nih.gov/pubmed/15879863>
23. Hoebeke P, De Caestecker K, Vande Walle J, et al. The effect of botulinum-A toxin in incontinent children with therapy resistant overactive detrusor. *J Urol* 2006 Jul;176(1):328-30; discussion 330-1.
<http://www.ncbi.nlm.nih.gov/pubmed/16753434>
24. Groen LA, Hoebeke P, Loret N, et al. Sacral neuromodulation with an implantable pulse generator in children with lower urinary tract symptoms: 15-year experience. *J Urol* 2012 Oct;188(4):1313-7.
<http://www.ncbi.nlm.nih.gov/pubmed/22902022>

11. MONOSYMPTOMATIC ENURESIS

11.1 Background

Enuresis is synonymous to intermittent nocturnal incontinence. It is a frequent symptom in children. With a prevalence of 5-10% at 7 years of age, it is one of the most prevalent conditions in childhood. With a

spontaneous yearly cure rate of 15%, it is considered relatively benign (1,2). Nocturnal enuresis is considered primary when a child has not yet had a prolonged period of being dry. The term “secondary nocturnal enuresis” is used when a child or adult begins wetting again after having stayed dry. In most cases of secondary nocturnal enuresis the causes are either organic or stem from a psychologic problem.

However, 7 out of 100 children wetting the bed at age 7 will take this condition into adulthood. As it is a stressful condition, which puts a high psychological burden on children resulting in low self-esteem, treatment is advised from the age of 6-7 years onwards. Treatment is unnecessary in younger children in whom spontaneous cure is likely. The child’s mental status, family expectations, social issues and cultural background need to be considered before treatment can be started.

11.2 Definition

Enuresis is the condition describing the symptom of incontinence during night. Any wetting during sleep above the age of 5 years is enuresis. However, most importantly, there is a single symptom only. Children with other LUT symptoms and enuresis are said to have **non-monosymptomatic enuresis**. Thorough history-taking, excluding any other daytime symptoms, is mandatory before diagnosing **monosymptomatic enuresis**. Any associated urinary tract symptoms make the condition a ‘**daytime LUT condition**’ (3).

The condition is described as ‘primary’ when the symptom has always existed and the patient has not been dry for a period longer than 6 months. The condition is described as ‘secondary’, when there has been a symptom-free interval of 6 months. Genetically, enuresis is a complex and heterogeneous disorder. Loci have been described on chromosomes 12, 13 and 22 (3).

Three factors play an important pathophysiological role:

- high night-time urine output;
- night-time low bladder capacity or increased detrusor activity;
- arousal disorder.

Due to an imbalance between night-time urine output and night-time bladder capacity, the bladder can become easily full at night and the child will either wake up to empty the bladder or will void during sleep if there is a lack of arousal from sleep (1-3).

11.3 Diagnosis

The diagnosis is obtained by history-taking. In a patient with monosymptomatic enuresis, no further investigations are needed. A voiding diary, which records daytime bladder function and night-time urine output, will help to guide the treatment. An estimate of night-time urine production can be obtained by weighing diapers (nappies) in the morning and adding the volume of the morning void. Measuring the daytime bladder capacity gives an estimate of bladder capacity compared to normal values for age (4).

Ultrasound of the urinary tract is not recommended but, when available, it can be used to exclude underlying pathology.

In most children, bedwetting is a familial problem, with most affected children found to have a history of bedwetting within the family. A urinary dipstick may help differentiate between true enuresis resulting from polyuria due to insipidus diabetes.

11.4 Treatment

Before using alarm treatment or medication, simple therapeutic interventions should be considered.

11.4.1 Supportive treatment measures

Explaining the condition to the child and his parents helps to demystify the problem. Eating and drinking habits should be reviewed, stressing normal fluid intake during the day and reducing fluid intake in the hours before sleep. Keeping a chart depicting wet and dry nights has been shown to be successful.

Counselling, provision of information, positive reinforcement, and increasing (and supporting) motivation of the child should be introduced first. There is a high level of evidence to show that supportive treatment is more successful than doing nothing, although the cure rate is not significantly high. However, supportive therapy as an initial management carries a high grade of recommendation (4).

Supportive measures have limited success when used alone, they should be used in conjunction with other treatment modalities, of which pharmacological and alarm treatment are the two most important.

11.4.2 Alarm treatment

Alarm treatment is the best form for arousal disorder (LE: 1; GR: A). Initial success rates of 80% are realistic, with low relapse rates, especially when night-time diuresis is not too high and bladder capacity is not too low (5).

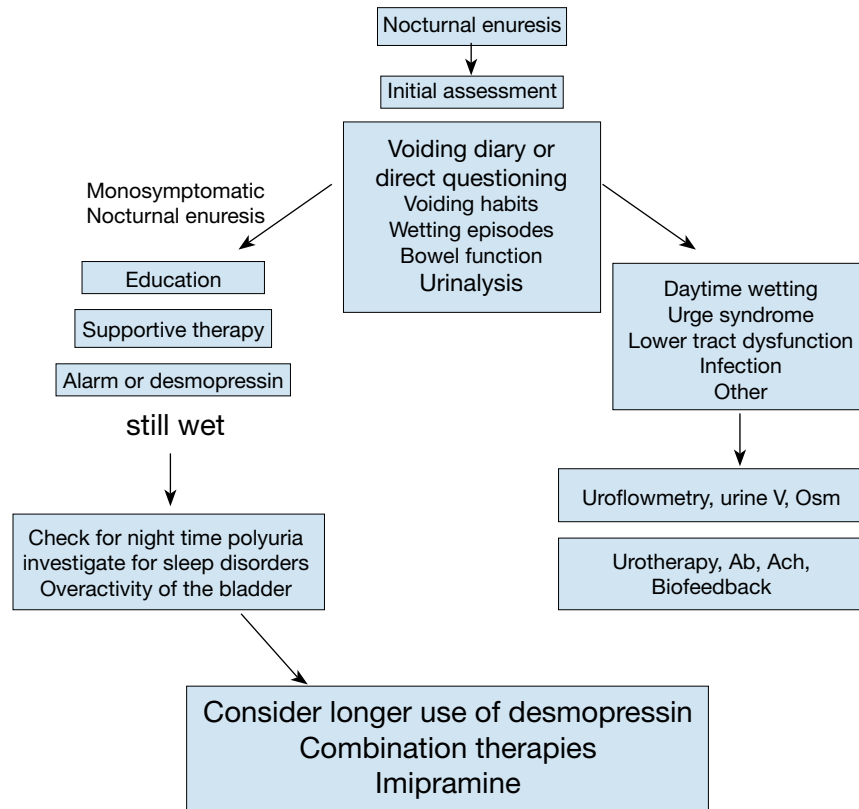
11.4.3 Medication

In the case of high night-time diuresis, success rates of 70% can be obtained with desmopressin (DDAVP), either as tablets, 200–400 µg, or as sublingual desmopressin oral lyophilisate, 120–240 µg. A nasal spray is no longer recommended due to an increased risk of overdose (6,7) (LE: 1; GR: A). However, relapse rates are high after desmopressin discontinuation (4).

In the case of small bladder capacity, treatment with antispasmodics or anticholinergics is possible (4). However, when these medications are necessary, the condition is no longer considered to be monosymptomatic.

Imipramine, which has been popular for treatment of enuresis, achieves only a moderate response rate of 50% and has a high relapse rate. Furthermore, cardiotoxicity and death with overdose are described. Its use should therefore be discouraged (8) (LE: 1;GR: C).

Figure 2: Assessment and treatment of nocturnal enuresis



Guidelines for the treatment of monosymptomatic enuresis	LE	GR
Treatment is unnecessary in younger children (< 5 years of age) in whom spontaneous cure is likely.	2	A
Voiding diaries or questionnaires should be used to exclude daytime symptoms.	2	A
A urine test is indicated to exclude the presence of infection or potential causes such as diabetes insipidus.	2	B
Supportive measures have limited success when used alone; they should be used in conjunction with other treatment modalities, of which pharmacological and alarm treatment are the two most important.	2	B
Alarm treatment is the best treatment for arousal disorder with low relapse rates. There may be family compliance problems.	1	A
For the treatment of night time diuresis, Desmopressin treatment has shown to be effective. The response rate is high around 70% , relapse rates are high.	1	A
The choice of the treatment modality can be made during parental counselling. The parents should be well informed about the problem and advantages and disadvantages of each one of the two treatment modalities should be explained.	4	B

11.5 References

1. Lackgren G, Hjalmas K, van Gool J, et al. Nocturnal enuresis: a suggestion for a European treatment strategy. *Acta Paediatr* 1999 Jun;88(6):679-90.
<http://www.ncbi.nlm.nih.gov/pubmed/10419258>
2. Neveus T, von Gontard A, Hoebeke P, et al. The standardization of terminology of lower urinary tract function in children and adolescents: report from the Standardisation Committee of the International Children's Continence Society. *J Urol* 2006 Jul;176(1):314-24.
<http://www.ncbi.nlm.nih.gov/pubmed/16753432>
3. Neveus T, Lackgren G, Tuvemo T, et al. Enuresis—background and treatment. *Scand J Urol Nephrol Suppl* 2000;206:1-44.
<http://www.ncbi.nlm.nih.gov/pubmed/11196246>
4. Hjalmas K, Arnold T, Bower W, et al. Nocturnal enuresis: an international evidence based management strategy. *J Urol* 2004 Jun;171(6 Pt 2):2545-61. [no abstract available]
<http://www.ncbi.nlm.nih.gov/pubmed/15118418>
5. Glazener CM, Evans JH, Peto RE. Alarm interventions for nocturnal enuresis in children. *Cochrane Database Syst Rev* 2005 Apr;(2):CD002911.
<http://www.ncbi.nlm.nih.gov/pubmed/15846643>
6. Dehoorne JL, Raes AM, van Laecke E, et al. Desmopressin toxicity due to prolonged half-life in 18 patients with nocturnal enuresis. *J Urol* 2006 Aug;176(2):754-7; discussion 757-8.
<http://www.ncbi.nlm.nih.gov/pubmed/16813936>
7. Glazener CMA, Evans JH. Desmopressin for nocturnal enuresis. *Cochrane Database Syst Rev* 2002;(3):CD002112.
<http://www.ncbi.nlm.nih.gov/pubmed/12137645>
8. Glazener CMA, Evans JHC, Peto R. Tricyclic and related drugs for nocturnal enuresis in children. *Cochrane Database Syst Rev* 2000;(2):CD002117.
<http://www.ncbi.nlm.nih.gov/pubmed/12917922>

12. MANAGEMENT OF NEUROGENIC BLADDER IN CHILDREN

12.1 Background

Neurogenic detrusor-sphincter dysfunction (NDSD) can develop as a result of a lesion at any level in the nervous system. This condition contributes to various forms of lower urinary tract dysfunction, which may lead to incontinence, UTIs, VUR, and renal scarring. Surgery may be required to establish adequate bladder drainage. If not managed properly, NDSD can potentially cause renal failure, requiring dialysis or transplantation.

The management of neurogenic bladder sphincter dysfunction in children has undergone major changes over the years. Although nappies (diapers), permanent catheters, external appliances, Crede's manoeuvre and various forms of urinary diversion have been acceptable treatment methods, these are now reserved for only a small number of resistant patients. The introduction of clean intermittent catheterisation (IC) has revolutionised the management of children with neurogenic bladder. Not only has it made conservative management a very successful treatment option, but it has also made surgical creation of continent reservoirs a very effective treatment alternative, with a good outcome for quality of life and kidney protection (1-3).

Neurogenic bladder in children with myelodysplasia presents with various patterns of detrusor-sphincter dysfunction within a wide range of severity. About 15% of neonates with myelodysplasia have no signs of neurourological dysfunction at birth. However, there is a high chance of progressive changes in the dynamics of neurological lesions with time. Even babies with normal neurourological function at birth have a one in three risk of developing either detrusor sphincter dyssynergia or denervation by the time they reach puberty. At birth, the majority of patients have normal upper urinary tracts, but nearly 60% of them develop upper tract deterioration due to infections, bladder changes and reflux (4-7).

As our understanding of urodynamic studies has evolved, it has allowed us to understand the nature and severity of problems and manage these patients in a more rational and individualised manner. Despite the remarkable changes of the last quarter of the 20th century, the main goals of treatment have remained the same, i.e. prevention of urinary tract deterioration and achievement of continence at an appropriate age.

12.2 Definition

The most common presentation is at birth with myelodysplasia. The term myelodysplasia includes a group of developmental anomalies that result from defects in neural tube closure. Lesions may include spina bifida occulta, meningocele, lipomyelomeningocele, or myelomeningocele. Myelomeningocele is by far the most common defect seen and the most detrimental. Traumatic and neoplastic spinal lesions of the cord are less frequent in children. Additionally, different growth rates between the vertebral bodies and the elongating spinal cord can introduce a dynamic factor to the lesion. Scar tissue surrounding the cord at the site of meningocele closure can tether the cord during growth.

In occult myelodysplasia, the lesions are not overt and often occur with no obvious signs of neurological lesion.

In nearly 90% of patients, however, a cutaneous abnormality overlies the lower spine, and this condition can easily be detected by simple inspection of the lower back (8).

Total or partial sacral agenesis is a rare congenital anomaly that involves absence of part or all of one or more sacral vertebrae. This anomaly can be part of the caudal regression syndrome, and must be considered in any child presenting with anorectal malformation (ARM). Patients with cerebral palsy may also present with varying degrees of voiding dysfunction, usually in the form of uninhibited bladder contractions (often due to spasticity of the pelvic floor and sphincter complex) and wetting.

Bladder sphincter dysfunction is poorly correlated with the type and spinal level of the neurological lesion.

12.3 Classification

The purpose of any classification system is to facilitate the understanding and management of the underlying pathology. There are various systems of classification of neurogenic bladder.

Most systems of classification were formulated primarily to describe those types of dysfunction secondary to neurological disease or injury. Such systems are based on the localisation of the neurological lesion and the findings of the neurourological examination. These classifications have been of more value in adults, in whom neurogenic lesions are usually due to trauma and are more readily identifiable.

In children, the spinal level and extent of congenital lesion are poorly correlated with the clinical outcome. Urodynamic and functional classifications have therefore been more practical for defining the extent of the pathology and planning treatment in children.

The bladder and sphincter are two units working in harmony to make a single functional unit. The initial approach should be to evaluate the state of each unit and define the pattern of bladder dysfunction. According to the nature of the neurological deficit, the bladder and sphincter may be in either an overactive or inactive state:

- the bladder may be overactive with increased contractions, and low capacity and compliance, or inactive with no effective contractions;
- the outlet (urethra and sphincter) may be independently overactive causing functional obstruction, or paralysed with no resistance to urinary flow;
- these conditions may present in different combinations.

This is mainly a classification based on urodynamic findings. The understanding of the pathophysiology of disorders is essential to plan a rational treatment plan for each individual patient. In meningomyelocele, most patients will present with hyper-reflexive detrusor and dyssynergic sphincter, which is a dangerous combination as pressure is built up and the upper tract is threatened.

12.4 Urodynamic studies

Urodynamic studies enable the clinician to observe lower urinary tract function and its deviations from normal. Since the treatment plan mainly depends upon a good understanding of the underlying problem in the lower urinary tract, a well-performed urodynamic study is mandatory in the evaluation of each child with neurogenic bladder.

As the bony level often does not correspond with the neurological defect present, and as the effect of the lesion on bladder function cannot be entirely determined by radiographic studies or physical examination, the information gained from a urodynamic study is priceless. A urodynamic study also provides the clinician with information about the response of the vesicourethral unit to therapy, as demonstrated by improvement or deterioration in follow-up.

It is important to determine several urodynamic parameters, including:

- the bladder capacity;
- the intravesical filling pressure;
- the intravesical pressure at the moment of urethral leakage;

- the presence or absence of reflex detrusor activity;
- the competence of the internal and external sphincteric mechanisms;
- the degree of coordination of the detrusor and sphincteric mechanisms;
- the voiding pattern;
- the post-voiding residual urine volume.

12.4.1 **Method of urodynamic study**

There is very little comparative data evaluating the complexity and invasiveness of urodynamic testing for neurogenic bladders in children.

12.4.2 **Uroflowmetry**

As uroflowmetry is the least invasive of all urodynamic tests, it can be used as an initial screening tool. It provides an objective way of assessing the efficiency of voiding, and, together with an ultrasonographic examination, the residual urine volume can also be determined. Unlike in children with non-neurogenic voiding dysfunction, uroflowmetry will rarely be used as a single investigational tool in children with neurogenic bladders, as it does not provide information for bladder storage, yet it may be very practical to monitor emptying in the follow-up. The main limitation of a urodynamic study is the need for the child to be old enough to follow instructions and void on request.

The recording of pelvic floor or abdominal skeletal muscle activity by electromyography (EMG) during uroflowmetry can be used to evaluate coordination between detrusor and the sphincter. As it is a non-invasive test, combined uroflowmetry and EMG may be very useful in evaluating sphincter activity during voiding (9-12) (LE: 3; GR: C).

12.4.3 **Cystometry**

Although moderately invasive and dependent on a cooperative child, cystometry in children provides valuable information regarding detrusor contractility and compliance. The amount of information obtained from each study is related to the degree of interest and care given to the test.

It is important to be aware of the alterations in filling and emptying detrusor pressures as the infusion rates change during cystometry. Slow fill cystometry (filling rate < 10 mL/min) is recommended by the ICCS for use in children (13). However, it has been suggested that the infusion rate should be set according to the child's predicted capacity, based on age and divided by 10 (14).

Several clinical studies using conventional artificial fill cystometry to evaluate neurogenic bladder in children have reported that conventional cystometry provides useful information for diagnosis and follow-up of children with neurogenic bladder (15-20). All the studies were retrospective clinical series and lacked comparison with natural fill cystometry, so that the grade of recommendation for an artificial cystometry in children with neurogenic bladder is not high (LE: 4). Additionally, there is evidence suggesting that natural bladder behaviour is altered during regular artificial filling cystometry (21,22).

However, conventional cystometry in infants is useful for predicting future deterioration. Urodynamic parameters, such as low capacity and compliance and high leak-point pressures, are poor prognostic factors for future deterioration. Resolution of reflux is less likely to happen in such bladders (15,20,22) (LE: 4).

During natural fill cystometry, the bladder is allowed to fill naturally and the bladder and abdominal pressures are recorded using microtransducer catheters. Theoretically, this allows investigation of bladder function in near-physiological conditions. Studies on natural fill cystometry in children report similar results to those of studies done in adults. Natural fill cystometry gives a lower detrusor pressure rise during filling, and lower voided volumes with higher voiding pressures. The incidence of bladder overactivity is higher with natural filling cystometry when compared with conventional artificial filling cystometry (21,23,24).

Although there are only a few studies on natural fill cystometry in children with neurogenic bladder, the results suggest that natural fill cystometry detects new findings compared with diagnoses delivered by conventional cystometry (21) (LE: 3). However, the comparison between natural fill and artificial fill cystometry has not been performed against a gold standard, making it difficult to conclude which study is a true reflection of natural bladder behaviour. Findings in the non-neurogenic adult population have questioned the reliability of natural fill cystometry, as natural fill cystometry has shown a high incidence of bladder overactivity in totally normal asymptomatic volunteers (25).

The main disadvantage of natural fill cystometry is that it is labour-intensive and time-consuming. Moreover, because of the transurethral catheter used during this study, false-positive findings caused by the catheter are possible. Especially in children, the recording of events is difficult and there is an increased risk of artefacts, which makes interpretation of the huge amount of data even more difficult.

Natural fill cystometry remains a new technique in the paediatric population. More data need to be gathered in a standard way before it can be widely accepted (11).

12.5 Management

The medical care of children with myelodysplasia with a neurogenic bladder requires constant observation and adaptation to new problems. In the first years of life, the kidneys are highly susceptible to back-pressure and infection. During this period, the emphasis is on documenting the pattern of NDS, and assessing the potential for functional obstruction and VUR.

12.5.1 Investigations

An abdominal ultrasound obtained as soon as possible after birth will detect hydronephrosis or other upper genitourinary tract pathology. Following ultrasound, a voiding cystourethrogram should be obtained to evaluate the lower urinary tract. Measurement of residual urine during both ultrasound and cystography should also be done. These studies provide a baseline for the appearance of the upper and lower urinary tracts, can facilitate the diagnosis of hydronephrosis or VUR, and can help identify children at risk for upper genitourinary tract deterioration and impairment of renal function.

A urodynamic evaluation can be done after some weeks, and needs to be repeated at regular intervals, in combination with evaluation of the upper tracts (26-28) (LE: 3; GR: B).

12.5.2 Early management with intermittent catheterisation

Overwhelming experience gained over the years with early management of neurogenic bladder in infants has led to a consensus that children do not have upper tract deterioration when managed early with IC and anticholinergic medication. IC should be started soon after birth in all babies, especially in those with signs of possible outlet obstruction (26,29-37) (LE: 2; GR: B).

The early initiation of IC in the newborn period makes it easier for parents to master the procedure and for children to accept it as they grow older (38,39).

Early management results in fewer upper tract changes, but also better bladder protection and lower incontinence rates. It has been suggested that increased bladder pressures due to detrusor sphincter dyssynergia cause secondary changes of the bladder wall. These fibroproliferative changes in the bladder wall may cause further loss of elasticity and compliance, resulting in a small non-compliant bladder with progressively elevated pressures.

Early institution of IC and anticholinergic drugs may prevent this in some patients (2,37,40) (LE: 3). The retrospective evaluation of patients has also shown that significantly fewer augmentations were required in patients with an early start of IC (33,34) (LE: 4).

12.5.3 Medical therapy

At present, oxybutynin, tolterodine, trospium and propiverine are the most frequently used drugs, with oxybutynin being the most studied.

Two different forms of tolterodine have been investigated in children with neurogenic bladder. The extended release formulation of tolterodine has been found to be as efficient as the instant release form, with the advantages of being single dosage and less expensive. Although the clinical outcome is encouraging, the level of evidence is low for anticholinergic medication because there are no controlled studies (40,41-47) (LE: 3; GR: B).

The use of medication to facilitate emptying in children with neurogenic bladder has not been well studied in the literature. A few studies investigating the use of α -adrenergic blockade in children with neurogenic bladder have reported a good response rate, but the studies lacked controls, and long-term follow-up is warranted (48) (LE: 4; GR: C).

12.5.3.1 Botulinum toxin injections

In neurogenic bladders that are refractory to anticholinergics, injection of botulinum toxin into the detrusor muscle is a novel treatment alternative. Initial promising results in adults have initiated its use in children. It has been shown that this treatment has beneficial effects on clinical and urodynamic variables. Complete continence was achieved in 65-87% of patients; in most studies mean maximum detrusor pressure was reduced to at least 40 cmH₂O and bladder compliance was increased to at least 20 cmH₂O/mL. However these findings are limited by the lack of controlled trials and the fact that most studies involved small numbers of patients (49-54).

Botulinum toxin seems to be more effective in bladders with obvious detrusor muscle overactivity, whereas non-compliant bladders without obvious contractions are unlikely to respond (55-60).

The most commonly used dose of botulinum toxin is 10 U/kg with a maximum dose of 200 units. No dose study has been performed in children and there is no evidence regarding the optimal dose. Currently, it is unclear how many times this treatment can be repeated, although repetitive treatment has been found to be safe in adults (61-64).

Injection of botulinum toxin in therapy-resistant bladders appears to be an effective and safe treatment alternative (LE: 3; GR: C). Urethral sphincter botulinum-A toxin injection has been shown to be effective in decreasing urethral resistance and improve voiding. The evidence is still too low to recommend its routine use in decreasing outlet resistance, but it could be considered as an alternative in refractory cases (65-67).

12.5.4 Management of bowel incontinence

Children with neurogenic bladder have disturbances of bowel function as well as urinary function. Bowel incontinence in these children is frequently unpredictable. It is related to the turnover rate of faecal material in the anal area after evacuation, the degree of intactness of sacral cord sensation and motor function, and reflex reactivity of the external anal sphincter (68).

Bowel incontinence is managed most commonly with mild laxatives, such as mineral oil, combined with enemas to facilitate removal of bowel contents. A regular and efficient bowel emptying regimen is often necessary to maintain faecal continence, and may have to be started at a very young age. With antegrade or retrograde enemas, most of these children will have decreased constipation problems and may attain some degree of faecal continence (69-73) (LE: 3).

Biofeedback training programmes to strengthen the external anal sphincter have not been shown to be more effective than a conventional bowel management programme in achieving faecal continence (74). Electrostimulation of the bowel may also offer a variable improvement in some patients (75) (LE: 3; GR: C).

12.5.5 Urinary tract infection

Urinary tract infections are common in children with neurogenic bladders. In the absence of reflux, UTIs should be treated symptomatically. There is strong evidence for not prescribing antibiotics to patients who have bacteriuria but no clinical symptoms. Although bacteriuria is seen in more than half of children on clean IC, patients who are asymptomatic do not need treatment (76-78) (LE: 3). Patients with VUR should usually be placed on prophylactic antibiotics to reduce the incidence of pyelonephritis, which can potentially lead to renal damage (79,80).

12.5.6 Sexuality

Sexuality, while not an issue in childhood, becomes progressively more important as the patient gets older. This issue has historically been overlooked in individuals with myelodysplasia. However, patients with myelodysplasia do have sexual encounters. Studies indicate that at least 15-20% of males are capable of fathering children and 70% of females can conceive and carry a pregnancy to term. It is therefore important to counsel patients about sexual development in early adolescence.

12.5.7 Bladder augmentation

Children with a good response to anticholinergic treatment and an overactive sphincter may be continent between catheterisations. Bladder pressure and development of the upper urinary tract will determine whether additional treatment is necessary.

Therapy-resistant overactivity of the detrusor, or small capacity and poor compliance, will usually need to be treated by bladder augmentation. A simple bladder augmentation using intestine may be carried out if there is any bladder tissue, a competent sphincter and/or bladder neck, and a urethra that can be catheterised.

Stomach is rarely used as an augmenting patch because of the associated complications (81). Ileal or colonic patches are frequently used for augmenting the bladder, with either intestinal segment appearing to be equally useful. Despite some advantages (e.g. avoiding mucus, decreased malignancy rate and fewer complications), alternative urothelium-preserving techniques, such as autoaugmentation and seromuscular cystoplasty, have not proven to be as successful as standard augmentation with intestine (82,83).

A range of applications of engineered bladder tissues are at different stages of development. There have been a few in pre-clinical trials; recent progress suggests that engineered bladder tissues may have an expanded clinical application in the future (84).

12.5.8 Bladder outlet procedures

Children with detrusor overactivity, but with underactive sphincters, will be better for protecting their upper tracts, although they will be severely incontinent. Initial treatment is IC (as it might reduce the degree of incontinence and offers much better control over UTIs) with anticholinergic drugs. At a later age, the outlet resistance will be increased in order to render them continent. No medical treatment available has been validated to increase bladder outlet resistance. Alpha-adrenergic receptor stimulation of the bladder neck has not been very effective (85-90).

When conservative measures fail, surgical procedures need to be considered for maintaining

continence. Although a simple augmentation is sufficient for most low-capacity, high-pressure bladders, augmentation with additional bladder outlet procedures is required when both the bladder and outlet are deficient. Bladder outlet procedures include bladder neck reconstruction or other forms of urethral reconstruction.

Various procedures can be used on the bladder neck to increase resistance, but all of them may complicate transurethral catheterisation. Augmentation with surgical closure of the bladder neck may be required primarily, or as a secondary procedure in certain rare clinical situations. In this situation, a continent stoma will be required. However, most surgeons prefer to leave the bladder neck and urethra patent as a safety precaution.

12.5.9 Continent stoma

Augmentation with an additional continent stoma is utilised primarily after failure of previous bladder outlet surgery. It is also advisable when an inability to catheterise transurethrally is likely. An abdominal wall continent stoma may be particularly beneficial to wheelchair-bound spina bifida patients, who often have difficulty with urethral catheterisation or are dependent on others to catheterise the bladder. For continence with augmentation and an abdominal wall stoma, an adequate bladder outlet mechanism is essential to maintain continence.

12.5.10 Total bladder replacement

Total bladder replacement in anticipation of normal voiding in children is very rare, as there are infrequent indications for a total cystectomy, with preservation of the bladder outlet and a competent urethral sphincter. This type of bladder replacement is much more common in adult urological reconstruction. Any type of major bladder and bladder outlet construction should be performed in centres with sufficient experience of the surgical technique, and with experienced healthcare personnel to carry out post-operative follow-up (91-93).

12.5.11 Lifelong follow-up of neurogenic bladder patients

Neurogenic bladder patients require lifelong supervision, and the monitoring of renal function is extremely important. Periodic investigation of upper tract changes, renal function and bladder status is mandatory.

Repeat urodynamic tests are therefore needed more frequently (every year) in younger children and less frequently in older children. From the urological viewpoint, a repeat urodynamic study is warranted when the patient has a change in symptoms or undergoes any neurosurgical procedure. In the case of any apparent changes in the upper and lower urinary tract, or changes in neurological symptoms, a more detailed examination including urodynamics and spinal magnetic resonance imaging is indicated.

Renal failure can progress slowly or occur with startling speed in these children. Patients who have undergone reconstructive procedures using intestine should be regularly followed up for complications such as infection, stone formation, reservoir rupture, metabolic changes, and malignancy (93).

The risk of malignancy in enteric augmentations has been reported to be higher than expected, and the risk increases with length of follow-up. Malignancy has been found to occur in 0.6-2.8% of patients during median follow-up of 13-21 years (94-99). In a study including 153 patients with a median follow-up time of 28 years (95), malignancy was found in 4.5%. The malignancy seemed to be associated with coexisting carcinogenic stimuli or with the inherent risk present with bladder exstrophy. Although there is poor data on follow-up schemes; after a reasonable time of follow up (f.i: 10 years), an annual diagnostic work-up including cystoscopy should be considered.

12.6 References

1. Bauer SB. The management of the myelodysplastic child: a paradigm shift. *BJU Int* 2003 Oct;92(Suppl 1):23-8. [no abstract available]
<http://www.ncbi.nlm.nih.gov/pubmed/12969005>
2. Retik AB, Perlmutter AD, Gross RE. Cutaneous ureteroileostomy in children. *N Eng J Med* 1967 Aug;277(5):217-22. [no abstract available]
<http://www.ncbi.nlm.nih.gov/pubmed/4226464>
3. Lapedes J, Diokno AC, Silber SJ, et al. Clean, intermittent self-catheterization in the treatment of urinary tract disease. 1972. *J Urol* 2002 Feb;167(2 Pt 2):1131-3; discussion 1134.
<http://www.ncbi.nlm.nih.gov/pubmed/11905887>
4. Bauer SB. The management of spina bifida from birth onwards. In: Whitaker RH, Woodard JR, eds. *Paediatric urology*. London: Butterworths, 1985, pp. 87-112.
5. Bauer SB. Early evaluation and management of children with spina bifida. In: King LR (ed). *Urologic surgery in neonates and young infants*. Philadelphia: WB Saunders, 1988, pp. 252-264.

6. Wilcock AR, Emery JL. Deformities of the renal tract in children with meningomyelocele and hydrocephalus, compared with those of children showing no such deformities. *Br J Urol* 1970 Apr;42(2):152-7. [no abstract available]
<http://www.ncbi.nlm.nih.gov/pubmed/5420153>
7. Hunt GM, Whitaker RH. The pattern of congenital renal anomalies associated with neural-tube defects. *Dev Med Child Neurol* 1987 Feb;29(1):91-5.
<http://www.ncbi.nlm.nih.gov/pubmed/3556803>
8. Pierre-Kahn A, Zerah M, Renier D, et al. Congenital lumbosacral lipomas. *Childs Nerv Syst*. 1997;13(6):298-334; discussion 335.
<http://www.ncbi.nlm.nih.gov/pubmed/9272285>
9. Aoki H, Adachi M, Banya Y, et al. [Evaluation of neurogenic bladder in patients with spinal cord injury using a CMG.EMG study and CMG.UFM.EMG study.] *Hinyokika Kyo* 1985 Jun;31(6):937-48. [Article in Japanese]
<http://www.ncbi.nlm.nih.gov/pubmed/4061211>
10. Casado JS, Virseda Chamorro M, Leva Vallejo M, Fernandez Lucas C, Aristizabal Agudelo JM, de la Fuente Trabado M. [Urodynamic assessment of the voiding phase in childhood.] *Arch Esp Urol* 2002 Mar;55(2):177-89. [Article in Spanish]
<http://www.ncbi.nlm.nih.gov/pubmed/12014050>
11. Wen JG, Yeung CK, Djurhuus JC. Cystometry techniques in female infants and children. *Int Urogynecol J Pelvic Floor Dysfunct* 2000;11(2):103-12.
<http://www.ncbi.nlm.nih.gov/pubmed/10805268>
12. Bradley CS, Smith KE, Kreder KJ. Urodynamic evaluation of the bladder and pelvic floor. *Gastroenterol Clin North Am* 2008 Sep;37(3):539-52.
<http://www.ncbi.nlm.nih.gov/pubmed/18793995>
13. Norgaard JP, van Gool JD, Hjalmas K, et al. Standardization and definitions in lower urinary tract dysfunction in children. International Children's Continence Society. *Br J Urol* 1998 May;81(Suppl 3):1-16. [no abstract available]
<http://www.ncbi.nlm.nih.gov/pubmed/9634012>
14. Bauer SB. Pediatric urodynamics: lower tract. In: O'Donnell B, Koff SA, eds. *Pediatric urology*. Oxford: Butterworth-Heinemann, 1998, pp. 125-151.
15. Tanikaze S, Sugita Y. [Cystometric examination for neurogenic bladder of neonates and infants.] *Hinyokika Kyo* 1991 Nov;37(11):1403-5. [Article in Japanese]
<http://www.ncbi.nlm.nih.gov/pubmed/1767767>
16. Zoller G, Schoner W, Ringert RH. Pre-and postoperative urodynamic findings in children with tethered spinal cord syndrome. *Eur Urol* 1991;19(2):139-41.
<http://www.ncbi.nlm.nih.gov/pubmed/2022217>
17. Ghoniem GM, Roach MB, Lewis VH, et al. The value of leak pressure and bladder compliance in the urodynamic evaluation of meningomyelocele patients. *J Urol* 1990 Dec;144(6):1440-2.
<http://www.ncbi.nlm.nih.gov/pubmed/2231938>
18. Ghoniem GM, Shoukry MS, Hassouna ME. Detrusor properties in myelomeningocele patients: in vitro study. *J Urol* 1998 Jun;159(6):2193-6.
<http://www.ncbi.nlm.nih.gov/pubmed/9598568>
19. Palmer LS, Richards I, Kaplan WE. Age related bladder capacity and bladder capacity growth in children with myelomeningocele. *J Urol* 1997 Sep;158(3 Pt 2):1261-4.
<http://www.ncbi.nlm.nih.gov/pubmed/9258190>
20. Agarwal SK, McLorie GA, Grewal D, et al. Urodynamic correlates of resolution of reflux in meningomyelocele patients. *J Urol* 1997 Aug;158 (3 Pt 2):580-2.
<http://www.ncbi.nlm.nih.gov/pubmed/9224367>
21. Zermann DH, Lindner H, Huschke T, et al. Diagnostic value of natural fill cystometry in neurogenic bladder in children. *Eur Urol* 1997;32(2):223-8.
<http://www.ncbi.nlm.nih.gov/pubmed/9286658>
22. Webb RJ, Griffiths CJ, Ramsden PD, et al. Measurement of voiding pressures on ambulatory monitoring: comparison with conventional cystometry. *Br J Urol* 1990 Feb;65(2):152-4.
<http://www.ncbi.nlm.nih.gov/pubmed/2317646>
23. McLnerney PD, Vanner TF, Harris SA, et al. Ambulatory urodynamics. *Br J Urol* 1991 Mar;67(3):272-4.
<http://www.ncbi.nlm.nih.gov/pubmed/2021814>
24. Yeung CK, Godley ML, Duffy PG, et al. Natural filling cystometry in infants and children. *Br J Urol* 1995 Apr;75(4):531-7.
<http://www.ncbi.nlm.nih.gov/pubmed/7788266>

25. Swithinbank LV, James M, Shepherd A, et al. Role of ambulatory urodynamic monitoring in clinical urological practice. *Neurourol Urodyn* 1999;18(3):215-22.
<http://www.ncbi.nlm.nih.gov/pubmed/10338442>
26. McGuire EJ, Woodside JR, Borden TA, et al. Prognostic value of urodynamic testing in myelodysplastic patients. 1981. *J Urol* 2002 Feb;167(2 Pt 2):1049-53. [no abstract available]
<http://www.ncbi.nlm.nih.gov/pubmed/11905876>
27. Sillen U, Hansson E, Hermansson G, et al. Development of the urodynamic pattern in infants with myelomeningocele. *Br J Urol* 1996 Oct;78(4):596-601.
<http://www.ncbi.nlm.nih.gov/pubmed/8944517>
28. Tarcan T, Bauer S, Olmedo E, et al. Long-term follow-up of newborns with myelodysplasia and normal urodynamic findings: is follow-up necessary? *J Urol* 2001 Feb;165(2):564-7.
<http://www.ncbi.nlm.nih.gov/pubmed/11176436>
29. Kasabian NG, Bauer SB, Dyro FM, et al. The prophylactic value of clean intermittent catheterization and anticholinergic medication in newborns and infants with myelodysplasia at risk of developing urinary tract deterioration. *Am J Dis Child* 1992 Jul;146(7):840-3.
<http://www.ncbi.nlm.nih.gov/pubmed/1496955>
30. Wang SC, McGuire EJ, Bloom DA. Urethral dilatation in the management of urological complications of myelodysplasia. *J Urol* 1989 Oct;142(4):1054-5.
<http://www.ncbi.nlm.nih.gov/pubmed/2795730>
31. Lin-Dyken DC, Wolraich ML, Hawtrey CE, et al. Follow-up of clean intermittent catheterization for children with neurogenic bladders. *Urology* 1992;40(6):525-9.
<http://www.ncbi.nlm.nih.gov/pubmed/1466106>
32. Kaufman AM, Ritchey ML, Roberts AC, et al. Decreased bladder compliance in patients with myelomeningocele treated with radiological observation. *J Urol* 1996 Dec;156(6):2031-3.
<http://www.ncbi.nlm.nih.gov/pubmed/8965337>
33. Wu HY, Baskin LS, Kogan BA. Neurogenic bladder dysfunction due to myelomeningocele: neonatal versus childhood treatment. *J Urol* 1997 Jun;157(6):2295-7.
<http://www.ncbi.nlm.nih.gov/pubmed/9146656>
34. Kaefer M, Pabby A, Kelly M, et al. Improved bladder function after prophylactic treatment of the high risk neurogenic bladder in newborns with myelomeningocele. *J Urol* 1999 Sep;162 (3 Pt 2):1068-71.
<http://www.ncbi.nlm.nih.gov/pubmed/10458433>
35. van Gool JD, Dik P, de Jong TP. Bladder-sphincter dysfunction in myelomeningocele. *Eur J Pediatr* 2001 Jul;160(7):414-20.
<http://www.ncbi.nlm.nih.gov/pubmed/11475578>
36. Bauer SB. The argument for early assessment and treatment of infants with spina bifida. *Dialogues in Pediatric Urology* 2000;23:2-3.
37. Park JM. Early reduction of mechanical load of the bladder improves compliance: experimental and clinical observations. *Dialogues in Pediatric Urology* 2000;23:6-7.
38. Lindehall B, Moller A, Hjalmas K, et al. Long-term intermittent catheterization: the experience of teenagers and young adults with myelomeningocele. *J Urol* 1994 Jul;152(1):187-9.
<http://www.ncbi.nlm.nih.gov/pubmed/8201663>
39. Joseph DB, Bauer SB, Colodny AH, et al. Clean intermittent catheterization in infants with neurogenic bladder. *Pediatrics* 1989 Jul;84(1):72-82.
<http://www.ncbi.nlm.nih.gov/pubmed/2740179>
40. Baskin LS, Kogan BA, Benard F. Treatment of infants with neurogenic bladder dysfunction using anticholinergic drugs and intermittent catheterization. *Br J Urol* 1990 Nov;66(5):532-4.
<http://www.ncbi.nlm.nih.gov/pubmed/2249125>
41. Connor JP, Betrus G, Fleming P, et al. Early cystometrograms can predict the response to intravesical instillation of oxybutynin chloride in myelomeningocele patients. *J Urol* 1994 Apr;151(4):1045-7.
<http://www.ncbi.nlm.nih.gov/pubmed/8126787>
42. Goessel C, Knispel HH, Fiedler U, et al. Urodynamic effects of oral oxybutynin chloride in children with myelomeningocele and detrusor hyperreflexia. *Urology* 1998 Jan;51(1):94-8.
<http://www.ncbi.nlm.nih.gov/pubmed/9457296>
43. Haferkamp A, Staehler G, Gerner HJ, et al. Dosage escalation of intravesical oxybutynin in the treatment of neurogenic bladder patients. *Spinal Cord* 2000 Apr;38(4):250-4.
<http://www.ncbi.nlm.nih.gov/pubmed/10822396>
44. Ferrara P, D'Aleo CM, Tarquini E, et al. Side-effects of oral or intravesical oxybutynin chloride in children with spina bifida. *BJU Int* 2001 May;87(7):674-8.
<http://www.ncbi.nlm.nih.gov/pubmed/11350411>

45. Ellsworth PI, Borgstein NG, Nijman RJ, et al. Use of tolterodine in children with neurogenic detrusor overactivity: relationship between dose and urodynamic response. *J Urol* 2005 Oct;174(4Pt2):1647-51. <http://www.ncbi.nlm.nih.gov/pubmed/16148673>
46. Mahanta K, Medhi B, Kaur B, et al. Comparative efficacy and safety of extended-release and instant-release tolterodine in children with neural tube defects having cystometric abnormalities. *J Pediatr Urol* 2008 Apr;4(2):118-23. <http://www.ncbi.nlm.nih.gov/pubmed/18631906>
47. Franco I. Overactive bladder in children. Part 2: Management. *J Urol* 2007 Sep;178(3Pt1):769-74; discussion 774. <http://www.ncbi.nlm.nih.gov/pubmed/17631332>
48. Austin PF, Homsy YL, Masel JL, et al. Alpha-adrenergic blockade in children with neuropathic and nonneuropathic voiding dysfunction. *J Urol* 1999 Sep;162(3 Pt 2):1064-7. <http://www.ncbi.nlm.nih.gov/pubmed/10458432>
49. Schulte-Baukloh H, Knispel HH, Stolze T, et al. Repeated botulinum-A toxin injections in treatment of children with neurogenic detrusor overactivity. *Urology* 2005 Oct;66(4):865-70; discussion 870. <http://www.ncbi.nlm.nih.gov/pubmed/16230156>
50. Game X, Mouracade P, Chartier-Kastler E, et al. Botulinum toxin-A (Botox) intradetrusor injections in children with neurogenic detrusor overactivity/neurogenic overactive bladder: A systematic literature review. *J Pediatr Urol* 2009 Jun;5(3):156-64. <http://www.ncbi.nlm.nih.gov/pubmed/19264554>
51. Schulte-Baukloh H, Michael T, Stürzebecher B, et al. Botulinum-A Toxin Detrusor Injection as a Novel Approach in the Treatment of Bladder Spasticity in Children with Neurogenic Bladder. *Eur Urol* 2003 Jul;44(1):139-43. <http://www.ncbi.nlm.nih.gov/pubmed/12814690>
52. Hoebeke P, De Caestecker K, Vande Walle J, et al. The effect of botulinum-A toxin in incontinent children with therapy resistant overactive detrusor. *J Urol* 2006 Jul;176(1):328-30. <http://www.ncbi.nlm.nih.gov/pubmed/16753434>
53. Mangera A, Andersson KE, Apostolidis A, et al. Contemporary Management of Lower Urinary Tract Disease With Botulinum Toxin A: A Systematic Review of Botox (OnabotulinumtoxinA) and Dysport (AbobotulinumtoxinA). *Eur Urol* 2011 Oct;60(4):784-95. <http://www.ncbi.nlm.nih.gov/pubmed/21782318>
54. Deshpande AV, Sampang R, Smith GHH. Study of Botulinum Toxin A in Neurogenic Bladder Due to Spina Bifida in Children. *ANZ J Surg* 2010 Apr;80(4):250-3. <http://www.ncbi.nlm.nih.gov/pubmed/20575951>
55. Smith CP, Somogyi GT, Chancellor MB. Emerging role of botulinum toxin in the treatment of neurogenic and non-neurogenic voiding dysfunction. *Curr Urol Rep* 2002 Oct;3(5):382-7. <http://www.ncbi.nlm.nih.gov/pubmed/12354347>
56. Leippold T, Reitz A, Schurch B. Botulinum toxin as a new therapy option for voiding disorders: current state of the art. *Eur Urol* 2003 Aug;44(2):165-74. <http://www.ncbi.nlm.nih.gov/pubmed/12875934>
57. Schulte-Baukloh H, Knispel HH, Michael T. Botulinum-A toxin in the treatment of neurogenic bladder in children. *Paediatrics* 2002 Aug;110(2 Pt 1):420-1. [no abstract available] <http://www.ncbi.nlm.nih.gov/pubmed/12165609>
58. Lusuuardi L, Nader A, Koen M, et al. [Minimally invasive, safe treatment of the neurogenic bladder with botulinum-A-toxin in children with myelomeningocele.] *Aktuelle Urol* 2004 Feb;35(1):49-53. [Article in German] <http://www.ncbi.nlm.nih.gov/pubmed/14997415>
59. Schröder A, Thüroff JW. New strategies for medical management of overactive bladder in children. *Curr Opin Urol* 2010 Jul;20(4):313-7. <http://www.ncbi.nlm.nih.gov/pubmed/21475074>
60. Schurcha B, Corcos J. Botulinum toxin injections for paediatric incontinence. *Curr Opin Urol* 2005 Jul;15(4):264-7. <http://www.ncbi.nlm.nih.gov/pubmed/15928517>
61. Hoebeke P, De Caestecker K, Vande Walle J, et al. The effect of botulinum-A toxin in incontinent children with therapy resistant overactive detrusor. *J Urol* 2006 Jul;176(1):328-30. <http://www.ncbi.nlm.nih.gov/pubmed/16753434>
62. Kajbafzadeh AM, Moosavi S, Tajik P, et al. Intravesical injection of botulinum toxin type A: management of neuropathic bladder and bowel dysfunction in children with myelomeningocele. *Urology* 2006 Nov;68(5):1091-6. <http://www.ncbi.nlm.nih.gov/pubmed/17113899>

63. Akbar M, Abel R, Seyler TM, et al. Repeated botulinum-A toxin injections in the treatment of myelodysplastic children and patients with spinal cord injuries with neurogenic bladder dysfunction. *BJU Int* 2007 Sep;100(3):639-45.
<http://www.ncbi.nlm.nih.gov/pubmed/17532858>
64. DasGupta R, Murphy FL. Botulinum toxin in paediatric urology: a systematic literature review. *Pediatr Surg Int* 2009 Jan;25(1):19-23.
<http://www.ncbi.nlm.nih.gov/pubmed/18953547>
65. Mokhless I, Gaafar S, Fouda K, et al. Botulinum A toxin urethral sphincter injection in children with nonneurogenic neurogenic bladder. *J Urol* 2006 Oct;176(4Pt2):1767-70.
<http://www.ncbi.nlm.nih.gov/pubmed/16945643>
66. Mokhless I, Gaafar S, Fouda K, et al. Botulinum A toxin urethral sphincter injection in children with nonneurogenic neurogenic bladder. *J Urol* 2006 Oct;176(4 Pt 2):1767-70.
<http://www.ncbi.nlm.nih.gov/pubmed/16945643>
67. Franco I, Landau-Dyer L, Isom-Batz G, et al. The use of botulinum toxin A injection for the management of external sphincter dyssynergia in neurologically normal children. *J Urol* 2007 Oct;178(4 Pt 2):1775-9.
<http://www.ncbi.nlm.nih.gov/pubmed/17707430>
68. Younoszai MK. Stooling problems in patients with myelomeningocele. *South Med J* 1992 Jul;85(7):718-24.
<http://www.ncbi.nlm.nih.gov/pubmed/1631686>
69. Squire R, Kiely EM, Carr B, Ransley PG, Duffy PG. The clinical application of the Malone antegrade colonic enema. *J Pediatr Surg* 1993 Aug;28(8):1012-5.
<http://www.ncbi.nlm.nih.gov/pubmed/8229586>
70. Whitehead WE, Wald A, Norton NJ. Treatment options for fecal incontinence. *Dis Colon Rectum* 2001 Jan;44(1):131-42 ; discussion 142-4.
<http://www.ncbi.nlm.nih.gov/pubmed/11805574>
71. Krogh K, Kvitzau B, Jorgensen TM, et al. [Treatment of anal incontinence and constipation with transanal irrigation.] *Ugeskr Laeger* 1999 Jan;161(3):253-6. [Article in Danish]
<http://www.ncbi.nlm.nih.gov/pubmed/10025223>
72. Van Savage JG, Yohannes P. Laparoscopic antegrade continence enema in situ appendix procedure for refractory constipation and overflow fecal incontinence in children with spina bifida. *J Urol* 2000 Sep;164(3 Pt 2):1084-7.
<http://www.ncbi.nlm.nih.gov/pubmed/10958747>
73. Aksnes G, Diseth TH, Helseth A, et al. Appendicostomy for antegrade enema: effects on somatic and psychosocial functioning in children with myelomeningocele. *Pediatrics* 2002 Mar;109(3):484-9.
<http://www.ncbi.nlm.nih.gov/pubmed/11875145>
74. Loening-Baucke V, Desch L, Wolraich M. Biofeedback training for patients with myelomeningocele and fecal incontinence. *Dev Med Child Neurol* 1988 Dec;30(6):781-90.
<http://www.ncbi.nlm.nih.gov/pubmed/3234607>
75. Marshall DF, Boston VE. Altered bladder and bowel function following cutaneous electrical field stimulation in children with spina bifida-interim results of a randomized double-blind placebocontrolled trial. *Eur J Pediatr Surg* 1997 Dec;7(Suppl 1):41-3.
<http://www.ncbi.nlm.nih.gov/pubmed/9497117>
76. Hansson S, Caugant D, Jodal U, et al. Untreated asymptomatic bacteriuria in girls: I-Stability of urinary isolates. *BMJ* 1989 Apr;298(6677):853-5.
<http://www.ncbi.nlm.nih.gov/pubmed/2497822>
77. Hansson S, Jodal U, Lincoln K, et al. Untreated asymptomatic bacteriuria in girls: II - Effect of phenoxymethylpenicillin and erythromycin given for intercurrent infections. *BMJ* 1989 Apr;298(6677):856-9.
<http://www.ncbi.nlm.nih.gov/pubmed/2497823>
78. Hansson S, Jodal U, Noren L, et al. Untreated bacteriuria in asymptomatic girls with renal scarring. *Pediatrics* 1989 Dec;84(6):964-8.
<http://www.ncbi.nlm.nih.gov/pubmed/2587151>
79. Johnson HW, Anderson JD, Chambers GK, et al. A short-term study of nitrofurantoin prophylaxis in children managed with clean intermittent catheterization. *Pediatrics* 1994 May;93(5):752-5.
<http://www.ncbi.nlm.nih.gov/pubmed/8165073>
80. Schlager TA, Anderson S, Trudell J, et al. Nitrofurantoin prophylaxis for bacteriuria and urinary tract infection in children with neurogenic bladder on intermittent catheterization. *J Pediatr* 1998 Apr;132(4):704-8.
<http://www.ncbi.nlm.nih.gov/pubmed/9580774>

81. Nguyen DH, Mitchell ME. Gastric bladder reconstruction. *Urol Clin North Am* 1991 Nov;18(4):649-57.
<http://www.ncbi.nlm.nih.gov/pubmed/1949398>
82. Duel BP, Gonzalez R, Barthold JS. Alternative techniques for augmentation cystoplasty. *J Urol* 1998 Mar;159(3):998-1005.
<http://www.ncbi.nlm.nih.gov/pubmed/9474216>
83. Bandi G, Al-Omar O, McLorie GA. Comparison of traditional enterocystoplasty and seromuscular colocolocystoplasty lined with urothelium. *J Pediatr Urol* 2007 Dec;3(6):484-9.
<http://www.ncbi.nlm.nih.gov/pubmed/18947800>
84. Atala A, Bauer SB, Soker S, et al. Tissue-engineered autologous bladders for patients needing cystoplasty. *Lancet* 2006 Apr;367(9518):1241-6.
<http://www.ncbi.nlm.nih.gov/pubmed/16631879>
85. Naglo AS. Continence training of children with neurogenic bladder and detrusor hyperactivity: effect of atropine. *Scan J Urol Nephrol* 1982;16(3):211-5.
<http://www.ncbi.nlm.nih.gov/pubmed/7163785>
86. Austin PF, Westney OL, Leng WW, et al. Advantages of rectus fascial slings for urinary incontinence in children with neuropathic bladders. *J Urol* 2001 Jun;165(6 Pt 2):2369-71.
<http://www.ncbi.nlm.nih.gov/pubmed/11398778>
87. Guys JM, Fakhro A, Louis-Borrione C, et al. Endoscopic treatment of urinary incontinence: long-term evaluation of the results. *J Urol* 2001 Jun;165(6 Pt 2):2389-91.
<http://www.ncbi.nlm.nih.gov/pubmed/11371983>
88. Kassouf W, Capolicchio G, Bernardinucci G, et al. Collagen injection for treatment of urinary incontinence in children. *J Urol* 2001 May;165(5):1666-8.
<http://www.ncbi.nlm.nih.gov/pubmed/11342951>
89. Kryger JV, Levenson G, Gonzalez R. Long-term results of artificial urinary sphincters in children are independent of age at implantation. *J Urol* 2001 Jun;165(6 Pt 2):2377-9.
<http://www.ncbi.nlm.nih.gov/pubmed/11371981>
90. Holmes NM, Kogan BA, Baskin LS. Placement of artificial urinary sphincter in children and simultaneous gastrocystoplasty. *J Urol* 2001 Jun;165(6 Pt 2):2366-8.
<http://www.ncbi.nlm.nih.gov/pubmed/11371944>
91. Mitchell ME, Piser JA. Intestinocystoplasty and total bladder replacement in children and young adults: follow up in 129 cases. *J Urol* 1987 Sep;138(3):579-84.
<http://www.ncbi.nlm.nih.gov/pubmed/3625861>
92. Shekarriz B, Upadhyay J, Demirbilek S, et al. Surgical complications of bladder augmentation: comparison between various enterocystoplasties in 133 patients. *Urology* 2000 Jan;55(1):123-8.
<http://www.ncbi.nlm.nih.gov/pubmed/10654908>
93. Medel R, Ruarte AC, Herrera M, et al. Urinary continence outcome after augmentation ileocystoplasty as a single surgical procedure in patients with myelodysplasia. *J Urol* 2002 Oct;168(4 Pt 2):1849-52.
<http://www.ncbi.nlm.nih.gov/pubmed/12352374>
94. Sung MT, Zhang S, Lopez-Betran A, et al. Urothelial carcinoma following augmentation cystoplasty: an aggressive variant with distinct clinicopathological characteristics and molecular genetic alterations. *Histopathology* 2009 Aug;55(2):161-73.
<http://www.ncbi.nlm.nih.gov/pubmed/19694823>
95. Husmann DA, Rathbun SR. Long-term follow up of enteric bladder augmentations: The risk for malignancy. *J Pediatr Urol* 2008 Oct;4(5):381-5.
<http://www.ncbi.nlm.nih.gov/pubmed/18653384>
96. Balachandra B, Swanson PE, Upton MP, et al. Adenocarcinoma arising in a gastrocystoplasty. *J Clin Pathol* 2007 Jan;60(1):85-7.
<http://www.ncbi.nlm.nih.gov/pubmed/17213351>
97. Vemulakonda VM, Lendvay TS, Shnorhavorian M, et al. Metastatic adenocarcinoma after augmentation gastrocystoplasty. *J Urol* 2008 Mar;179(3):1094-6.
<http://www.ncbi.nlm.nih.gov/pubmed/18206936>
98. Castellan M, Gosalbez R, Perez-Brayfield M, et al. Tumor in bladder reservoir after gastrocystoplasty. *J Urol* 2007 Oct;178(4 Pt 2):1771-4.
<http://www.ncbi.nlm.nih.gov/pubmed/17707009>
99. Soergel TM, Cain MP, Misseri R, et al. Transitional cell carcinoma of the bladder following augmentation cystoplasty for the neuropathic bladder. *J Urol* 2004 Oct;172(4 Pt 2):1649-51.
<http://www.ncbi.nlm.nih.gov/pubmed/15371782>

13. DILATATION OF THE UPPER URINARY TRACT (URETEROPELVIC JUNCTION AND URETEROVESICAL JUNCTION OBSTRUCTION)

13.1 Background

Dilatation of the upper urinary tract remains a significant clinical challenge in deciding which patient will benefit from treatment.

Ureteropelvic junction (UPJ) obstruction is defined as impaired urine flow from the pelvis into the proximal ureter with subsequent dilatation of the collecting system and the potential to damage the kidney. It is the most common cause of neonatal hydronephrosis (1). It has an overall incidence of 1:1500 and a ratio of males to females of 2:1 in newborns.

Ureterovesical junction (UVJ) obstruction is an obstructive condition of the distal ureter as it enters the bladder, commonly called a primary obstructive megaureter. Megaureters are the second most likely cause of neonatal hydronephrosis. They occur more often in males and are more likely to occur on the left side (2).

It can be very difficult to define 'obstruction' as there is no clear division between 'obstructed' and 'non-obstructed' urinary tracts. Currently, the most popular definition is that an obstruction represents any restriction to urinary outflow that, if left untreated, will cause progressive renal deterioration (3).

13.2 Diagnosis

The widespread use of ultrasonography during pregnancy has resulted in a higher detection rate for antenatal hydronephrosis (4). The challenge in the management of dilated upper urinary tracts is to decide which child should be observed, which child should be managed medically, and which child requires surgical intervention. Despite the wide range of diagnostic tests, there is no single test that can accurately distinguish obstructive from non-obstructive cases (Figure 1).

13.2.1 Antenatal ultrasound

Usually between the 16th and 18th weeks of pregnancy, the kidneys are visualised routinely, when almost all amniotic fluid consists of urine. The most sensitive time for foetal urinary tract evaluation is the 28th week. If dilatation is detected, ultrasound should focus on:

- laterality, severity of dilatation, and echogenicity of the kidneys;
- hydronephrosis or hydro-ureteronephrosis;
- bladder volume and bladder emptying;
- sex of the child;
- amniotic fluid volume (5).

13.2.2 Postnatal ultrasound

Since transitory neonatal dehydration lasts about 48 hours after birth, imaging should be performed following this period of postnatal oliguria. However, in severe cases (bilateral dilatation, solitary kidney, oligohydramnios), immediate postnatal sonography is recommended (6).

Ultrasound should assess the anteroposterior diameter of the renal pelvis, calyceal dilatation, kidney size, thickness of the parenchyma, cortical echogenicity, ureters, bladder wall and residual urine.

13.2.3 Voiding cystourethrogram (VCUG)

In newborns with identified upper urinary tract dilatation, the primary or important associated factors that must be detected include:

- vesicoureteral reflux (found in up to 25% of affected children) (7);
- urethral valves;
- ureteroceles;
- diverticula;
- neurogenic bladder.

Conventional VCUG is the method of choice for primary diagnostic procedures (8).

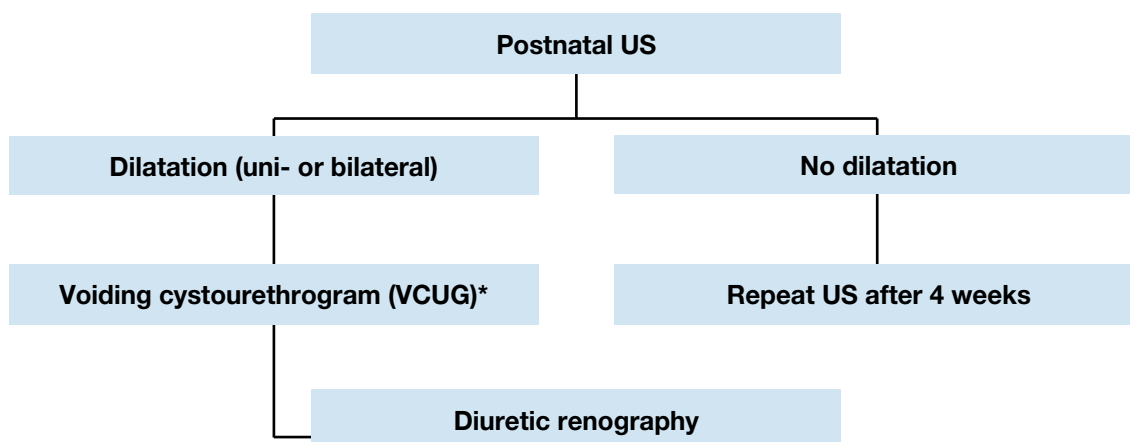
13.2.4 Diuretic renography

Diuretic renography is the most commonly used diagnostic tool to detect the severity and functional significance of problems with urine transport. ^{99m}Tc-MAG3 is the radionuclide of choice. It is important to perform the study under standardised circumstances (hydration, transurethral catheter) between the fourth and sixth weeks of life (9).

Oral fluid intake is encouraged prior to the examination. At 15 minutes before the injection of the

radionuclide, it is mandatory to administer normal saline intravenous infusion at a rate of 15 mL/kg over 30 minutes, with a subsequent maintenance rate of 4 mL/kg/h throughout the whole time of the investigation (10). The recommended dose of furosemide is 1 mg/kg for infants during the first year of life, while 0.5 mg/kg should be given to children aged 1 to 16 years, up to a maximum dose of 40 mg.

Figure 3: Diagnostic algorithm for dilatation of the upper urinary tract



* A diagnostic work-up including VCUG must be discussed with the parents, as it is possible that, even if a reflux is detected, it may have absolutely no clinical impact. However, it should be borne in mind that reflux has been detected in up to 25% of cases of prenatally detected and postnatally confirmed hydronephrosis (7).

13.3 Treatment

13.3.1 Prenatal management

Counselling the parents of an affected child is one of the most important aspects of care. The prognosis is hopeful for a hydronephrotic kidney, even if it is severely affected, as it may still be capable of meaningful renal function. In contrast, a severely hypoplastic and dysplastic kidney has a much more hopeless outlook.

It is important to be able to tell the parents exactly when they will have a definitive diagnosis for their child and what this diagnosis will mean. In some cases, however, it will be immediately obvious that the child is severely affected; there will be evidence of massive bilateral dilatation, bilateral hypoplastic dysplasia, progressive bilateral dilatation with oligohydramnios, and pulmonary hypoplasia.

Intrauterine intervention is rarely indicated and should only be performed in well-experienced centres (11).

13.3.2 UPJ obstruction

It is most important that management decisions are made on the basis of serial investigations that have used the same technique and have been performed by the same institution under standardised circumstances.

Symptomatic obstruction (recurrent flank pain, urinary tract infection) requires surgical correction using a pyeloplasty, according to the standardized open technique of Hynes and Anderson (12). In experienced hands, laparoscopic or retroperitoneoscopic techniques and robot-assisted techniques have the same success rates as standard open procedures. In asymptomatic cases, conservative follow-up is the treatment of choice.

Indications for surgical intervention comprise impaired split renal function (less than 40%), a decrease of split renal function of more than 10% in subsequent studies, increased anteroposterior diameter on the ultrasound, and grade III and IV dilatation as defined by the Society for Fetal Urology (13).

13.3.3 Megaureter

The treatment options of secondary megaureters are reviewed in the Chapter on 'Reflux & Valves', Section 14.4).

13.3.3.1 Conservative management

If a functional study reveals and confirms adequate ureteral drainage, conservative management is the best option. Initially, low-dose prophylactic antibiotics within the first year of life are recommended for the prevention of urinary tract infections, although there are no existing prospective randomised trials evaluating the benefit of this regimen (14).

With spontaneous remission rates of up to 85% in primary megaureter cases, surgical management is no longer recommended, except for megaureters with recurrent urinary tract infections, deterioration of split renal function and significant obstruction (15).

13.3.3.2 Surgical management

The initial approach to the ureter can be either intravesical, extravesical or combined. Straightening the ureter is necessary without devascularisation. Ureteral tapering should enhance urinary flow into the bladder. The ureter must be tapered to achieve a diameter for an antireflux repair. Several tailoring techniques exist, such as ureteral imbrication or excisional tapering (16). Some institutions perform endoscopic stenting, but there is still no long-term data and no prospective randomised trials to confirm their outcome.

13.4 Conclusion

The use of routine perinatal sonography has resulted in increased detection of hydronephrosis caused by UPJ or UVJ obstruction. Meticulous and repeat postnatal evaluation is mandatory to try to identify obstructive cases at risk of renal deterioration and requiring surgical reconstruction. Surgical methods are quite standardised and have a good clinical outcome.

13.5 Conclusions and recommendations for UPJ-, UVJ-obstruction

Conclusions	LE
Nowadays, most hydronephrotic kidneys have already been diagnosed prenatally during a maternal ultrasound investigation.	2
Ureteropelvic junction obstruction is the leading cause of (40%) of hydronephrotic kidneys (40%).	1

Recommendations	LE	GR
Postnatal investigations include serial ultrasound and subsequent diuretic renogram and sometimes VCUG.	2	B
A decision about surgical intervention should be based on the time course of the hydronephrosis and the impairment of renal function.	2	B
Indications for surgical intervention are an impaired split renal function due to obstruction or a decrease of split renal function in subsequent studies and increased anteroposterior diameter on the ultrasound, and grade IV dilatation as defined by the Society for Fetal Urology.	2	B
For uteropelvic junction obstruction, the gold standard of treatment is pyeloplasty.	2	B
Most primary megaureters require no surgical intervention.	2	B

13.6 References

- Lebowitz RL, Griscom NT. Neonatal hydronephrosis: 146 cases. *Radiol Clin North Am* 1977 Apr;15(1):49-59.
<http://www.ncbi.nlm.nih.gov/pubmed/8777627>
- Brown T, Mandell J, Lebowitz RL. Neonatal hydronephrosis in the era of sonography. *AJR Am J Roentgenol* 1987 May;148(5):959-63.
<http://www.ncbi.nlm.nih.gov/pubmed/8777627>
- Koff SA. Problematic ureteropelvic junction obstruction. *J Urol* 1987 Aug;138(2):390.
<http://www.ncbi.nlm.nih.gov/pubmed/8777627>
- Gunn TR, Mora JD, Pease P. Antenatal diagnosis of urinary tract abnormalities by ultrasonography after 28 weeks' gestation: incidence and outcome. *Am J Obstet Gynecol* 1995 Feb;172(2 Pt 1):479-86.
<http://www.ncbi.nlm.nih.gov/pubmed/8777627>
- Grignon A, Filiatrault D, Homsy Y, et al. Ureteropelvic junction stenosis: antenatal ultrasonographic diagnosis, postnatal investigation, and follow-up. *Radiology* 1986 Sep;160(3):649-51.
<http://www.ncbi.nlm.nih.gov/pubmed/8777627>
- Flashner SC, King LR. Ureteropelvic junction. In: *Clinical Pediatric Urology*. Philadelphia, WB Saunders: 1976, p. 693.
- Thomas DF. Prenatally detected uropathy: epidemiological considerations. *Br J Urol* 1998 Apr;81 Suppl 2:8-12.
<http://www.ncbi.nlm.nih.gov/pubmed/9602790>
- Ebel KD. Uroradiology in the fetus and newborn: diagnosis and follow-up of congenital obstruction of the urinary tract. *Pediatr Radiol* 1998 Aug;28(8):630-5.
<http://www.ncbi.nlm.nih.gov/pubmed/8777627>
- O'Reilly P, Aurell M, Britton K, et al. Consensus on diuresis renography for investigating the dilated upper urinary tract. Radionuclides in Nephrourology Group. Consensus Committee on Diuresis Renography. *J Nucl Med* 1996 Nov;37(11):1872-6.
<http://www.ncbi.nlm.nih.gov/pubmed/8917195>

10. Choong KK, Gruenewald SM, Hodson EM, et al. Volume expanded diuretic renography in the postnatal assessment of suspected uretero-pelvic junction obstruction. *J Nucl Med* 1992 Dec;33(12):2094-8.
<http://www.ncbi.nlm.nih.gov/pubmed/1460498>
11. Reddy PP, Mandell J. Prenatal diagnosis. Therapeutic implications. *Urol Clin North Am* 1998 May;25(2):171-80.
<http://www.ncbi.nlm.nih.gov/pubmed/9633572>
12. Novick AC, Stroom AB. Surgery of the kidney. In: *Campbell's Urology*. Philadelphia, WB Saunders: 1998, p. 3044.
13. Fernbach SK, Maizels M, Conway JJ. Ultrasound grading of hydronephrosis: introduction to the system used by the Society for Fetal Urology. *Pediatr Radiol* 1993;23(6):478-80.
<http://www.ncbi.nlm.nih.gov/pubmed/8255658>
14. Arena F, Baldari S, Proietto F, et al. Conservative treatment in primary neonatal megaureter. *Eur J Pediatr Surg* 1998 Dec;8(6):347-51.
<http://www.ncbi.nlm.nih.gov/pubmed/9926303>
15. Peters CA, Mandell J, Lebowitz RL, et al. Congenital obstructed megaureters in early infancy: diagnosis and treatment. *J Urol* 1989 Aug;142(2 Pt 2):641-5; discussion 667-8.
<http://www.ncbi.nlm.nih.gov/pubmed/2746792>
16. Sripathi V, King PA, Thomson MR, et al. Primary obstructive megaureter. *J Pediatr Surg* 1991 Jul;26(7):826-9.
<http://www.ncbi.nlm.nih.gov/pubmed/1895193>

14. VESICoureTERIC REFLUX IN CHILDREN

14.1 Methodology

The scientific literature for reflux disease is still limited and the level of evidence is generally low. Most of the studies are retrospective, include different patient groups, and have poor stratification of quality. Also, there is a high risk of presenting misleading results by combining different types of studies when systematically extracting data. Therefore, for reflux disease, it is unfortunately not possible to produce recommendations based on high-quality studies. The authors have assessed the current literature, but in the absence of conclusive findings, have provided recommendations based on panel consensus. These guidelines aim to provide a practical approach to the treatment of VUR based on risk analysis.

14.2 Background

Vesicoureteric reflux, or the retrograde flow of urine from the bladder into the ureter, is an anatomical and/or functional disorder with potentially serious consequences, such as renal scarring, hypertension, and renal failure. Fortunately, patients with VUR present within a wide range of severity, and a good proportion of reflux patients do not develop renal scars and probably do not need any intervention (1). VUR is a very common urological anomaly in children, with an incidence of nearly 1%. Its management is one of the most controversial issues in paediatric urology.

The main goal in management is the preservation of kidney function, by minimising the risk of pyelonephritis. By defining and analysing the risk factors for each patient [i.e. age, sex, reflux grade, lower urinary tract dysfunction (LUTD), anatomical abnormalities, and kidney status], it is possible to identify those patients with a potential risk of UTIs and renal scarring. Controversy persists over the optimal management of VUR, particularly the choice of diagnostic procedures, treatment (medical, endoscopic or open surgical), and the timing of treatment.

Many children present without symptoms of UTI and because invasive diagnostic procedures are performed only when clinically indicated, the exact prevalence of VUR is unknown. However, the prevalence of VUR in non-symptomatic children has been estimated at 0.4-1.8% (2). Among infants prenatally identified with hydronephrosis on ultrasonography (US), who were screened for VUR, the prevalence was 16.2% (7-35%) (3). Siblings of children with VUR had a 27.4% (3-51%) risk of also having VUR, whereas the offspring of parents with VUR had a higher incidence of 35.7% (21.2-61.4%) (3).

However, reflux detected by sibling screening is associated with lower grades (3) and significantly earlier resolution (4). When VUR is discovered in siblings after UTI, it is usually high grade and associated with a high incidence of reflux nephropathy, particularly if the sibling is male and the grade of reflux was high in the index patient. Even when asymptomatic, siblings and offspring of those with VUR may be diagnosed with high-grade reflux and scarring (5,6).

The incidence of VUR is much higher among children with UTIs (30-50%, depending on age). UTIs are more common in girls than boys due to anatomical differences. However, among all children with UTIs, boys are more likely to have VUR than girls (29% vs. 14%). Boys also tend to have higher grades of VUR diagnosed at younger ages, although their VUR is more likely to resolve (7-10).

There is a clear co-prevalence between LUTD and VUR (11). LUTD refers to the presence of lower urinary tract symptoms (LUTSs), including urge, urge incontinence, weak stream, hesitancy, frequency and UTIs, which reflect the filling and/or emptying dysfunction that may be accompanied with bowel problems (11). Some studies have described a prevalence of 40-60% for VUR in children with LUTD (12). It is possible that VUR is secondary to LUTD, and that treatment of LUTD therefore results in correction of VUR. In contrast, high-grade VUR may affect bladder dynamics, which subsequently leads to LUTD. A recently published Swedish reflux trial has demonstrated LUTD in 34% of patients, and subdivision into groups characteristic of children revealed that 9% had isolated overactive bladder and 24% had voiding phase dysfunction. There was a significant negative correlation between dysfunction at 2 years and improved dilating reflux. Renal damage at study entry and follow-up was associated with LUTD at 2 years. Recurrent UTIs were seen in 33% of children with LUTD, and in 20% of those without (13).

The spontaneous resolution of VUR is dependent on age at presentation, sex, grade, laterality, mode of clinical presentation, and anatomy (4). Faster resolution of VUR is more likely with age < 1 year at presentation, lower grade of reflux (grade 1-3), and asymptomatic presentation with prenatal hydronephrosis or sibling reflux. The overall resolution rate is high in congenital high-grade VUR during the first years of life. In several Scandinavian studies, the complete resolution rate for high-grade VUR has been reported at > 25%, which is higher than the resolution rate for VUR detected after infancy (14,15).

The presence of renal cortical abnormality, bladder dysfunction, and breakthrough febrile UTIs are negative predictive factors for reflux resolution (16-18).

Dilating VUR increases the risk of developing acute pyelonephritis and renal scarring. Untreated recurrent UTIs may have a negative impact on somatic growth and medical status of the child. Ten to forty percent of children with symptomatic VUR have evidence of renal scarring, resulting from either congenital dysplasia and/or acquired post-infectious damage, which may have a negative impact on somatic growth and general wellbeing (19-21).

Higher grades of VUR present with higher rates of renal scars. Scar rates vary in different patient groups. In those with prenatal hydronephrosis, renal scarring occurs in ~10% of patients (22-27), whereas in patients with LUTD, this may increase up to 30% (28-30). Renal scarring may adversely affect renal growth and function, with bilateral scarring increasing the risk of insufficiency. Reflux nephropathy (RN) may be the most common cause of childhood hypertension. Follow-up studies have shown that 10-20% of children with RN develop hypertension or end-stage renal disease (31).

14.3 Diagnostic work-up

The diagnostic work-up should aim to evaluate the overall health and development of the child, the presence of UTIs, renal status, the presence of VUR, and lower urinary tract function. A basic diagnostic work-up comprises a detailed medical history (including family history, and screening for LUTD), physical examination including blood pressure measurement, urinalysis (assessing proteinuria), urine culture, and serum creatinine in patients with bilateral renal parenchymal abnormalities.

Imaging is the basis of diagnosis and management of VUR. The standard imaging tests include renal and bladder ultrasonography (US), VCUG and nuclear renal scans. The criterion standard in diagnosis of VUR is VCUG, especially at the initial work-up. This test provides precise anatomical detail and allows grading of VUR (32). In 1985, the International Reflux Study Committee introduced a uniform system for the classification of VUR (33,34) (Table 9). The grading system combines two earlier classifications and is based upon the extent of retrograde filling and dilatation of the ureter, renal pelvis and calyces on VCUG (35).

Radionuclide studies for detection of reflux have lower radiation exposure than VCUG, but the anatomical details depicted are inferior (36). Recent studies on alternative imaging modalities for detection on VUR have yielded good results with voiding urosonography and magnetic resonance VCUG (37-39). However, despite the concerns about ionising radiation and its invasive nature, conventional VCUG still remains the gold standard because it allows better determination of the grade of VUR (in a single or duplicated kidney) and assessment of the bladder and urethral configuration.

Table 9: Grading system for VUR on VCUG, according to the International Reflux Study Committee (33)

Grade I	Reflux does not reach the renal pelvis; varying degrees of ureteral dilatation
Grade II	Reflux reaches the renal pelvis; no dilatation of the collecting system; normal fornices
Grade III	Mild or moderate dilatation of the ureter, with or without kinking; moderate dilatation of the collecting system; normal or minimally deformed fornices
Grade IV	Moderate dilatation of the ureter with or without kinking; moderate dilatation of the collecting system; blunt fornices, but impressions of the papillae still visible
Grade V	Gross dilatation and kinking of the ureter, marked dilatation of the collecting system; papillary impressions no longer visible; intraparenchymal reflux

Dimercaptosuccinic acid (DMSA) is the best nuclear agent for visualising the cortical tissue and differential function between both kidneys. DMSA is taken up by proximal renal tubular cells and is a good indicator of renal parenchyma function. In areas of acute inflammation or scarring, DMSA uptake is poor and appears as cold spots. DMSA scans are therefore used to detect and monitor renal scarring. A baseline DMSA scan at the time of diagnosis can be used for comparison with successive scans later during follow-up (35,40). DMSA can also be used as a diagnostic tool during suspected episodes of acute pyelonephritis (41). Children with a normal DMSA scan during acute UTI have a low risk of renal damage (42).

Video-urodynamic studies are only important in patients in whom secondary reflux is suspected, such as those with spina bifida or boys in whom VCUG is suggestive of posterior urethral valves. In the case of LUTS, diagnosis and follow-up can be limited to non-invasive tests (e.g. voiding charts, US, or uroflowmetry) (11).

Cystoscopy has a limited role in evaluating reflux, except for infravesical obstruction or ureteral anomalies that might influence therapy.

The choice of imaging modalities varies depending on the mode of presentation.

14.3.1 Infants presenting because of prenatally diagnosed hydronephrosis

Ultrasound of the kidney and bladder is the first standard evaluation tool for children with prenatally diagnosed hydronephrosis. It is non-invasive and provides reliable information regarding kidney structure, size, parenchymal thickness and collecting system dilatation (43,44).

Ultrasound should be delayed until after the first week after birth because of early oliguria in the neonate. It is essential to evaluate the bladder, as well as the kidneys. The degree of dilatation in the collecting system under US, when the bladder is both full and empty, may provide significant information about the presence of VUR. Bladder wall thickness and configuration may be an indirect sign of LUTD and reflux. The absence of hydronephrosis on postnatal ultrasound excludes the presence of significant obstruction; however, it does not exclude VUR.

Monitoring with careful US avoids unnecessary invasive and irradiating examinations. The first two US scans within the first 1-2 months of life are highly accurate for defining the presence or absence of renal pathology. In infants with two normal, successive scans, VUR is a rare entity, and if present it is likely to be low grade (23,45). The degree of hydronephrosis is not a reliable indicator for the presence of VUR, even though cortical abnormalities are more common in high-grade hydronephrosis (3). The presence of cortical abnormalities on US (defined as cortical thinning and irregularity, as well as increased echogenicity) warrants the use of VCUG for detecting VUR (3). DMSA provides more reliable and quantitative measurement of the degree of cortical abnormalities when first detected with US.

The use of VCUG is recommended in patients with US findings of bilateral high-grade hydronephrosis, duplex kidneys with hydronephrosis, ureterocele, ureteric dilatation, and abnormal bladders, because the likelihood of VUR is much higher. In all other conditions, the use of VCUG to detect reflux is optional (3,46-48). When infants who are diagnosed with prenatal hydronephrosis become symptomatic with UTIs, further evaluation with VCUG should be considered (48). Patients with severe hydronephrosis and those whose hydronephrosis is sustained or progressive need further evaluation to exclude obstruction (see Chapter 14).

14.3.2 Siblings and offspring of reflux patients

The screening of asymptomatic siblings and offspring is controversial. Some authors think that early identification of children with VUR may prevent episodes of UTI and therefore renal scarring, whereas others think that screening asymptomatic individuals is likely to result in significant over-treatment of clinically insignificant VUR.

The overall estimate for renal cortical abnormalities is 19.3% (11-54%), with 27.8% having renal

damage in cohorts of symptomatic and asymptomatic children combined. In asymptomatic siblings only, the rate of renal damage is 14.4% (0-100%). Early screening and therefore early diagnosis and treatment appears to be more effective than late screening in preventing further renal damage. (3,5,49,50).

The lack of randomised clinical trials for screened patients to assess clinical health outcomes makes evidence-based guideline recommendations difficult.

Recommendations for paediatric screening for VUR
The parents of children with VUR should be informed that siblings and offspring have a high prevalence of VUR.
If screening is performed, siblings should be screened by renal US. VCUG is recommended if there is evidence of renal scarring on US or a history of UTI.
In older children who are toilet-trained, there is no added value in screening for VUR.

14.3.3 Children with febrile urinary tract infections

VCUG is recommended at 0-2 years of age after the first proven febrile UTI. If reflux is diagnosed, further evaluation has traditionally consisted of a DMSA scan. However, it can be reserved for high-grade VUR or VUR associated with a suggestion of abnormal renal parenchyma on ultrasound, or it can be used as a baseline test to compare the consequences of potential pyelonephritic complications in the future.

An alternative “top-down” approach is also an option, as suggested by several studies in the literature. This approach carries out an initial DMSA scan close to the time of a febrile UTI, to determine the presence of pyelonephritis, which is then followed by VCUG if the DMSA scan reveals kidney involvement. A normal DMSA scan with no subsequent VCUG will fail to spot VUR in 5-27% of cases, with the missed VUR presumably being less significant. In contrast, a normal DMSA scan with no VCUG avoids unnecessary VCUG in > 50% of those screened (51-54).

14.3.4 Children with lower urinary tract symptoms and vesicoureteric reflux

Detection of LUTD is essential in treating children with VUR. There are several hypotheses. For example, it is suggested that reflux with LUTD resolves faster after LUTD correction, and that patients with LUTD are at higher risk for developing UTI and renal scarring (55). Alternatively, it is possible that LUTD is secondary to VUR and that treatment of VUR therefore results in correction of LUTD. Or, it may be that there is a high co-prevalence of LUTD and VUR, but the treatment of one condition does not correct the other. In recent literature, there are no data to support any of the above hypotheses. Most studies are descriptive, uncontrolled and retrospective, and the evidence quality is low.

A recent Swedish reflux study, however, has indicated that patients who have both VUR and LUTD may have a worse final outcome after treatment, including an elevated risk for kidney damage (13). The results from the Swedish study indicate that the coexistence of both conditions should be explored in any patient who has VUR. If there are symptoms suggestive of LUTD (e.g. urgency, wetting, constipation or holding manoeuvres), an extensive history and examination, including voiding charts, uroflowmetry and residual urine determination, will reliably diagnose underlying LUTD.

In LUTD, VUR is often low grade and US findings are normal, and there is no indication for performing VCUG in all children with LUTD. Instead, it would be more rational to ask any patient with LUTD if he or she has a history of febrile UTI, because there is a greater possibility of finding VUR in such patients. However, because of the coexistence of LUTD and VUR, it would be better to do a test covering both conditions, such as a video-urodynamic study (VUDS). Any patient with LUTD and a history of febrile UTI should be investigated with a VUDS, if available. Furthermore, any child who fails standard therapy for LUTD should undergo urodynamic investigation. At this stage, combining a urodynamic study with VCUG is highly recommended.

14.4 Treatment

There are two main treatment approaches: conservative (non-surgical) and surgical.

14.4.1 Conservative therapy

The objective of conservative therapy is prevention of febrile UTI. It is based on the understanding that:

- VUR resolves spontaneously, mostly in young patients with low-grade reflux. Resolution is nearly 80% in VUR grades I and II and 30-50% in VUR grades III-V within 4-5 years of follow-up. Spontaneous resolution is low for bilateral high-grade reflux (56).
- VUR does not damage the kidney when patients are free of infection and have normal lower urinary tract function.
- There is no evidence that small scars can cause hypertension, renal insufficiency or problems during

pregnancy. Indeed, these are possible only in cases of severe bilateral renal damage.

- The conservative approach includes watchful waiting, intermittent or continuous antibiotic prophylaxis, and bladder rehabilitation in those with LUTD (55,57-60).
- Circumcision during early infancy may be considered as part of the conservative approach, because it is effective in reducing the risk of infection in normal children (61).

14.4.1.1 Follow-up

Regular follow-up with imaging studies (e.g. VCUG, nuclear cystography, or DMSA scan) is part of the conservative management to monitor spontaneous resolution and kidney status. Conservative management should be dismissed in all cases of febrile breakthrough infections, despite prophylaxis, and intervention should be considered.

14.4.1.2 Continuous antibiotic prophylaxis (CAP)

The use of CAP and duration of follow-up during prophylaxis in reflux patients is another area of major controversy. Although it is difficult to make definitive recommendations based on recent literature, it is clear that antibiotic prophylaxis may not be needed in every reflux patient (58,62-64). Although there are trials showing no benefit of CAP, especially in low-grade reflux, there are also trials showing that CAP prevents further renal damage, particularly in patients with grade III and V reflux (65-69).

It is difficult and risky to select patients who do not need CAP. A safe approach would be to use CAP in most cases. Decision making may be influenced by the presence of risk factors for UTI, such as young age, high-grade VUR, status of toilet-training/LUTS, female sex, and circumcision status. However, recent literature does not provide any reliable information about the duration of CAP in reflux patients.

A practical approach would be to use CAP until after children have been toilet-trained and ensuring that there is no LUTD. Active surveillance of UTI is needed after CAP is discontinued. The follow-up scheme and the decision to perform an antireflux procedure or discontinuation of CAP may also depend on personal preferences and the attitude of patients and parents. It is strongly advised that the advantages and disadvantages should be discussed in detail with the family.

14.4.2 Surgical treatment

Surgical treatment can be carried out by endoscopic injection of bulking agents or ureteral reimplantation.

14.4.2.1 Subureteric injection of bulking materials

With the availability of biocompatible substances, subureteric injection of bulking materials has become increasingly popular because it is minimally invasive and performed on an outpatient basis. Using cystoscopy, bulking materials are injected beneath the intramural part of the ureter in a submucosal location. The injected bulking agent elevates the ureteral orifice and the distal ureter, so that coaptation is increased. This results in narrowing of the lumen, which prevents reflux of urine into the ureter, while still allowing its antegrade flow. With the availability of biodegradable substances, endoscopic subureteric injection of bulking agents has become an alternative to long-term antibiotic prophylaxis and surgical intervention in the treatment of VUR in children.

Several bulking agents have been used over the past two decades, including polytetrafluoroethylene (PTFE or Teflon), collagen, autologous fat, polydimethylsiloxane, silicone, chondrocytes, and more recently, a solution of dextranomer/hyaluronic acid (Deflux).

Although the best results have been obtained with PTFE (70), due to concerns about particle migration, PTFE has not been approved for use in children (71). Although they are all biocompatible, other compounds such as collagen and chondrocytes have failed to provide a good outcome. Deflux was approved by the US FDA in 2001 for the treatment of VUR in children. Initial clinical trials have demonstrated that this method is effective in treating reflux (72). Studies with long term follow-up have shown that there is a high recurrence rate which may go up to 20% in 2 years (62).

In a meta-analysis (73) including 5527 patients and 8101 renal units, the reflux resolution rate (by ureter) following one treatment for grades I and II reflux was 78.5%, 72% for grade III, 63% for grade IV, and 51% for grade V. If the first injection was unsuccessful, the second treatment had a success rate of 68% and the third treatment 34%. The aggregate success rate with one or more injections was 85%. The success rate was significantly lower for duplicated (50%) versus single (73%) systems, and neuropathic (62%) versus normal (74%) bladders.

Clinical validation of the effectiveness of antireflux endoscopy is currently hampered by the lack of methodologically appropriate studies. In the most recent prospective, randomised trials comparing three treatment arms (I, endoscopic injection; II, antibiotic prophylaxis; III, surveillance without antibiotic prophylaxis) in 203 children aged 1-2 years with grade III/IV reflux, endoscopic treatment gave the highest resolution rate of 71% compared to 39% and 47% for treatment arms II and III, respectively, after 2 years' follow-up. The

recurrence rate at 2 years after endoscopic treatment was 20%. The occurrence of febrile UTIs and scar formation was highest in the surveillance group at 57% and 11%, respectively. New scar formation rate was higher with endoscopic injection (7%) compared with antibiotic prophylaxis (0%) (74). Longer follow-up studies are needed to validate these findings.

14.4.2.2 Open surgical techniques

Various intra- and extravesical techniques have been described for the surgical correction of reflux. Although different methods have specific advantages and complications, they all share the basic principle of lengthening the intramural part of the ureter by submucosal embedding of the ureter. All techniques have been shown to be safe with a low rate of complications and excellent success rates (92-98%) (75).

The most popular and reliable open procedure is cross trigonal reimplantation described by Cohen. The main concern with this procedure is the difficulty of accessing the ureters endoscopically if needed when the child is older. Alternatives are suprahiatal reimplantation (Politano-Leadbetter technique) and infrahiatal reimplantation (Glenn-Anderson technique). If an extravesical procedure (Lich-Gregoir) is planned, cystoscopy should be performed preoperatively to assess the bladder mucosa and the position and configuration of the ureteric orifices. In bilateral reflux, an intravesical antireflux procedure may be considered, because simultaneous bilateral extravesical reflux repair carries an increased risk of temporary postoperative urine retention (76). Overall, all surgical procedures offer very high and similar success rates for correcting VUR.

14.4.2.3 Laparoscopy

There have been a considerable number of case series of transperitoneal extravesical and pneumovesicoscopic intravesical ureteral reimplantation, which have shown the feasibility of the techniques. Today, both conventional and robot-assisted laparoscopic approaches present comparable outcomes to their open surgical counterparts in terms of successful resolution of reflux. Further studies are needed to define the costs and benefits of both approaches.

The major shortcoming of the new techniques seems to be the longer operative times, which hinders their wider acceptance. Also, laparoscopic approaches are more invasive than endoscopic correction and their advantages over open surgery are still debated. Therefore, at present, a laparoscopic approach cannot be recommended as a routine procedure. It can be offered as an alternative to the parents in centres where there is enough experience (61,77-83).

14.5 Recommendations for the management of vesicoureteric reflux in childhood

Regardless of the grade of reflux or presence of renal scars, all patients diagnosed within the first year of life should be treated initially with CAP. During early childhood, the kidneys are at higher risk of developing new scars. Immediate, parenteral antibiotic treatment should be initiated for febrile breakthrough infections. Definitive surgical or endoscopic correction is the preferred treatment in patients with frequent breakthrough infections (78).
Surgical correction should be considered in patients with persistent high-grade reflux (grades IV/V). There is no consensus about the timing and type of surgical correction. The outcome of open surgical correction is better than endoscopic correction for higher grades of reflux, whereas satisfactory results can be achieved by endoscopic injection for lower grades.
There is no evidence that correction of persistent low-grade reflux (grades I-III) without symptoms and normal kidneys offers a significant benefit. These patients may be candidates for endoscopic treatment.
In all children presenting at age 1-5 years, CAP is the preferred option for initial therapy. For those with high-grade reflux or abnormal renal parenchyma, surgical repair is a reasonable alternative. In patients with lower grades of reflux and without symptoms, close surveillance without antibiotic prophylaxis may be an option.
A detailed investigation for the presence of LUTD should be performed in all children after toilet-training. If LUTD is found, the initial treatment should always be for LUTD.
If parents prefer definitive therapy to conservative management, surgical correction may be considered. Endoscopic treatment is an option for all children with low grades of reflux.
The traditional approach of initial medical treatment after diagnosis and shifting to interventional treatment in case of breakthrough infections and new scar formation needs to be challenged, because the treatment should be tailored to different risk groups.

The choice of management depends on the presence of renal scars, clinical course, grade of reflux, ipsilateral renal function, bilaterality, bladder function, associated anomalies of the urinary tract, age, compliance, and parental preference (79). Febrile UTI, high-grade reflux, bilaterality, and cortical abnormalities are considered to be risk factors for possible renal damage. The presence of LUTD is an additional risk factor for new scars.

In high-risk patients who already have renal impairment, a more aggressive, multidisciplinary approach is needed.

Table 10: Management and follow-up according to different risk groups

Risk Groups	Presentation	Initial treatment	Comment	Follow-up
High	Symptomatic male or female patients after toilet-training with high-grade reflux (grades IV-V), abnormal kidneys and LUTD	Initial treatment is always for LUTD with CAP; intervention may be considered in cases of BT infections or persistent reflux	Greater possibility of earlier intervention	More aggressive follow-up for UTI and LUTD; full re-evaluation after 6 months
High	Symptomatic male or female patients after toilet-training with high-grade reflux (grade IV-V), abnormal kidneys and no LUTD	Intervention should be considered	Open surgery has better results than endoscopic surgery	Post-operative VCUG on indication only; follow-up of kidney status until after puberty
Moderate	Symptomatic male or female patients before toilet-training, with high-grade reflux and abnormal kidneys	CAP is the initial treatment. Intervention may be considered in cases of BT infections or persistent reflux	Spontaneous resolution is higher in males	Follow-up for UTI/hydronephrosis; full re-evaluation after 12-24 months
Moderate	Asymptomatic patients (PNH or sibling) with high-grade reflux and abnormal kidneys	CAP is the initial treatment. Intervention may be considered in cases of BT, infections or persistent reflux		Follow-up for UTI/hydronephrosis; full re-evaluation after 12-24 months
Moderate	Symptomatic male or female patients after toilet-training, with high-grade reflux and normal kidneys with LUTD	Initial treatment is always for LUTD with CAP. Intervention may be considered in cases of BT, infections or persistent reflux	In case of persistent LUTD, despite urotherapy, intervention should be considered. The choice of intervention is controversial	Follow-up for UTI and LUTD, kidney status; full re-evaluation after successful urotherapy
Moderate	Symptomatic male or female patients after toilet-training with low-grade reflux, abnormal kidneys with or without LUTD	Choice of treatment is controversial. Endoscopic treatment may be an option. LUTD treatment should be given if needed.		Follow-up for UTI, LUTD, and kidney status until after puberty
Moderate	All symptomatic patients with normal kidneys, with low-grade reflux, with LUTD	Initial treatment is always for LUTD with or without CAP		Follow-up for UTI and LUTD
Low	All symptomatic patients with normal kidneys, with low-grade reflux, with no LUTD	No treatment or CAP	If no treatment is given, parents should be informed about risk of infection	Follow-up for UTI
Low	All asymptomatic patients with normal kidneys with low-grade reflux	No treatment or CAP in infants	If no treatment is given, parents should be informed about risk of infection	Follow-up for UTI

PNH = prenatal diagnosed hydronephrosis.

14.6 References

1. Fanos V, Cataldi L. Antibiotics or surgery for vesicoureteric reflux in children. *Lancet* 2004 Nov;364(9446):1720-2.
<http://www.ncbi.nlm.nih.gov/pubmed/15530633>
2. Sargent MA. What is the normal prevalence of vesicoureteral reflux? *Pediatr Radiol.* 2000 Sep;30(9):587-93.
<http://www.ncbi.nlm.nih.gov/pubmed/11009294>
3. Skoog SJ, Peters CA, Arant BS Jr, et al. Pediatric Vesicoureteral Reflux Guidelines Panel Summary Report: Clinical Practice Guidelines for Screening Siblings of Children With Vesicoureteral Reflux and Neonates/Infants With Prenatal Hydronephrosis. *J Urol* 2010 Sep;184(3):1145-51.
<http://www.ncbi.nlm.nih.gov/pubmed/20650494>
4. Estrada CR Jr, Passerotti CC, Graham DA, et al. Nomograms for predicting annual resolution rate of primary vesicoureteral reflux: results from 2,462 children. *J Urol* 2009 Oct;182(4):1535-41.
<http://www.ncbi.nlm.nih.gov/pubmed/19683762>
5. Pirker ME, Colhoun E, Puri P. Renal scarring in familial vesicoureteral reflux: is prevention possible? *J Urol* 2006 Oct;176(4 Pt 2):1842-6; discussion 1846.
<http://www.ncbi.nlm.nih.gov/pubmed/16945668>
6. Pirker ME, Mohanan N, Colhoun E, et al. Familial vesicoureteral reflux: influence of sex on prevalence and expression. *J Urol* 2006 Oct;176(4 Pt 2):1776-80.
<http://www.ncbi.nlm.nih.gov/pubmed/16945647>
7. Hannula A, Venhola M, Renko M, et al. Vesicoureteral reflux in children with suspected and proven urinary tract infection. *Pediatr Nephrol.* 2010 Aug;25(8):1463-9.
<http://www.ncbi.nlm.nih.gov/pubmed/20467791>
8. Menezes M, Puri P. Familial vesicoureteral reflux--is screening beneficial? *J Urol.* 2009 Oct;182(4 Suppl):1673-7.
<http://www.ncbi.nlm.nih.gov/pubmed/19692047>
9. Alsaywid BS, Saleh H, Deshpande A, et al. High grade primary vesicoureteral reflux in boys: long-term results of a prospective cohort study. *J Urol* 2010 Oct;184(4 Suppl):1598-603.
<http://www.ncbi.nlm.nih.gov/pubmed/20728178>
10. Noe HN. The long-term results of prospective sibling reflux screening. *J Urol.* 1992 Nov;148(5 Pt 2):1739-42.
<http://www.ncbi.nlm.nih.gov/pubmed/1433599>
11. Koff SA, Wagner TT, Jayanthi VR. The relationship among dysfunctional elimination syndromes, primary vesicoureteral reflux and urinary tract infections in children. *J Urol* 1998;160(3 Pt 2):1019-22.
<http://www.ncbi.nlm.nih.gov/pubmed/9719268>
12. Ural Z, Ulman I, Avanoğlu A. Bladder dynamics and vesicoureteral reflux: factors associated with idiopathic lower urinary tract dysfunction in children. *J Urol* 2008 Apr; 179(4):1564-7.
<http://www.ncbi.nlm.nih.gov/pubmed/18295262>
13. Sillén U, Brandström P, Jodal U, et al. The Swedish reflux trial in children: v. Bladder dysfunction. *J Urol* 2010 Jul;184(1):298-304.
<http://www.ncbi.nlm.nih.gov/pubmed/20488486>
14. Sjöström S, Sillén U, Bachelard M, Hansson S, Stokland E. Spontaneous resolution of high grade infantile vesicoureteral reflux. *J Urol* 2004 Aug;172(2):694-8; discussion 699.
<http://www.ncbi.nlm.nih.gov/pubmed/15247764>
15. Esbjörner E, Hansson S, Jakobsson B; Swedish Paediatric Nephrology Association. Management of children with dilating vesico-ureteric reflux in Sweden. *Acta Paediatr.* 2004 Jan;93(1):37-42.)
16. Knudson MJ, Austin JC, McMillan ZM, et al. Predictive factors of early spontaneous resolution in children with primary vesicoureteral reflux. *J Urol* 2007 Oct;178(4 Pt 2):1684-8.
<http://www.ncbi.nlm.nih.gov/pubmed/17707023>
17. Yeung CK, Sreedhar B, Sihoe JD, et al. Renal and bladder functional status at diagnosis as predictive factors for the outcome of primary vesicoureteral reflux in children. *J Urol* 2006 Sep;176(3):1152-6; discussion 1156-7
<http://www.ncbi.nlm.nih.gov/pubmed/16890714>
18. Sjöström S, Sillén U, Jodal U, et al. Predictive factors for resolution of congenital high grade vesicoureteral reflux in infants: results of univariate and multivariate analyses. *J Urol* 2010 Mar;183(3):1177-84.
<http://www.ncbi.nlm.nih.gov/pubmed/20096864>
19. Peters C, Rushton HG. Vesicoureteral reflux associated renal damage: congenital reflux nephropathy and acquired renal scarring. *J Urol* 2010 Jul;184(1):265-73.
<http://www.ncbi.nlm.nih.gov/pubmed/20483150>

20. Mohanan N, Colhoun E, Puri P. Renal parenchymal damage in intermediate and high grade infantile vesicoureteral reflux. *J Urol* 2008 Oct;180(4 Suppl):1635-8; discussion 1638.
<http://www.ncbi.nlm.nih.gov/pubmed/18708232>
21. Olbing H, Smellie JM, Jodal U, et al. New renal scars in children with severe VUR: a 10-year study of randomized treatment. *Pediatr Nephrol* 2003 Nov ;18(11):1128-31.
<http://www.ncbi.nlm.nih.gov/pubmed/14523634>
22. Estrada CR, Peters CA, Retik AB, et al. Vesicoureteral reflux and urinary tract infection in children with a history of prenatal hydronephrosis--should voiding cystourethrography be performed in cases of postnatally persistent grade II hydronephrosis? *J Urol* 2009 Feb;181(2):801-6; discussion 806-7.
<http://www.ncbi.nlm.nih.gov/pubmed/19095265>
23. Coplen DE, Austin PF, Yan Y, et al. Correlation of prenatal and postnatal ultrasound findings with the incidence of vesicoureteral reflux in children with fetal renal pelvic dilatation. *J Urol* 2008 Oct;180(4 Suppl):1631-4; discussion 1634.
<http://www.ncbi.nlm.nih.gov/pubmed/18718617>
24. Phan V, Traubici J, Hershenfield B, et al. Vesicoureteral reflux in infants with isolated antenatal hydronephrosis. *Pediatr Nephrol* 2003 Dec;18(12):1224-8.
<http://www.ncbi.nlm.nih.gov/pubmed/14586679>
25. Mallik M, Watson AR. Antenatally detected urinary tract abnormalities: more detection but less action. *Pediatr Nephrol* 2008 Jun;23(6):897-904.
<http://www.ncbi.nlm.nih.gov/pubmed/18278521>
26. Lee RS, Cendron M, Kinnamon DD, et al. Antenatal hydronephrosis as a predictor of postnatal outcome: a meta-analysis. *Pediatrics* 2006 Aug;118(2):586-93.
<http://www.ncbi.nlm.nih.gov/pubmed/16882811>
27. Ylilin E, Ala-Houhala M, Wikström S. Risk of renal scarring in vesicoureteral reflux detected either antenatally or during the neonatal period. *Urology* 2003 Jun;61(6):1238-42; discussion 1242-3.
<http://www.ncbi.nlm.nih.gov/pubmed/12809909>
28. Leonardo CR, Filgueiras MF, Vasconcelos MM, et al. Risk factors for renal scarring in children and adolescents with lower urinary tract dysfunction. *Pediatr Nephrol* 2007 Nov;22(11):1891-6.
<http://www.ncbi.nlm.nih.gov/pubmed/17874252>
29. Peters CA, Skoog SJ, Arant BS Jr, et al. Summary of the AUA Guideline on Management of Primary Vesicoureteral Reflux in Children. *J Urol* 2010 Sep;184(3):1134-44.
<http://www.ncbi.nlm.nih.gov/pubmed/20650499>
30. Naseer SR, Steinhardt GF. New renal scars in children with urinary tract infections, vesicoureteral reflux and voiding dysfunction: a prospective evaluation. *J Urol* 1997 Aug;158(2):566-8.
<http://www.ncbi.nlm.nih.gov/pubmed/9224361>
31. Blumenthal I. Vesicoureteric reflux and urinary tract infection in children. *Postgrad Med J* 2006;82(963):31-5.
<http://www.ncbi.nlm.nih.gov/pubmed/16397077>
32. Darge K, Riedmiller H. Current status of vesicoureteral reflux diagnosis. *World J Urol* 2004;22(2):88-95.
<http://www.ncbi.nlm.nih.gov/pubmed/15173954>
33. Westwood ME, Whiting PF, Cooper J, et al. Further investigation of confirmed urinary tract infection (UTI) in children under five years: a systematic review. *BMC Pediatr* 2005 Mar 15;5(1):2.
<http://www.ncbi.nlm.nih.gov/pubmed/15769296>
34. Lebowitz RL, Olbing H, Parkkulainen KV, et al. International Reflux Study in Children: international system of radiographic grading of vesicoureteric reflux. *Pediatr Radiol* 1985;15(2):105-9.
<http://www.ncbi.nlm.nih.gov/pubmed/3975102>
35. Westwood ME, Whiting PF, Cooper J, et al. Further investigation of confirmed urinary tract infection (UTI) in children under five years: a systematic review. *BMC Pediatr* 2005 Mar 15;5(1):2.
<http://www.ncbi.nlm.nih.gov/pubmed/15769296>
36. Snow BW, Taylor MB. Non-invasive vesicoureteral reflux imaging. *J Pediatr Urol* 2010 Dec;6(6):543-9.
<http://www.ncbi.nlm.nih.gov/pubmed/20488755>
37. Papadopoulou F, Anthopoulou A, Siomou E, et al. Harmonic voiding urosonography with a second-generation contrast agent for the diagnosis of vesicoureteral reflux. *Pediatr Radiol* 2009 Mar;39(3):239-44.
<http://www.ncbi.nlm.nih.gov/pubmed/19096835>
38. Darge K. Voiding urosonography with US contrast agents for the diagnosis of vesicoureteric reflux in children. II. Comparison with radiological examinations. *Pediatr Radiol* 2008 Jan;38(1):54-63; quiz 126-7.
<http://www.ncbi.nlm.nih.gov/pubmed/17639371>

39. Takazakura R, Johnin K, Furukawa A, et al. Magnetic resonance voiding cystourethrography for vesicoureteral reflux. *J Magn Reson Imaging* 2007 Jan;25(1):170-4.
<http://www.ncbi.nlm.nih.gov/pubmed/17154372>
40. Scherz HC, Downs TM, Caesar R. The selective use of dimercaptosuccinic acid renal scans in children with vesicoureteral reflux. *J Urol* 1994 Aug;152(2 Pt 2):628-31.
<http://www.ncbi.nlm.nih.gov/pubmed/8021985>
41. Lee MD, Lin CC, Huang FY, et al. Screening young children with a first febrile urinary tract infection for high-grade vesicoureteral reflux with renal ultrasound scanning and technetium-99m-labeled dimercaptosuccinic acid scanning. *J Pediatr* 2009 Jun;154(6):797-802.
<http://www.ncbi.nlm.nih.gov/pubmed/19230904>
42. Hoberman A, Charron M, Hickey RW, et al. Imaging studies after a first febrile urinary tract infection in young children. *N Engl J Med* 2003 Jan;348(3):195-202.
<http://www.ncbi.nlm.nih.gov/pubmed/12529459>
43. Grazioli S, Parvex P, Merlini L, et al. Antenatal and postnatal ultrasound in the evaluation of the risk of vesicoureteral reflux. *Pediatr Nephrol* 2010 Sep;25(9):1687-92.
<http://www.ncbi.nlm.nih.gov/pubmed/20524012>
44. Lidefelt KJ, Herthelius M. Antenatal hydronephrosis: infants with minor postnatal dilatation do not need prophylaxis. *Pediatr Nephrol* 2008 Nov;23(11):2021-4.
<http://www.ncbi.nlm.nih.gov/pubmed/18560902>
45. Hafez AT, McLorie G, Bagli D, et al. Analysis of trends on serial ultrasound for high grade neonatal hydronephrosis. *J Urol* 2002 Oct;168(4 Pt 1):1518-21.
<http://www.ncbi.nlm.nih.gov/pubmed/12352447>
46. Lee RS, Cendron M, Kinnamon DD, et al. Antenatal hydronephrosis as a predictor of postnatal outcome: a meta-analysis. *Pediatrics* 2006 Aug;118(2):586-93.
<http://www.ncbi.nlm.nih.gov/pubmed/16882811>
47. Lee JH, Choi HS, Kim JK, et al. Nonrefluxing neonatal hydronephrosis and the risk of urinary tract infection. *J Urol* 2008 Apr;179(4):1524-8.
<http://www.ncbi.nlm.nih.gov/pubmed/18295269>
48. Sidhu G, Beyene J, Rosenblum ND. Outcome of isolated antenatal hydronephrosis: a systematic review and meta-analysis. *Pediatr Nephrol* 2006 Feb;21(2):218-24.
<http://www.ncbi.nlm.nih.gov/pubmed/16362721>
49. Houle AM, Cheikhelard A, Barrieras D, et al. Impact of early screening for reflux in siblings on the detection of renal damage. *BJU Int* 2004 Jul;94(1):123-5.
<http://www.ncbi.nlm.nih.gov/pubmed/15217445>
50. Puri P, Cascio S, Lakshmandass G, et al. Urinary tract infection and renal damage in sibling vesicoureteral reflux. *J Urol* 1998 Sep;160(3 Pt 2):1028-30; discussion 1038.
<http://www.ncbi.nlm.nih.gov/pubmed/9719271>
51. Hansson S, Dhamey M, Sigström O, et al. Dimercapto-succinic acid scintigraphy instead of voiding cystourethrography for infants with urinary tract infection. *J Urol* 2004 Sep;172(3):1071-3; discussion 1073-4.
<http://www.ncbi.nlm.nih.gov/pubmed/15311040>
52. Herz D, Merguerian P, McQuiston L, et al. 5-year prospective results of dimercapto-succinic acid imaging in children with febrile urinary tract infection: proof that the top-down approach works. *J Urol* 2010 Oct;184(4 Suppl):1703-9.
<http://www.ncbi.nlm.nih.gov/pubmed/20728131>
53. Quirino IG, Silva JM, Diniz JS, et al. Combined use of late phase dimercapto-succinic acid renal scintigraphy and ultrasound as first line screening after urinary tract infection in children. *J Urol* 2011 Jan;185(1):258-63.
<http://www.ncbi.nlm.nih.gov/pubmed/21074813>
54. Preda I, Jodal U, Sixt R, et al. Normal dimercaptosuccinic acid scintigraphy makes voiding cystourethrography unnecessary after urinary tract infection. *J Pediatr* 2007 Dec;151(6):581-4, 584.e1.
<http://www.ncbi.nlm.nih.gov/pubmed/18035134>
55. Colen J, Docimo SG, Stanitski K, et al. Dysfunctional elimination syndrome is a negative predictor for vesicoureteral reflux. *J Pediatr Urol* 2006 Aug;2(4):312-5.
<http://www.ncbi.nlm.nih.gov/pubmed/18947628>
56. Elder JS, Peters CA, Arant BS Jr, et al. Pediatric Vesicoureteral Reflux Guidelines Panel summary report on the management of primary vesicoureteral reflux in children. *J Urol*. 1997 May;157(5):1846-51.
<http://www.ncbi.nlm.nih.gov/pubmed/9112544>

57. Dias CS, Silva JM, Diniz JS, et al. Risk factors for recurrent urinary tract infections in a cohort of patients with primary vesicoureteral reflux. *Pediatr Infect Dis J* 2010 Feb;29(2):139-44.
<http://www.ncbi.nlm.nih.gov/pubmed/20135833>
58. Craig JC, Simpson JM, Williams GJ, et al. Prevention of Recurrent Urinary Tract Infection in Children with Vesicoureteric Reflux and Normal Renal Tracts (PRIVENT) Investigators. Antibiotic prophylaxis and recurrent urinary tract infection in children. *N Engl J Med* 2009 Oct 29;361(18):1748-59.
<http://www.ncbi.nlm.nih.gov/pubmed/19864673>
59. Williams GJ, Wei L, Lee A, et al. Long-term antibiotics for preventing recurrent urinary tract infection in children. *Cochrane Database Syst Rev.* 2006 Jul 19;3:CD001534.
<http://www.ncbi.nlm.nih.gov/pubmed/16855971>
60. Wheeler DM, Vimalachandra D, Hodson EM, et al. Interventions for primary vesicoureteric reflux. *Cochrane Database Syst Rev.* 2004;(3):CD001532. Review. Update in: *Cochrane Database Syst Rev* 2007;(3):CD001532.
<http://www.ncbi.nlm.nih.gov/pubmed/15266449>
61. Singh-Grewal D, Macclessi J, Craig J. Circumcision for the prevention of urinary tract infection in boys: a systematic review of randomised trials and observational studies. *Arch Dis Child* 2005 Aug;90(8):853-8.
<http://www.ncbi.nlm.nih.gov/pubmed/15890696>
62. Brandström P, Nevéus T, Sixt R, et al. The Swedish reflux trial in children: IV. Renal damage. *J Urol* 2010 Jul;184(1):292-7. Epub 2010 May 23.
<http://www.ncbi.nlm.nih.gov/pubmed/20494369>
63. Greenfield SP, Chesney RW, Carpenter M, et al. Vesicoureteral reflux: the RIVUR study and the way forward. *J Urol* 2008 Feb; 179(2):405-7.
<http://www.ncbi.nlm.nih.gov/pubmed/18076937>
64. Greenfield SP. Antibiotic Prophylaxis in Pediatric Urology: An Update. *Curr Urol Rep* 2011 Jan 13.
<http://www.ncbi.nlm.nih.gov/pubmed/21229337>
65. Garin EH, Olavarria F, Garcia Nieto V, et al. Clinical significance of primary vesicoureteral reflux and urinary antibiotic prophylaxis after acute pyelonephritis: a multicenter, randomized, controlled study. *Pediatrics* 2006 Mar;117(3):626-32.
<http://www.ncbi.nlm.nih.gov/pubmed/16510640>
66. Pennesi M, Travan L, Peratoner L, et al; North East Italy Prophylaxis in VUR study group. Is antibiotic prophylaxis in children with vesicoureteral reflux effective in preventing pyelonephritis and renal scars? A randomized, controlled trial. *Pediatrics.* 2008 Jun;121(6):e1489-94.
<http://www.ncbi.nlm.nih.gov/pubmed/18490378>
67. Montini G, Rigon L, Zucchetto P, et al; IRIS Group. Prophylaxis after first febrile urinary tract infection in children? A multicenter, randomized, controlled, noninferiority trial. *Pediatrics* 2008 Nov;122(5):1064-71.
<http://www.ncbi.nlm.nih.gov/pubmed/18977988>
68. Roussey-Kesler G, Gadjos V, Idres N, et al. Antibiotic prophylaxis for the prevention of recurrent urinary tract infection in children with low grade vesicoureteral reflux: results from a prospective randomized study. *J Urol* 2008;179(2):674-9.
<http://www.ncbi.nlm.nih.gov/pubmed/18082208>
69. Brandström P, Esbjorner E, Herthelius M, et al. The Swedish Reflux Trial in Children: III. Urinary tract infection pattern. *J Urol* 2010;184(1):286-91.
<http://www.ncbi.nlm.nih.gov/pubmed/20488494>
70. Puri P, Granata C. Multicenter survey of endoscopic treatment of vesicoureteral reflux using polytetrafluoroethylene. *J Urol* Sep 1998;160(3 Pt 2):1007-11; discussion 1038.
<http://www.ncbi.nlm.nih.gov/pubmed/9719265>
71. Steyaert H, Sattonnet C, Bloch C, et al. Migration of PTFE paste particles to the kidney after treatment for vesico-ureteric reflux. *BJU Int* Jan 2000;85(1):168-9.
<http://www.ncbi.nlm.nih.gov/pubmed/10619969>
72. Lightner DJ. Review of the available urethral bulking agents. *Curr Opin Urol* 2002 Jul;12(4):333-8.
<http://www.ncbi.nlm.nih.gov/pubmed/12072655>
73. Elder JS, Diaz M, Caldamone AA, et al. Endoscopic therapy for vesicoureteral reflux: a meta-analysis. I. Reflux resolution and urinary tract infection. *J Urol* 2006 Feb;175(2):716-22.
<http://www.ncbi.nlm.nih.gov/pubmed/16407037>
74. Holmdahl G, Brandström P, Läckgren G, et al. The Swedish reflux trial in children: II. Vesicoureteral reflux outcome. *J Urol* 2010 Jul;184(1):280-5.
<http://www.ncbi.nlm.nih.gov/pubmed/20488469>

75. Duckett JW, Walker RD, Weiss R. Surgical results: International Reflux Study in Children--United States branch. *J Urol* 1992 Nov;148(5 Pt 2):1674-5.
<http://www.ncbi.nlm.nih.gov/pubmed/1433586>
76. Lipski BA, Mitchell ME, Burns MW. Voiding dysfunction after bilateral extravesical ureteral reimplantation. *J Urol* 1998 Mar;159(3):1019-21.
<http://www.ncbi.nlm.nih.gov/pubmed/9474222>
77. Janetschek G, Radmayr C, Bartsch G. Laparoscopic ureteral anti-reflux plasty reimplantation. First clinical experience. *Ann Urol (Paris)* 1995;29(2):101-5.
<http://www.ncbi.nlm.nih.gov/pubmed/7645993>
78. El-Ghoneimi A. Paediatric laparoscopic surgery. *Curr Opin Urol* 2003 Jul;13(4):329-35.
<http://www.ncbi.nlm.nih.gov/pubmed/12811298>
79. Jayanthi V, Patel A. Vesicoscopic ureteral reimplantation: a minimally invasive technique for the definitive repair of vesicoureteral reflux. *Adv Urol* 2008;973616
<http://www.ncbi.nlm.nih.gov/pubmed/19009038>
80. Chung PH, Tang DY, Wong KK, et al. Comparing open and pneumovesical approach for ureteric reimplantation in pediatric patients--a preliminary review. *J Pediatr Surg* 2008 Dec;43(12):2246-9.
<http://www.ncbi.nlm.nih.gov/pubmed/19009038>
81. Riquelme M, Aranda A, Rodriguez C. Laparoscopic extravesical transperitoneal approach for vesicoureteral reflux. *J Laparoendosc Adv Surg Tech A* 2006 Jun;16(3):312-6.
<http://www.ncbi.nlm.nih.gov/pubmed/16796449>
82. Canon SJ, Jayanthi VR, Patel AS. Vesicoscopic cross-trigonal ureteral reimplantation: a minimally invasive option for repair of vesicoureteral reflux. *J Urol* 2007 Jul;178(1):269-73; discussion 273.
<http://www.ncbi.nlm.nih.gov/pubmed/17499791>
83. Marchini GS, Hong YK, Minnillo BJ, et al. Robotic assisted laparoscopic ureteral reimplantation in children: case matched comparative study with open surgical approach. *J Urol* 2011 May;185(5):1870-5.
<http://www.ncbi.nlm.nih.gov/pubmed/21421223>
84. Austin JC, Cooper CS. Vesicoureteral reflux: who benefits from correction. *Urol Clin North Am* 2010 May;37(2):243-52.
<http://www.ncbi.nlm.nih.gov/pubmed/20569802>

15. URINARY STONE DISEASE

15.1 Background

Paediatric stone disease is an important clinical problem in paediatric urology practice. Because of its recurrent nature, every effort should be made to discover the underlying metabolic abnormality so that it can be treated appropriately. Obtaining a stone-free state with interventional management and close follow-up are of the utmost importance.

Paediatric stone disease has its own unique features, which are different in both presentation and treatment compared to stone disease in adults. In contrast to adults with stone disease who are more likely to be male, boys and girls are affected almost equally. Most paediatric stones are located in the upper urinary tract. However, bladder stones are still common in underdeveloped areas of the world and are usually ammonium acid urate and uric acid stones, strongly implicating dietary factors (1).

The incidence and characteristics of stones show a wide geographical variation in children. Although urinary stone disease is generally considered to be a relatively rare disease, it is quite common in some parts of the world. Paediatric stone disease is endemic in Turkey, Pakistan and in some South Asian, African and South American states. However, recent epidemiological studies have shown that the incidence of paediatric stone disease is also increasing in the Western world (2,3) especially in girls, Caucasian ethnicity, and older children (4). In the UK and other European countries, 75% of calculi in children are composed of organic matrix and struvite, with many stone formations associated with *Proteus* infection and urinary tract anomalies (5).

15.2 Stone formation mechanisms, diagnosis of causative factors and medical treatment for specific stone types

Urinary stone formation is the result of a complex process involving metabolic, anatomical factors and presence of infection.

Calcium, oxalate, uric acid or cystine molecules may develop into stones when they are supersaturated in urine. In the presence of a supersaturated solution, a decreased concentration of

crystallisation inhibitors (citrate, magnesium, pyrophosphate, macromolecules and glycosaminoglycans) may be all that is needed for a urinary stone to form. Urinary pH changes also affect stone formation. In addition, an impaired flow of urine due to an abnormal morphology may facilitate stasis and increase the concentration of stone-forming substances.

15.2.1 Calcium stones

Calcium stones are usually made from calcium oxalate or calcium phosphate. Supersaturation of calcium (hypercalciuria) and oxalate (hyperoxaluria) or decreased concentration of inhibitors, such as citrate (hypocitraturia), play a major role in the formation of calcium oxalate stones.

Hypercalciuria. This is defined by a 24-hour urinary calcium excretion of more than 4 mg/kg/day in a child weighing less than 60 kg. In infants younger than 3 months, 5 mg/kg/day is considered to be the upper limit of normal for calcium excretion (6).

Hypercalciuria can be classified as either idiopathic or secondary. Idiopathic hypercalciuria is diagnosed when clinical, laboratory, and radiographic investigations fail to delineate an underlying cause. Secondary hypercalciuria occurs when a known process produces excessive urinary calcium. In secondary (hypercalcaemic) hypercalciuria, a high serum calcium level may be due to increased bone resorption (hyperparathyroidism, hyperthyroidism, immobilization, acidosis, metastatic disease) or gastrointestinal hyperabsorption (hypervitaminosis D) (7).

A good screening test for hypercalciuria compares the ratio of urinary calcium to creatinine. The normal calcium-to-creatinine ratio in children is less than 0.2. If the calculated ratio is higher than 0.2, repeat testing is indicated. Neonates and infants have a higher calcium excretion and lower creatinine excretion than older children (6,74). If the follow-up ratios are normal, then no additional testing for hypercalciuria is needed. However, if the ratio remains elevated, a timed 24-hour urine collection should be obtained and the calcium excretion calculated.

The 24-hour calcium excretion test is the criterion standard for the diagnosis of hypercalciuria. If calcium excretion is higher than 4 mg/kg/day (0.1 mmol/kg/day), the diagnosis of hypercalciuria is confirmed and further evaluation is warranted. Further evaluation includes levels of serum bicarbonate, creatinine, alkaline phosphatase, calcium, magnesium, pH, and parathyroid hormone. Freshly voided urine should be measured for pH (6-9).

A 24-hour urine collection should also be collected for measurement of calcium, phosphorus, sodium, magnesium, citrate and oxalate. Meanwhile dietary manipulations should be tried to normalise urine calcium (9).

Initial management is always to increase fluid intake and urinary flow. Dietary modification is a mandatory part of effective therapy. The child should be referred to a dietician to assess accurately the daily intake of calcium, animal protein, and sodium. Dietary sodium restriction is recommended as well as maintenance of calcium intake consistent with the daily needs of the child (10).

A brief trial of a low-calcium diet can be carried out to determine if exogenous calcium intake is contributing to high urinary calcium. However, great caution should be used when trying to restrict calcium intake for long periods (LE: 3; GR: B).

Hydrochlorothiazide and other thiazide-type diuretics may be used to treat hypercalciuria at a dosage of 1-2 mg/kg/day (5,11) (LE: 3; GR: C). Citrate therapy is also useful if citrate levels are low or if hypercalciuria persists, despite other therapies (5,12) (LE: 4; GR: C).

Hyperoxaluria. Oxalic acid is a metabolite excreted by the kidneys. Only 10-15% of oxalate comes from diet. Normal school children excrete less than 50 mg (0.57 mmol)/1.73m²/day (5,13), while infants excrete four times as much. Hyperoxaluria may result from increased dietary intake, enteric hyperabsorption (as in short bowel syndrome) or an inborn error of metabolism.

In primary hyperoxaluria, one of the two liver enzymes that play a role in the metabolism of oxalate may be deficient. In primary hyperoxaluria there is increased deposition of calcium oxalate in the kidney and in urine. With increased deposition of calcium oxalate in the kidneys, renal failure may ensue in resulting deposition of calcium oxalate in other tissues. The diagnosis is made upon laboratory findings of severe hyperoxaluria and clinical symptoms. The definitive diagnosis requires liver biopsy to assay the enzyme activity.

Other forms of hyperoxaluria, as mentioned earlier, may be due to hyperabsorption of oxalate in inflammatory bowel syndrome, pancreatitis and short bowel syndrome. Yet, the majority of children who have high levels of oxalate excretion in urine may not have any documented metabolic problem or any dietary cause. This is known as idiopathic 'mild' hyperoxaluria, with urine oxalate levels elevated only mildly in these cases. The treatment of hyperoxaluria consists of the promotion of high urine flow, restriction of dietary oxalate and regular calcium intake. Pyridoxine may be useful in reducing urine levels, especially in primary hyperoxaluria (5,13) (LE: 4; GR: C).

Hypocitraturia. Citrate is a urinary stone inhibitor. Citrate acts by binding to calcium and by directly inhibiting the growth and aggregation of calcium oxalate as well as calcium phosphate crystals. Thus, low urine citrate may be a significant cause of calcium stone disease. In adults, hypocitraturia is the excretion of citrate in urine of less than 320 mg/day (1.5 mmol/day) for adults; this value must be adjusted for children depending on body size (14,15).

Hypocitraturia usually occurs in the absence of any concurrent symptoms or any known metabolic derangements. It may also occur in association with any metabolic acidosis, distal tubular acidosis or diarrhoeal syndromes.

Environmental factors that lower urinary citrate include a high protein intake and excessive salt intake. Many reports emphasise the significance of hypocitraturia in paediatric calcium stone disease. The presence of hypocitraturia ranges from 30% to 60% in children with calcium stone disease.

Due to the increased stone risk in hypocitraturia, the restoration of normal citrate levels is advocated to reduce stone formation. Although some studies have shown that citrate replacement therapy reduces the risk of stone formation in an adult population, there are few relevant studies in children. Hypocitraturia is treated by potassium citrate at a starting dose of 1 mEq/kg, given in two divided doses (15) (LE: 3; GR: B).

15.2.2 **Uric acid stones**

Uric acid stones are responsible for urinary calculi in 4-8% of children. Uric acid is the end product of purine metabolism. Hyperuricosuria is the main cause of uric acid stone formation in children. A daily output of uric acid of more than 10 mg/kg/day is considered to be hyperuricosuria (5).

The formation of uric acid stones is mainly dependent on the presence of acidic urinary composition. Uric acid dissociation and solubility is strongly reduced at pH of less than 5.8. As the pH becomes more alkaline, uric acid crystals become more soluble and the risk of uric acid stone formation is reduced.

In the familial or idiopathic form of hyperuricosuria, children usually have normal serum uric acid levels. In other children, it can be caused by uric acid overproduction secondary to inborn errors of metabolism, myeloproliferative disorders or other causes of cell breakdown. Hyperuricosuria is also caused by high purine and protein intake. Although hyperuricosuria is a risk factor for calcium oxalate stone formation in adults, this does not appear to be a significant risk factor in children.

Uric acid stones are non-opaque stones. Plain X-rays are insufficient to show uric acid stones, and renal sonography and spiral CT are used for diagnosis.

Alkalinisation of urine is the mainstay of therapy and prevention for uric acid stones. Citrate preparations are useful as alkalinising agents. Maintaining a urine pH of 6 to 6.5 is sufficient to prevent uric acid stones (5).

15.2.3 **Cystine stones**

Cystinuria is the cause of cystine stone formation and accounts for 2-6% of all urinary stones in children. Cystinuria is an incompletely recessive autosomal disorder characterised by failure of renal tubules to reabsorb four basic amino acids: cystine, ornithine, lysine and arginine.

Of these four amino acids, only cystine has poor solubility in urine, so that only cystine stones may form in the case of excessive excretion in urine. Cystine solubility is pH-dependent, with cystine precipitation beginning at pH levels < 7.0. Other metabolic conditions, such as hypercalciuria, hypocitraturia and hyperuricosuria, may accompany cystinuria, so leading to the formation of mixed-composition stones.

Cystine stones are faintly radiolucent and may be difficult to show on regular radiograph studies. They are also hard in texture and more difficult to disintegrate by extracorporeal shock wave lithotripsy (SWL).

The medical treatment for cystine stones aims to reduce cystine saturation in urine and increase its solubility. The initial treatment consists of maintaining a high urine flow and the use of alkalinising agents, such as potassium citrate to maintain urine pH at above 7.0. If this treatment fails, the use of α -mercaptopyronil glycine may reduce cystine levels in urine and prevent stone formation. Use of these drugs can be associated with severe side effects, such as bone marrow depression and nephrotic syndrome (16) (LE: 4; GR: C).

15.2.4 **Infection stones (struvite stones)**

Infection-related stones constitute nearly 5% of urinary stones in children. Bacteria capable of producing urease enzyme (*Proteus*, *Klebsiella*, *Pseudomonas*) are responsible for the formation of such stones.

Urease converts urea into ammonia and bicarbonate, so alkalinizing the urine and further converting bicarbonate into carbonate. In the alkaline environment, triple phosphates form, eventually resulting in a supersaturated environment of magnesium ammonium phosphate and carbonate apatite, which in turn leads to stone formation.

In addition to bacterial elimination, stone elimination is essential for treatment, as stones will harbour infection and antibiotic treatment will not be effective. Consideration should be given to investigating any congenital problem that causes stasis and infection. Genitourinary tract anomalies predispose to formation of such stones.

15.3 Clinical presentation

Presentation tends to be age-dependent, with symptoms such as flank pain and haematuria being more common in older children. Non-specific symptoms (e.g. irritability, vomiting) are common in very young children. Haematuria, usually gross, occurring with or without pain, is less common in children. However, microscopic haematuria may be the sole indicator and is more common in children. In some cases, urinary infection may be the only finding leading to radiological imaging in which a stone is identified (174,18).

15.4 Diagnosis

15.4.1 Imaging

Generally, ultrasonography should be used as a first study. Renal ultrasonography is very effective for identifying stones in the kidney. Many radiopaque stones can be identified with a simple abdominal flat-plate examination.

If no stone is found but symptoms persist, spiral CT scanning is indicated. The most sensitive test for identifying stones in the urinary system is non-contrast helical CT scanning. It is safe and rapid, with 97% sensitivity and 96% specificity (19-21) (LE: 2; GR: B).

Intravenous pyelography is rarely used in children, but may be needed to delineate the caliceal anatomy prior to percutaneous or open surgery.

15.4.2 Metabolic evaluation

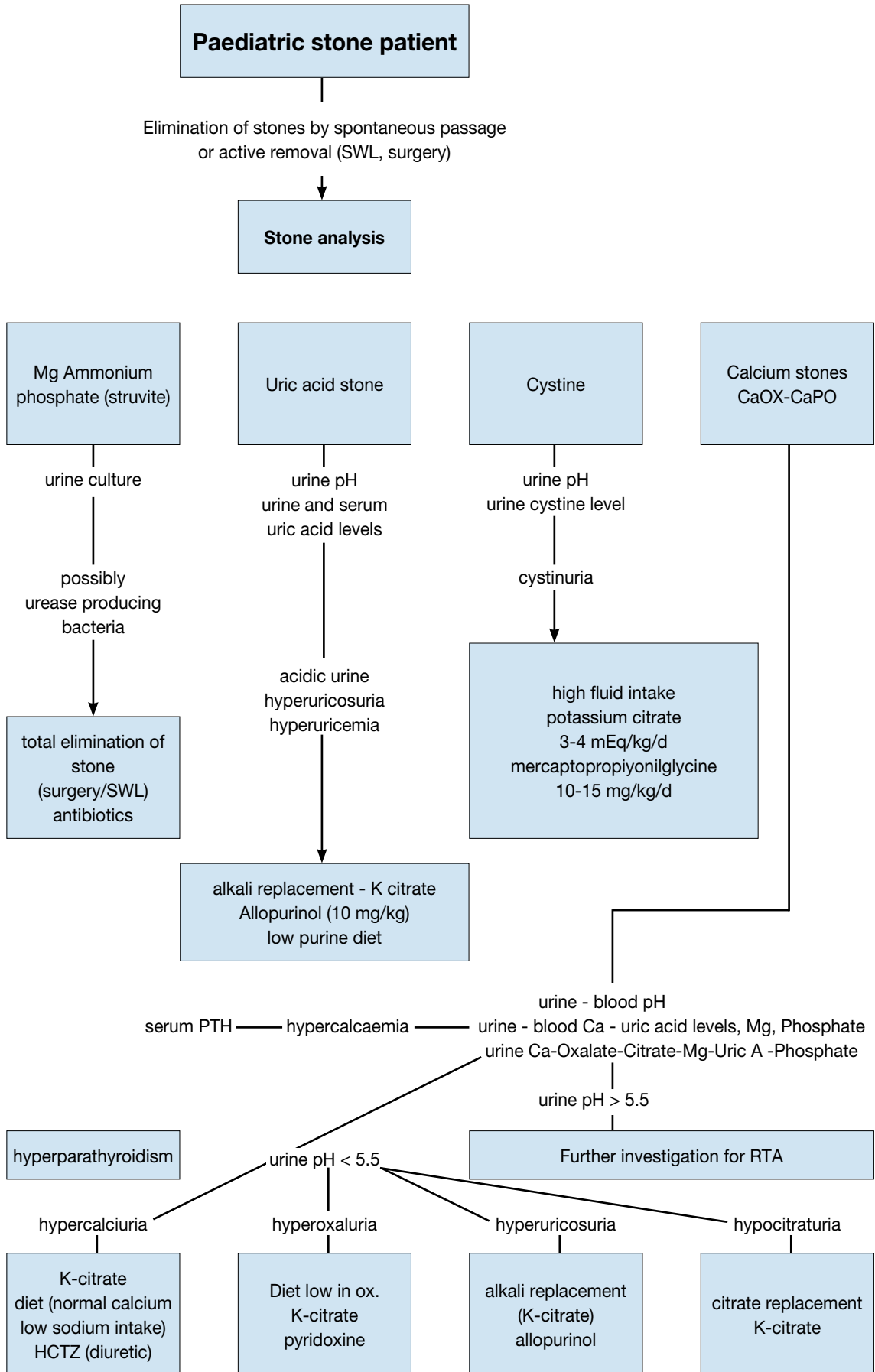
Due to the high incidence of predisposing factors for urolithiasis in children and high stone recurrence rates, every child with urinary stone should be given a complete metabolic evaluation (1,22,23).

Metabolic evaluation includes:

- Family and patient history of metabolic problems.
- Analysis of stone composition (following stone analysis, metabolic evaluation can be modified according to the specific stone type).
- Electrolytes, BUN, creatinine, calcium, phosphorus, alkaline phosphatase, uric acid, total protein, carbonate, albumin, and parathyroid hormone (if there is hypercalcaemia).
- Spot urinalysis and culture, including ratio of calcium to creatinine.
- Urine tests, including a 24-hour urine collection for calcium, phosphorus, magnesium, oxalate, uric acid citrate, cystine, protein, and creatinine clearance.

Figure 4 provides an algorithm of how to perform metabolic investigations in urinary stone disease in children and to plan medical treatment accordingly.

Figure 4: Algorithm for metabolic investigations in urinary stone disease in children



SWL = extracorporeal shockwave lithotripsy; HCTZ = hydrochlorothiazide; PTH = parathyroid hormone; RTA = renal tubular acidosis.

15.5 Management

With the advance of technology stone management has changed from open surgical approach to endoscopic techniques that are less invasive. Deciding the form of treatment depends on the number, size, location, composition and anatomy of the urinary tract (22,24,25).

Currently, most paediatric stones can easily be managed by SWL. Endoscopic treatment can be applied easily for ureteric and bladder stones. Percutaneous removal of stones is also possible for kidney stones in children. Only a small portion of children will need an open surgical approach.

15.5.1 *Extracorporeal shock wave lithotripsy (SWL)*

Many reports confirm that SWL can be performed in children with no suspicion of long-term morbidity of the kidney (26-31).

The mean number of shock waves for each treatment is about 1800 and 2000 (up to 4000 if needed) and the mean power set varies between 14 kV and 21 kV. The use of ultrasonography and digital fluoroscopy has significantly decreased the radiation exposure and it has been shown that children are exposed to significantly lower doses of radiation compared to adults (24,32,33). Concerns about anaesthesia do not seem to be a problem anymore because of advances in technique and medication, even in the infant period. The type of anaesthesia should be general or dissociative for children under 10 years of age, whereas conventional intravenous sedation or patient-controlled analgesia is an option for older children who are able to co-operate (34) (LE: 2b).

Stone-free rates are significantly affected by various factors. Regardless of the location, as the stone size increases, the stone-free rates decrease and re-treatment rate increases. The stone-free rates for < 1 cm, 1-2 cm, > 2 cm and overall, were reported as nearly 90%, 80%, 60% and 80%, respectively. As the stone size increases, the need for additional sessions increases (24,32,33,35-39).

Localisation of the calculi has been described as a significant factor affecting the success rates in different studies. Stones in renal pelvis and upper ureter seem to respond better to SWL. In these mentioned sites, the stone clearance rates are nearly 90%. However, SWL was found to be less effective for caliceal stones particularly the lower caliceal stones. Several studies reported stone-free rates for isolated lower caliceal stones varying between 50% and 62% (40-43).

Shockwave lithotripsy can also be used to treat ureteral calculi. However, this is a more specific issue and with controversies. The success rates with SWL are less for distal ureteric stones. There may also be technical problems with localisation and focusing of ureteric stones in children (40,42-45).

The type of machine used has a strong effect on success rates and complications. First-generation machines can deliver more energy to a larger focal zone, resulting in higher fragmentation rates in a single therapy. However, general anaesthesia is usually required due to the intolerable discomfort associated with a first-generation machine. Later-generation machines have a smaller focal zone and deliver less energy, and have a lower risk of pulmonary trauma. However, additional treatments may be needed with later-generation machines. The success rate is higher in younger children (38).

Although stenting does not affect stone clearance, overall complication rates are higher and hospital stay is longer in the unstented patient (37,38). Stenting is essential in solitary kidneys undergoing SWL treatment. Children with a large stone burden have a high risk of developing Steinstrasse and urinary obstruction and should be followed more closely for the risk of prolonged urinary tract obstruction after SWL.

Post-SWL stent or nephrostomy tube placement may be needed in prolonged obstruction (23,39).

Complications arising from SWL in children are usually self-limiting and transient. The most common complications are:

- renal colic;
- transient hydronephrosis;
- dermal ecchymosis;
- urinary tract infection;
- formation of Steinstrasse;
- sepsis;
- rarely, haemoptysis.

In children with sterile pre-operative urine cultures, antibiotic prophylaxis to decrease infectious complications is not recommended (46). However, every effort should be made to sterilize the urine before performing SWL, ureteroscopy (URS), or percutaneous nephrolithotomy (PCNL).

15.5.2 *Percutaneous nephrolithotomy*

Shockwave lithotripsy is the first choice for treating most renal paediatric stones. However, percutaneous renal surgery can be used for larger and complex stones. Pre-operative evaluation, indication and surgical technique

are similar in children compared to adults. Percutaneous nephrolithotomy is used as monotherapy in most cases, but is also used as an adjunctive procedure to other therapies.

The use of adult-sized instruments, in association with an increased number of tracts and sheath size, seems to increase blood loss. However, the development of small-calibre instruments means that PCNL can be used in children. Percutaneous nephrolithotomy has some advantages for children (particularly smaller children), such as smaller skin incision, single-step dilation and sheath placement, good working access for paediatric instruments, variable length, and lower cost (46,47).

As monotherapy, PCNL is considerably effective and safe. The reported stone-free rates in the recent literature are between 86.9% and 98.5% after a single session. These rates increase with adjunctive measures, such as second-look PCNL, SWL and URS. Even in complete staghorn cases, a clearance rate of 89% has been achieved following a single session (48-51,53,54).

The most frequently reported complications of PCNL in children are bleeding, post-operative fever or infection, and persistent urinary leakage. Bleeding requiring transfusion in the modern series is reported in less than 10% (55-60) and is closely associated with stone burden, operative time, sheath size and the number of tracts (60,61). In recent studies, post-operative infectious complications, such as fever with or without documented UTI, are reported as less than 15% (55,56,58-60,62) and the origin of fever is not always found to be the infection. With the availability of smaller size instruments, miniaturized PCNL ('mini-perc') through a 13F or 14F sheath has become possible (63-65), with decreased transfusion rates (65). This miniaturization has been further developed into the technique of 'micro-perc' using a 4.85F 'all-seeing needle'. This technique is still experimental and enables the stone to be fragmented by a laser *in situ* and left for spontaneous passage (66). As experience has accumulated in adult cases, new approaches have also started to be applied in children, including tubeless PCNL. This technique has been used in uncomplicated surgery for stones smaller than 2 cm, with patients left either with an indwelling catheter or double J stent in the ureter (67,68) or totally tubeless (69).

The mean post-operative hospital stay is similar to adults. It is reported as 3-4 days in all published literature and is much shorter than open surgery. The less invasive nature of this technique has made it a promising alternative to open surgery for treating renal stones in children (LE: 2; GR: B).

15.5.3 Ureterorenoscopy

The increasing availability of smaller size endourological equipment has made it possible to manage paediatric ureteral stones using endoscopic techniques.

The technique used in children is similar to the one used in adults. It is strongly recommended that guide wires are used and the procedure is performed using direct vision. Routine balloon dilation of ureterovesical junction and ureteral stenting are controversial. In general, ureteric dilatation is being performed much less and only in selected cases. There is a tendency to use hydrodilation more because it is similarly effective (46,70-73,74-76) (LE: 3; GR: B).

Different lithotripsy techniques, including ultrasonic, pneumatic and laser lithotripsy, have all been shown to be safe and effective. Because of the smaller size of the probes, laser energy is easier to use in smaller instruments and is more useful for paediatric cases (53,71,73,77-83).

All studies reporting the use of endoscopy for ureteric stones in children have clearly demonstrated that there is no significant risk of ureteric strictures or reflux with this mode of therapy (LE: 1; GR: A). A multi-institutional study on the use of semi-rigid ureteroscopy for ureteral calculi in children has revealed that the procedure is effective with a 90% stone-free rate and efficacy quotient. The study also focused on the factors affecting the complication rates. The authors found that although operating time, age, institutional experience, orifice dilation, stenting and stone burden were significant on univariate analysis, multivariate analysis revealed that operating time was the only significant parameter affecting the complication rate (84).

A recent literature review contains a growing number of case series on the use of flexible ureterorenoscopic interventions in children. Both intrarenal and ureteric stones can be treated using this approach (85-89). In these series, the authors generally did not use active orifice dilation, but attempted to use a ureteral sheath where possible. However, an important problem was the inability to obtain retrograde access to the ureter in approximately half of the cases (87,88). This problem can be overcome by stenting and leaving the stent indwelling for passive dilation of the orifice, and performing the procedure in a second session. The success rates varied between 60 and 100%, with a negligible number of complications (85-87,89). The need for additional procedures was related to stone size (85). Although the use of flexible instruments seems feasible for the present time, more data are needed for comparison with other endourological modalities in children.

15.5.4 Open stone surgery

Most stones in children can be managed by SWL and endoscopic techniques. However, in some situations, open surgery is inevitable. Good candidates for open stone surgery include very young children with large stones and/or a congenitally obstructed system, which also requires surgical correction. Open surgery is also necessary in children with severe orthopaedic deformities that limit positioning for endoscopic procedures.

In centres with a well-established experience, a laparoscopic approach may be a good alternative for some cases as a last resort before open surgery. Suitable candidates include patients who have a history of previous failed endoscopic procedures, complex renal anatomy (ectopic or retrorenal colon), concomitant ureteropelvic junction obstruction or caliceal diverticula, megaureter, or large impacted stones. Laparoscopic stone surgery via conventional or a robot-assisted transperitoneal or retroperitoneal approach can be attempted. However, there is very limited experience with these techniques and they are not routine therapeutic modalities (90,91).

Bladder stones in children can usually be managed by endoscopic techniques. Open surgery may also be used for very large bladder stones or for bladder stones caused by an anatomical problem.

Recommendations for interventional management are given in Table 11.

Table 11: Recommendations for interventional management in paediatric stones

Stone size and localisation*	Primary treatment option	LE GR	Secondary treatment options	Comment
Staghorn stones	PCNL	2B	Open/SWL	Multiple sessions and accesses with PCNL may be needed. Combination with SWL may be useful.
Pelvis < 10 mm	SWL	1A	RIRS/PCNL	
Pelvis 10-20 mm	SWL	2B	PCNL/Open	Multiple sessions with SWL may be needed. PCNL has similar recommendation grade.
Pelvis > 20 mm	PCNL	2B	SWL/Open	Multiple sessions with SWL may be needed.
Lower pole calyx < 10 mm	SWL	2B	RIRS/PCNL	Anatomical variations are important for complete clearance after SWL.
Lower pole calyx > 10 mm	PCNL	2B	SWL	Anatomical variations are important for complete clearance after SWL.
Upper ureteric stones	SWL	2B	PCNL/URS/ Open	
Lower ureteric stones	URS	1A	SWL/Open	Additional intervention need is high with SWL.
Bladder stones	Endoscopic	2B		Open is easier and with less operative time with large stones.

* Cystine and uric acid stones excluded.

PCNL = percutaneous nephrolithostomy; SWL = shock-wave lithotripsy; RIRS = retrograde intrarenal surgery; URS = ureteroscopy.

15.6 Conclusions and recommendations

Conclusions	LE
The incidence of stone disease in children is increasing.	2
Any child with urinary stone disease deserves metabolic and anatomical evaluation.	2
Treatment should be supported with medical treatment for the underlying metabolic abnormality if detected.	1
Open surgery for stone disease in children is an exceedingly rare requirement.	1
Surgical treatment is based on minimally invasive modalities.	1

Recommendations	LE	GR
In most cases, plain abdominal X-ray and ultrasonography is sufficient for diagnosis and follow-up.	2	B
Non-contrast CT may be required in cases with a doubtful diagnosis or complex cases requiring surgery.	2	B
The use of appropriate-size instruments will decrease the number of complications in surgical treatment.	1	A

15.7 References

1. Straub M, Strohmaier WL, Berg W, et al. Diagnosis and metaphylaxis of stone disease. Consensus concept of the National Working Committee on Stone Disease for the Upcoming German Urolithiasis Guideline. *World J Urol* 2005 Nov;23(5):309-23.
<http://www.ncbi.nlm.nih.gov/pubmed/16315051>
2. Bush NC, Xu L, Brown BJ, et al. Hospitalizations for pediatric stone disease in United States, 2002-2007. *J Urol* 2010 Mar;183(3):1151-6.
<http://www.ncbi.nlm.nih.gov/pubmed/20096871>
3. Novak TE, Lakshmanan Y, Trock BJ, et al. Sex prevalence of pediatric kidney stone disease in the United States: an epidemiologic investigation. *Urology* 2009 Jul;74(1):104-7.
<http://www.ncbi.nlm.nih.gov/pubmed/19428065>
4. Sas DJ, Hulseley TC, Shatat IF, et al. Increasing incidence of kidney stones in children evaluated in the emergency department. *J Pediatr* 2010 Jul;157(1):132-7.
<http://www.ncbi.nlm.nih.gov/pubmed/20362300>
5. Bartosh SM. Medical management of pediatric stone disease. *Urol Clin North Am* 2004 Aug;31(3):575-87.
<http://www.ncbi.nlm.nih.gov/pubmed/15313066>
6. Kruse K, Kracht U, Kruse U. Reference values for urinary calcium excretion and screening for hypercalciuria in children and adolescents. *Eur J Pediatr* 1984 Nov;143(1):23-31.
<http://www.ncbi.nlm.nih.gov/pubmed/6510426>
7. Sargent JD, Stukel TA, Kresel J, et al. Normal values for random urinary calcium to creatinine ratios in infancy. *J Pediatr* 1993 Sep;123(3):393-7.
<http://www.ncbi.nlm.nih.gov/pubmed/8355114>
8. Stapleton FB, Noe HN, Roy S 3rd, et al. Hypercalciuria in children with urolithiasis. *Am J Dis Child* 1982 Aug;136(8):675-8.
<http://www.ncbi.nlm.nih.gov/pubmed/7102617>
9. Stapleton FB, Noe HN, Roy S 3rd, et al. Urinary excretion of calcium following an oral calcium loading test in healthy children. *Pediatrics* 1982 May;69(5):594-7.
<http://www.ncbi.nlm.nih.gov/pubmed/7079015>
10. Borghi L, Schianchi T, Meschi T, et al. Comparison of two diets for the prevention of recurrent stones in idiopathic hypercalciuria. *N Engl J Med* 2002 Jan;346(2):77-84.
<http://www.ncbi.nlm.nih.gov/pubmed/11784873>
11. Preminger GM, Pak CY. Eventual attenuation of hypocalciuric response to hydrochlorothiazide in absorptive hypercalciuria. *J Urol* 1987 Jun;137(6):1104-9.
<http://www.ncbi.nlm.nih.gov/pubmed/3586136>
12. Tekin A, Tekgul S, Atsu N, et al. Oral potassium citrate treatment for idiopathic hypocitruria in children with calcium urolithiasis. *J Urol* 2002 Dec;168(6):2572-4.
<http://www.ncbi.nlm.nih.gov/pubmed/12441986>
13. Morgenstern BZ, Milliner DS, Murphy ME, et al. Urinary oxalate and glycolate excretion patterns in the first year of life: a longitudinal study. *J Pediatr* 1993 Aug;123(2):248-51.
<http://www.ncbi.nlm.nih.gov/pubmed/8345420>
14. Defoor W, Asplin J, Jackson E, et al. Results of a prospective trial to compare normal urine supersaturation in children and adults. *J Urol* 2005 Oct;174(4 Pt 2):1708-10.
<http://www.ncbi.nlm.nih.gov/pubmed/16148687>
15. Tekin A, Tekgul S, Atsu N, et al. A study of the etiology of idiopathic calcium urolithiasis in children: hypocitruria is the most important risk factor. *J Urol* 2000 Jul;164(1):162-5.
<http://www.ncbi.nlm.nih.gov/pubmed/10840454>
16. Tekin A, Tekgul S, Atsu N, et al. Cystine calculi in children: the results of a metabolic evaluation and response to medical therapy. *J Urol* 2001 Jun;165(6 Pt 2):2328-30.
<http://www.ncbi.nlm.nih.gov/pubmed/11371943>
17. Bove P, Kaplan D, Dalrymple N, et al. Reexamining the value of hematuria testing in patients with acute flank pain. *J Urol* 1999 Sep;162(3 Pt 1):685-7.
<http://www.ncbi.nlm.nih.gov/pubmed/10458342>
18. Sternberg K, Greenfield SP, Williot P, et al. Pediatric stone disease: an evolving experience. *J Urol* 2005 Oct;174(4 Pt 2):1711-4.
<http://www.ncbi.nlm.nih.gov/pubmed/16148688>
19. Oner S, Oto A, Tekgul S, et al. Comparison of spiral CT and US in the evaluation of paediatric urolithiasis. *JBR-BTR* 2004 Sep-Oct;87(5):219-23.
<http://www.ncbi.nlm.nih.gov/pubmed/15587558>

20. Memarsadeghi M, Heinz-Peer G, Helbich TH, et al. Unenhanced multi-detector row CT in patients suspected of having urinary stone disease: effect of section width on diagnosis. *Radiology* 2005 May;235(2):530-6.
<http://www.ncbi.nlm.nih.gov/pubmed/15758192>
21. Strouse PJ, Bates DG, Bloom DA, et al. Non-contrast thin-section helical CT of urinary tract calculi in children. *Pediatr Radiol* 2002 May;32(5):326-32.
<http://www.ncbi.nlm.nih.gov/pubmed/11956719>
22. Tiselius HG, Ackermann D, Alken P, et al; Working Party on Lithiasis, European Association of Urology. Guidelines on urolithiasis. *Eur Urol* 2001 Oct;40(4):362-71.
<http://www.ncbi.nlm.nih.gov/pubmed/11713390>
23. Tekin A, Tekgul S, Atsu N, et al. Ureteropelvic junction obstruction and coexisting renal calculi in children: role of metabolic abnormalities. *Urology* 2001 Mar;57(3):542-5.
<http://www.ncbi.nlm.nih.gov/pubmed/11248635>
24. Raza A, Turna B, Smith G, et al. Paediatric urolithiasis: 15 years of local experience with minimally invasive endourological management of paediatric calculi. *J Urol* 2005 Aug;174(2):682-5.
<http://www.ncbi.nlm.nih.gov/pubmed/16006948>
25. Rizvi SA, Naqvi SA, Hussain Z, et al. Paediatric urolithiasis: developing nation perspectives. *J Urol* 2002 Oct;168(4 Pt 1):1522-5.
<http://www.ncbi.nlm.nih.gov/pubmed/12352448>
26. Willis LR, Evan AP, Connors BA, et al. Relationship between kidney size, renal injury, and renal impairment induced by shock wave lithotripsy. *J Am Soc Nephrol* 1999 Aug;10(8):1753-62.
<http://www.ncbi.nlm.nih.gov/pubmed/10446943>
27. Villanyi KK, Szekely JG, Farkas LM, et al. Short-term changes in renal function after extracorporeal shock wave lithotripsy in children. *J Urol* 2001 Jul;166(1):222-4.
<http://www.ncbi.nlm.nih.gov/pubmed/11435873>
28. Aldridge RD, Aldridge RC, Aldridge LM. Anesthesia for pediatric lithotripsy. *Paediatr Anaesth* 2006 Mar;16(3):236-41.
<http://www.ncbi.nlm.nih.gov/pubmed/16490086>
29. McLorie GA, Pugach J, Pode D, et al. Safety and efficacy of extracorporeal shock wave lithotripsy in infants. *Can J Urol* 2003 Dec;10(6):2051-5.
<http://www.ncbi.nlm.nih.gov/pubmed/14704109>
30. Aksoy Y, Ozbey I, Atmaca AF, et al. Extracorporeal shock wave lithotripsy in children: experience using a mpl-9000 lithotripter. *World J Urol* 2004 Jun;22(2):115-9.
<http://www.ncbi.nlm.nih.gov/pubmed/14740160>
31. Vljakovic M, Slavkovic A, Radovanovic M, et al. Long-term functional outcome of kidneys in children with urolithiasis after ESWL treatment. *Eur J Pediatr Surg* 2002 Apr;12(2):118-23.
<http://www.ncbi.nlm.nih.gov/pubmed/12015657>
32. Muslumanoglu AY, Tefekli A, Sarilar O, et al. Extracorporeal shock wave lithotripsy as first line treatment alternative for urinary tract stones in children: a large scale retrospective analysis. *J Urol* 2003 Dec;170(6 Pt 1):2405-8.
<http://www.ncbi.nlm.nih.gov/pubmed/14634438>
33. Ather MH, Noor MA. Does size and site matter for renal stones up to 30-mm in size in children treated by extracorporeal lithotripsy? *Urology* 2003 Jan;61(1):212-5; discussion 215.
<http://www.ncbi.nlm.nih.gov/pubmed/12559298>
34. Ugur G, Erhan E, Kocabas S, et al. Anaesthetic/analgesic management of extracorporeal shock wave lithotripsy in paediatric patients. *Paediatr Anaesth* 2003 Jan;13(1):85-7.
<http://www.ncbi.nlm.nih.gov/pubmed/12535048>
35. Rodrigues Netto N Jr, Longo JA, Ikonomidis JA, et al. Extracorporeal shock wave lithotripsy in children. *J Urol* 2002 May;167(5):2164-6.
<http://www.ncbi.nlm.nih.gov/pubmed/11956471>
36. Afshar K, McLorie G, Papanikolaou F, et al. Outcome of small residual stone fragments following shock wave lithotripsy in children. *J Urol* 2004 Oct;172(4 Pt 2):1600-3.
<http://www.ncbi.nlm.nih.gov/pubmed/15371769>
37. Tan AH, Al-Omar M, Watterson JD, et al. Results of shockwave lithotripsy for pediatric urolithiasis. *J Endourol* 2004 Aug;18(6):527-30.
<http://www.ncbi.nlm.nih.gov/pubmed/15333214>
38. Lottmann HB, Traxer O, Archambaud F, et al. Monotherapy extracorporeal shock wave lithotripsy for the treatment of staghorn calculi in children. *J Urol* 2001 Jun;165(6 Pt 2):2324-7.
<http://www.ncbi.nlm.nih.gov/pubmed/11371942>

39. Al-Busaidy SS, Prem AR, Medhat M. Pediatric staghorn calculi: the role of extracorporeal shock wave lithotripsy monotherapy with special reference to ureteral stenting. *J Urol* 2003 Feb;169(2):629-33. <http://www.ncbi.nlm.nih.gov/pubmed/12544330>
40. Ozgur Tan M, Karaoglan U, Sozen S, et al. Extracorporeal shock-wave lithotripsy for treatment of ureteral calculi in paediatric patients. *Pediatr Surg Int* 2003 Aug;19(6):471-4. <http://www.ncbi.nlm.nih.gov/pubmed/12736749>
41. Demirkesen O, Onal B, Tansu N, et al. Efficacy of extracorporeal shock wave lithotripsy for isolated lower caliceal stones in children compared with stones in other renal locations. *Urology* 2006 Jan;67(1):170-174; discussion 174-5. <http://www.ncbi.nlm.nih.gov/pubmed/16413356>
42. Ozgur Tan M, Karaoglan U, Sen I, et al. The impact of radiological anatomy in clearance of lower calyceal stones after shock wave lithotripsy in paediatric patients. *Eur Urol* 2003 Feb;43(2):188-93. <http://www.ncbi.nlm.nih.gov/pubmed/12565778>
43. Onal B, Demirkesen O, Tansu N, et al. The impact of caliceal pelvic anatomy on stone clearance after shock wave lithotripsy for pediatric lower pole stones. *J Urol* 2004 Sep;172(3):1082-6. <http://www.ncbi.nlm.nih.gov/pubmed/15311043>
44. Landau EH, Gofrit ON, Shapiro A, et al. Extracorporeal shock wave lithotripsy is highly effective for ureteral calculi in children. *J Urol* 2001 Jun;165(6 Pt 2):2316-9. <http://www.ncbi.nlm.nih.gov/pubmed/11371970>
45. Hochreiter WW, Danuser H, Perrig M, et al. Extracorporeal shock wave lithotripsy for distal ureteral calculi: what a powerful machine can achieve. *J Urol* 2003 Mar;169(3):878-80. <http://www.ncbi.nlm.nih.gov/pubmed/12576804>
46. Wu HY, Docimo SG. Surgical management of children with urolithiasis. *Urol Clin North Am* 2004 Aug;31(3):589-94. <http://www.ncbi.nlm.nih.gov/pubmed/15313067>
47. Jackman SV, Hedican SP, Peters CA, et al. Percutaneous nephrolithotomy in infants and preschool age children: experience with a new technique. *Urology* 1998 Oct;52(4):697-701. <http://www.ncbi.nlm.nih.gov/pubmed/9763096>
48. Sahin A, Tekgul S, Erdem E, et al. Percutaneous nephrolithotomy in older children. *J Pediatr Surg* 2000 Sep;35(9):1336-8. <http://www.ncbi.nlm.nih.gov/pubmed/10999692>
49. Shokeir AA, El-Nahas AR, Shoma AM, et al. Percutaneous nephrolithotomy in treatment of large stones within horseshoe kidneys. *Urology* 2004 Sep;64(3):426-9. <http://www.ncbi.nlm.nih.gov/pubmed/15351557>
50. Boormans JL, Scheepe JR, Verkoelen CF, et al. Percutaneous nephrolithotomy for treating renal calculi in children. *BJU Int* 2005 Mar;95(4):631-4. <http://www.ncbi.nlm.nih.gov/pubmed/15705093>
51. MS, Shokeir AA, Hafez AT, et al. Percutaneous nephrolithotomy in children: early and late anatomical and functional results. *J Urol* 2004 Sep;172(3):1078-81. <http://www.ncbi.nlm.nih.gov/pubmed/15311042>
52. Zeren S, Satar N, Bayazit Y, et al. Percutaneous nephrolithotomy in the management of pediatric renal calculi. *J Endourol* 2002 Mar;16(2):75-8. <http://www.ncbi.nlm.nih.gov/pubmed/11962558>
53. Desai MR, Kukreja RA, Patel SH, et al. Percutaneous nephrolithotomy for complex paediatric renal calculus disease. *J Endourol* 2004 Feb;18(1):23-7. <http://www.ncbi.nlm.nih.gov/pubmed/15006048>
54. Badawy H, Salama A, Eissa M, et al. Percutaneous management of renal calculi: experience with percutaneous nephrolithotomy in 60 children. *J Urol* 1999 Nov;162(5):1710-3. <http://www.ncbi.nlm.nih.gov/pubmed/10524919>
55. Nouralizadeh A, Basiri A, Javaherforooshzadeh A, et al. Experience of percutaneous nephrolithotomy using adult-size instruments in children less than 5 years old. *J Pediatr Urol* 2009 Oct;5(5):351-4. <http://www.ncbi.nlm.nih.gov/pubmed/19230776>
56. Unsal A, Resorlu B, Kara C, et al. Safety and efficacy of percutaneous nephrolithotomy in infants, preschool age, and older children with different sizes of instruments. *Urology* 2010 Jul;76(1):247-52. <http://www.ncbi.nlm.nih.gov/pubmed/20022089>
57. Khairy Salem H, Morsi HA, Omran A, et al. Tubeless percutaneous nephrolithotomy in children. *J Pediatr Urol* 2007 Jun;3(3):235-8. <http://www.ncbi.nlm.nih.gov/pubmed/18947742>

58. Dogan HS, Kilicarslan H, Kordan Y, et al. Percutaneous nephrolithotomy in children: does age matter? *World J Urol* 2011 Dec;29(6):725-9.
<http://www.ncbi.nlm.nih.gov/pubmed/21590468>
59. Guven S, Istanbuluoglu O, Gul U, et al. Successful percutaneous nephrolithotomy in children: Multicenter study on current status of its use, efficacy and complications using Clavien classification. *J Urol* 2011 Apr;185(4):1419-24.
<http://www.ncbi.nlm.nih.gov/pubmed/21334653>
60. Ozden E, Mercimek MN, Yakupoglu YK, et al. Modified Clavien classification in percutaneous nephrolithotomy: Assessment of complications in children. *J Urol* 2011 Jan, 185(1):264-8.
<http://www.ncbi.nlm.nih.gov/pubmed/21074805>
61. Ozden E, Sahin A, Tan B, et al. Percutaneous renal surgery in children with complex stones. *J Pediatr Urol* 2008 Aug;4(4):295-8.
<http://www.ncbi.nlm.nih.gov/pubmed/18644533>
62. Bilen CY, Gunay M, Ozden E, et al. Tubeless mini percutaneous nephrolithotomy in infants and preschool children: a preliminary report. *J Urol* 2010 Dec;184(6):2498-502.
<http://www.ncbi.nlm.nih.gov/pubmed/20961572>
63. Jackman SV, Docimo SG, Cadeddu JA, et al. The "mini-perc" technique: a less invasive alternative to percutaneous nephrolithotomy. *World J Urol* 1998;16(6):371-4.
<http://www.ncbi.nlm.nih.gov/pubmed/9870281>
64. Jackman SV, Hedican SP, Peters CA, et al. Percutaneous nephrolithotomy in infants and preschool age children: experience with a new technique. *Urology* 1998 Oct;52(4):697-701.
<http://www.ncbi.nlm.nih.gov/pubmed/9763096>
65. Bilen CY, Koçak B, Kitirci G, et al. Percutaneous nephrolithotomy in children: lessons learned in 5 years at a single institution. *J Urol* 2007 May;177(5):1867-71.
<http://www.ncbi.nlm.nih.gov/pubmed/17437838>
66. Desai MR, Sharma R, Mishra S, et al. Single-step percutaneous nephrolithotomy (microperc): the initial clinical report. *J Urol* 2011 Jul;186(1):140-5.
<http://www.ncbi.nlm.nih.gov/pubmed/21575966>
67. Khairy Salem H, Morsi HA, Omran A, et al. Tubeless percutaneous nephrolithotomy in children. *J Pediatr Urol* 2007 Jun;3(3):235-8.
<http://www.ncbi.nlm.nih.gov/pubmed/18947742>
68. Bilen CY, Gunay M, Ozden E, et al. Tubeless mini percutaneous nephrolithotomy in infants and preschool children: a preliminary report. *J Urol* 2010 Dec;184(6):2498-502.
<http://www.ncbi.nlm.nih.gov/pubmed/20961572>
69. Aghamir SM, Salavati A, Aloosh M, et al. Feasibility of totally tubeless percutaneous nephrolithotomy under the age of 14 years: a randomized clinical trial. *J Endourol* 2012 Jun;26(6):621-4.
<http://www.ncbi.nlm.nih.gov/pubmed/22192104>
70. Hill DE, Segura JW, Patterson DE, et al. Ureteroscopy in children. *J Urol* 1990 Aug;144(2 Pt 2):481-3; discussion 492-3.
<http://www.ncbi.nlm.nih.gov/pubmed/2374224>
71. Caione P, De Gennaro M, Capozza N, et al. Endoscopic manipulation of ureteral calculi in children by rigid operative ureterorenoscopy. *J Urol* 1990 Aug;144(2 Pt 2):484-5; discussion 492-3.
<http://www.ncbi.nlm.nih.gov/pubmed/2374225>
72. Minevich E, Defoor W, Reddy P, et al. Ureteroscopy is safe and effective in prepubertal children. *J Urol* 2005 Jul;174(1):276-9.
<http://www.ncbi.nlm.nih.gov/pubmed/15947666>
73. Soygur T, Zumrutbas AE, Gulpinar O, et al. Hydrodilation of the ureteral orifice in children renders ureteroscopic access possible without any further active dilation. *J Urol* 2006 Jul;176(1):285-7; discussion 287.
<http://www.ncbi.nlm.nih.gov/pubmed/16753421>
74. Al Busaidy SS, Prem AR, Medhat M. Paediatric ureteroscopy for ureteric calculi: a 4-year experience. *Br J Urol* 1997 Nov;80(5):797-801.
<http://www.ncbi.nlm.nih.gov/pubmed/9393306>
75. Schuster TG, Russell KY, Bloom DA, et al. Ureteroscopy for the treatment of urolithiasis in children. *J Urol* 2002 Apr;167(4):1813-5; discussion 1815-6.
<http://www.ncbi.nlm.nih.gov/pubmed/11912438>
76. Richter S, Shalev M, Lobik L, et al. Early postoperative vesicoureteral refluxa temporary and infrequent complication: prospective study. *J Endourol* 1999 Jun;13(5):365-6.
<http://www.ncbi.nlm.nih.gov/pubmed/10446797>

77. Van Savage JG, Palanca LG, Andersen RD, et al. Treatment of distal ureteral stones in children: similarities to the american urological association guidelines in adults. *J Urol* 2000 Sep;164 (3 Pt 2): 1089-93.
<http://www.ncbi.nlm.nih.gov/pubmed/10958749>
78. Bassiri A, Ahmadnia H, Darabi MR, et al. Transureteral lithotripsy in pediatric practice. *J Endourol* 2002 May;16(4):257-60.
<http://www.ncbi.nlm.nih.gov/pubmed/12042111>
79. Raza A, Smith G, Moussa S, et al. Ureteroscopy in the management of pediatric urinary tract calculi. *J Endourol* 2005 Mar ;19(2):151-8.
<http://www.ncbi.nlm.nih.gov/pubmed/15798409>
80. Satar N, Zeren S, Bayazit Y, et al. Rigid ureteroscopy for the treatment of ureteral calculi in children. *J Urol* 2004 Jul;172(1):298-300.
<http://www.ncbi.nlm.nih.gov/pubmed/15201799>
81. De Dominicis M, Matarazzo E, Capozza N, et al. Retrograde ureteroscopy for distal ureteric stone removal in children. *BJU Int* 2005 May;95(7):1049-52.
<http://www.ncbi.nlm.nih.gov/pubmed/15839930>
82. Dogan HS, Tekgul S, Akdogan B, et al. Use of the holmium:YAG laser for ureterolithotripsy in children. *BJU Int* 2004 Jul;94(1):131-3.
<http://www.ncbi.nlm.nih.gov/pubmed/15217447>
83. Thomas JC, DeMarco RT, Donohoe JM, et al. Paediatric ureteroscopic stone management. *J Urol* 2005 Sep;174(3):1072-4.
<http://www.ncbi.nlm.nih.gov/pubmed/16094060>
84. Dogan HS, Onal B, Satar N, et al. Factors affecting complication rates of ureteroscopic lithotripsy in children: results of multi-institutional retrospective analysis by Pediatric Stone Disease Study Group of Turkish Pediatric Urology Society. *J Urol* 2011 Sep;186(3):1035-40.
<http://www.ncbi.nlm.nih.gov/pubmed/21784482>
85. Tanaka ST, Makari JH, Pope JC 4th, et al. Pediatric ureteroscopic management of intrarenal calculi. *J Urol* 2008 Nov;180(5):2150-3.
<http://www.ncbi.nlm.nih.gov/pubmed/18804225>
86. Dave S, Khoury AE, Braga L, et al. Single-institutional study on role of ureteroscopy and retrograde intrarenal surgery in treatment of pediatric renal calculi. *Urology* 2008 Nov;72(5):1018-21.
<http://www.ncbi.nlm.nih.gov/pubmed/18585764>
87. Kim SS, Kolon TF, Canter D, et al. Pediatric flexible ureteroscopic lithotripsy: the Children's Hospital of Philadelphia experience. *J Urol* 2008 Dec;180(6):2616-9.
<http://www.ncbi.nlm.nih.gov/pubmed/18950810>
88. Corcoran AT, Smaldone MC, Mally D, et al. When is prior ureteral stent placement necessary to access the upper urinary tract in prepubertal children? *J Urol* 2008 Oct;180(4 Suppl):1861-3.
<http://www.ncbi.nlm.nih.gov/pubmed/18721946>
89. Abu Ghazaleh LA, Shunaigat AN, Budair Z. Retrograde intrarenal lithotripsy for small renal stones in prepubertal children. *Saudi J Kidney Dis Transpl* 2011 May;22(3):492-6.
<http://www.ncbi.nlm.nih.gov/pubmed/21566306>
90. Casale P, Grady RW, Joyner BD, et al. Transperitoneal laparoscopic pyelolithotomy after failed percutaneous access in the pediatric patient. *J Urol* 2004 Aug;172(2):680-3; discussion 683.
<http://www.ncbi.nlm.nih.gov/pubmed/15247760>
91. Lee RS, Passerotti CC, Cendron M, et al. Early results of robot assisted laparoscopic lithotomy in adolescents. *J Urol* 2007 Jun;177(6):2306-9; discussion 2309-10.
<http://www.ncbi.nlm.nih.gov/pubmed/17509345>

16. OBSTRUCTIVE PATHOLOGY OF RENAL DUPLICATION: URETEROCELE AND ECTOPIC URETER

16.1 Background

Ureterocele and ectopic ureter are the two main anomalies associated with complete renal duplication, but they also occur in a single system. At present, antenatal ultrasonography detects both conditions in the

majority of cases if associated with obstruction, and diagnosis is confirmed after birth by further examination. Later in life, these anomalies are revealed by clinical symptoms: UTI, pain, calculus formation, disturbances of micturition, and urinary incontinence. There is a wide variation of symptoms in patients with ureterocele (from the asymptomatic patient to urosepsis, urinary retention and upper tract dilatation after birth).

16.1.1 Ureterocele

Ureterocele is 4-7 times more frequent in female than in male patients; the overall incidence in autopsies is around 1 in 4,000 children. Around 80% is associated with the upper pole ureter in duplicated systems and 20% in single systems. About 10% of ureteroceles are bilateral (1).

16.1.2 Ectopic ureter

Ectopic ureter is less frequent than ureterocele (10 in 19,046 autopsies), but is also more common in female patients (male to female ratio, 1:5). Some remain asymptomatic, therefore, the true incidence is difficult to determine (2). Eighty per cent of ectopic ureters are associated with complete renal duplication, however, in male patients, most ectopic ureters are associated with a single system (3,4).

16.2 Definition and classification

16.2.1 Ureterocele

Ureterocele is a cystic dilatation that develops in the intravesical part of the submucosal ureter. The aetiology remains unclear (5-7). A single-system ureterocele is associated with a kidney with one ureter, and in duplex systems, the ureterocele belongs to the upper pole.

Ureteroceles usually cause obstruction of the upper pole, but the degree of obstruction and functional impairment is variable according to the type of ureterocele and upper pole dysplasia. In the orthotopic form, there is often no or only mild obstruction, and frequently the function of the moiety is normal or slightly impaired, and the corresponding ureter may be dilated. Cystic renal dysplasia is also associated with a single system ureterocele (8,9). Vesicoureteral reflux can be observed in 50% on the ipsilateral side and 20% on the contralateral side. Reflux into the ureterocele is uncommon (10).

In the ectopic form, the upper pole is altered, frequently dysplastic, and hypo-functional or non-functional (11,12). The corresponding ureter is a megaureter. In the caeco-ureterocele (see definition below), the upper pole of the renal duplication is dysplastic and non-functional.

16.2.1.1 Ectopic (extravesical) ureterocele

If any portion of the ureterocele extends into the bladder neck or urethra, it is called an ectopic ureterocele. Ectopic ureterocele is the most common form of ureterocele (> 80%). It can be voluminous, dissociating the trigone and slipping into the urethra, and may prolapse through the urethral meatus (caeco-ureterocele). The ureterocele orifice is tight, and located in the bladder itself or below the neck. The ureter corresponding to the lower pole moiety is raised by the ureterocele and is frequently refluxing or compressed by the ureterocele, leading to an obstructive megaureter. A contralateral renal duplication is associated in 50% of cases. Occasionally, large ureteroceles are responsible for reflux or obstruction of the contralateral upper tract.

16.2.1.2 Orthotopic (intravesical) ureterocele

The intravesical or orthotopic ureterocele is completely located in the bladder. Intravesical ureteroceles are mostly combined with a single kidney system and account for about 15% of cases. It is seen more in older children or adults.

16.2.2 Ectopic ureter

The term ectopic ureter describes a ureter with the orifice located at the bladder neck, in the urethra, or outside the urinary tract. The ureter can drain the upper pole of a duplex or single system. There is a fundamental difference between the sexes. In boys, the ectopic orifice is never below the external sphincter.

In girls, the ureteral orifice may be located (13):

- in the urethra, from the bladder neck to the meatus (35%)
- in the vaginal vestibule (34%)
- in the vagina (25%)
- in the uterus and Fallopian tube (6%).

In boys, the ureteral orifice may be located (13):

- in the posterior urethra (47%)
- in the prostatic utricle (10%)
- in the seminal vesicles (33%)
- in the vas deferens or ejaculatory ducts (10%).

16.3 Diagnosis

16.3.1 Ureterocele

Prenatal ultrasound easily reveals voluminous obstructive ureteroceles (14,15). In cases with a small upper pole or a slightly obstructive ureterocele, prenatal diagnosis is difficult. If prenatal diagnosis is impossible, the following clinical symptoms, besides incidental findings, can reveal the congenital anomaly at birth or later:

- At birth, a prolapsed and sometimes strangulated ureterocele may be observed in front of the urethral orifice. In a newborn boy, it might cause acute urinary retention, simulating urethral valves.
- The early symptom of pyelonephritis in either sex may lead to the diagnosis.
- Later symptoms can include dysuria, recurrent cystitis and urgency.

In cases of prenatal diagnosis at birth, ultrasonography confirms the ureteral dilatation that ends at the upper pole of a renal duplication. It also demonstrates the presence of a ureterocele in the bladder, with a dilated ureter behind the bladder.

At this point, it is important to assess the function of the upper pole using nuclear renography of the region of interest. This is best assessed with DMSA (16-18). Magnetic resonance urography may visualise the morphological status of the upper pole and lower moieties and of the contralateral kidney. Based on the prevalence of high-grade reflux, VCUG is mandatory for identifying ipsilateral or contralateral reflux, and assessing the degree of intraurethral prolapse of the ureterocele (19).

Urethrocystoscopy may reveal the pathology in cases where it is difficult to make the differential diagnosis between ureterocele and ectopic megaureter.

16.3.2 Ectopic ureter

Most of the ectopic megaureters are diagnosed primarily by ultrasonography. In some cases, clinical symptoms can lead to diagnosis:

- In neonates: dribbling of urine, pyuria, and acute pyelonephritis.
- In young girls: permanent urinary incontinence besides normal voiding, or significant vaginal discharge as the equivalent of incontinence; an ectopic orifice may be found in the meatal region (20).
- In pre-adolescent boys: epididymitis is the usual clinical presentation and the seminal vesicle may be palpable.

Ultrasonography, radionuclide studies (DMSA), VCUG, magnetic resonance urography, high-resolution MR imaging, and cystoscopy are the diagnostic tools to assess function, to detect reflux and rule out ipsilateral compression of the lower pole and urethral obstruction (21). In some cases, the large ectopic ureter presses against the bladder and can look like a pseudo-ureterocele (22,23).

Girls who present with lifelong minimal urinary incontinence, never being dry, normal bladder function, complete emptying, and normal ultrasound are very suspicious for ectopic ureter. This needs to be excluded or confirmed by further imaging (e.g. MR imaging). Filling the bladder with methylene blue and checking for clear urine output from the vagina can give clear evidence of extrasphincteric ureteral ectopia. This test is also helpful in confirming a vesicovaginal fistula (in this case blue fluid is drained from the vagina).

16.4 Treatment

16.4.1 Ureterocele

The management is controversial with a choice between a conservative approach, endoscopic decompression, ureteral reimplantation, partial nephroureterectomy, or complete primary reconstruction (24-29). The choice of a therapeutic modality depends on the following criteria: clinical status of the patient (e.g. urosepsis); patient age; function of the upper pole; presence of reflux or obstruction of the ipsilateral or contralateral ureter; presence of bladder neck obstruction caused by ureterocele; intravesical or ectopic ureterocele; and parents' and surgeon's preferences (30).

When the diagnosis is made by ultrasound, prophylactic antibiotic treatment is indicated until a VCUG can be performed.

16.4.1.1 Early treatment

In the presence of febrile infection or obstruction at the bladder neck, immediate endoscopic incision or puncture of the ureterocele is recommended. In a clinically asymptomatic child with a ureterocele and a non- or hypofunctional upper pole, without significant obstruction of the lower pole and without bladder outlet obstruction, prophylactic antibiotic treatment is given until follow-up procedures are instigated.

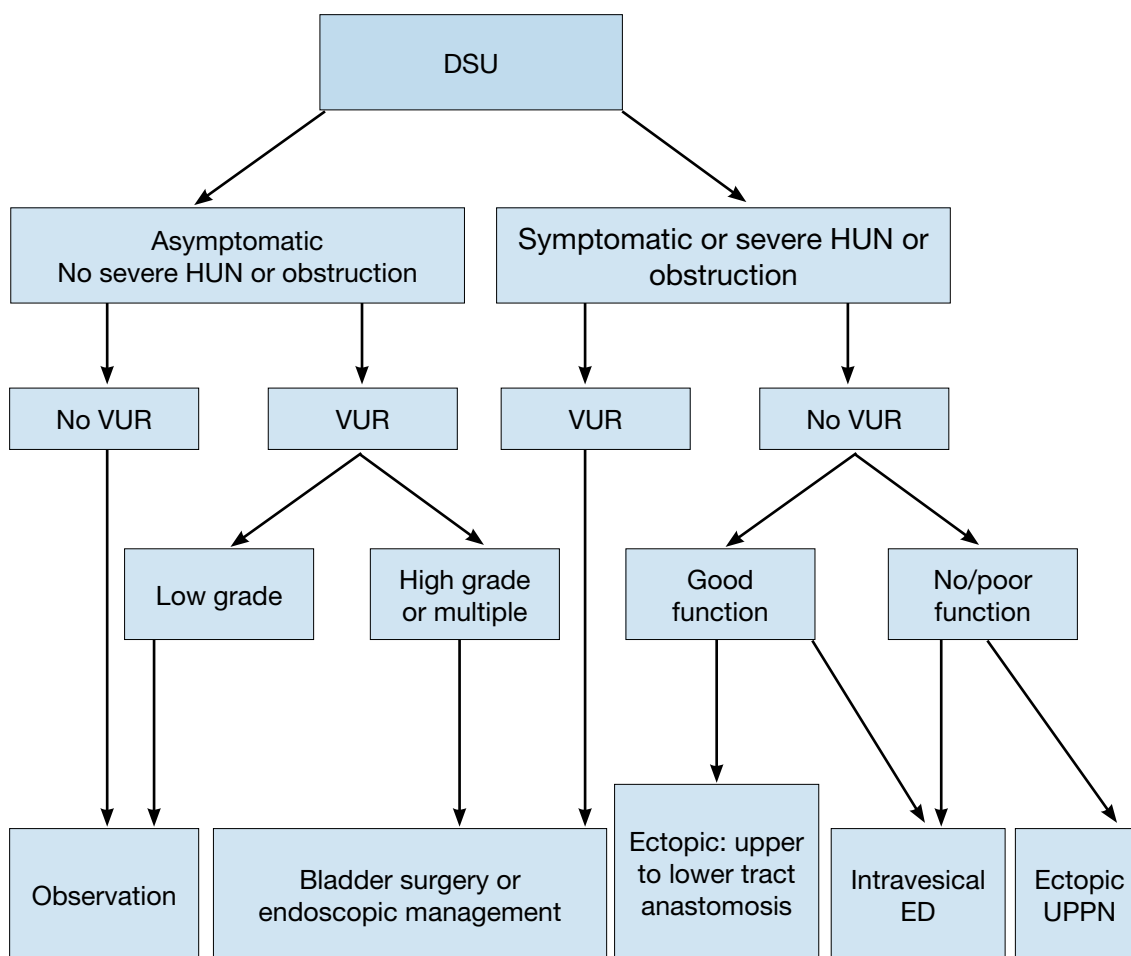
16.4.1.2 Re-evaluation

Conservative treatment may be adopted in asymptomatic patients without any bladder outlet obstruction,

without severe hydroureteronephrosis of the ureterocele moiety or high-grade (over grade III) reflux (30,31).

If decompression is effective and there is no reflux (~25% of cases and more often in intravesical ureterocele), the patient is followed-up conservatively. After an endoscopic incision, most of the children with an extravesical ureterocele (50-80%) need a secondary procedure, compared with only 18% of those with an intravesical ureterocele (32). Secondary surgery is necessary if decompression is not effective, significant reflux is present, or there is obstruction of the ipsi- or contralateral ureters, and/or bladder neck obstruction. Surgery may vary from upper pole nephrectomy to complete unilateral bladder reconstruction (10,26,33-40). In an ectopic ureterocele with severe hydroureteronephrosis and without reflux, the primary upper tract approach without endoscopic decompression (partial upper-pole nephroureterectomy, pyelo/uretero-pyelo/ureterostomy and upper-pole ureterectomy) gives up to an 80% chance of being the definitive treatment (30,41).

Figure 5: Algorithm for the management of duplex system ureteroceles after the first 3-6 months of life (30)



DSU = duplex system ureterocele; ED = endoscopic decompression; HUN = hydroureteronephrosis; MCUG = micturating cystourethrography; UPPN = upper pole partial nephrectomy; VUR = vesicoureteric reflux.

Obstruction is considered to be the presence of non-refluxing dilatation of non-ureterocele-bearing moieties (especially of the lower pole) or of an obstructive drainage pattern on diuretic renography.

16.4.2 Ectopic ureter

In the majority of cases, the upper pole is dysplastic and heminephro-ureterectomy should be considered. Ureteral reconstruction (ureteral reimplantation/ ureteroureterostomy/ureteropyelostomy and upper-pole ureterectomy) is a therapeutic option in cases in which the upper pole has function worth preserving. Both procedures can be performed through an open or laparoscopic approach (42-44). In patients with bilateral single ectopic ureters (a very rare condition), an individual approach depending on the sex and renal and bladder function is necessary. Usually the bladder neck is insufficient in these patients (45-48).

16.5 Conclusions and recommendations for obstructive pathology of renal duplication: ureterocele and ectopic ureter

Conclusions
Ureterocele and ectopic ureter are associated with complete renal duplication, but they also occur in a single system.
In most cases, in young children (first years of life) diagnosis is done by ultrasonography.
In older children clinical symptoms will prompt assessment.
Management includes a conservative approach, endoscopic decompression, partial nephroureterectomy, or complete primary reconstruction. Choice of treatment will depend on: <ul style="list-style-type: none"> - clinical status of the patient (e.g., urosepsis); - patient age; - function of the upper pole; - presence of reflux or obstruction of the ipsilateral or contralateral ureter; - presence of bladder neck obstruction caused by ureterocele; - intravesical or ectopic ureterocele; - and parents' and surgeon's preferences.

Recommendations			LE	GR
Ureterocele	Diagnosis	Ultrasonography, radionuclide studies (MAG III / DMSA), VCUG, magnetic resonance urography, high-resolution MRI, and cystoscopy are the diagnostic tools to assess function, to detect reflux and rule out ipsilateral compression of the lower pole and urethral obstruction.	3	B
	Treatment	Choice of treatment will depend on symptoms, function and reflux as well on surgical and parenteral choices: observation, endoscopic decompression, ureteral reimplantation, partial nephroureterectomy, complete primary reconstruction. <ul style="list-style-type: none"> - In patients (single/duplex systems) with no hydronephrosis and no symptoms, the risk for renal injury is low and conservative treatment is a good option. - In those with reflux, endoscopic treatment is an option; open reimplantation especially in dilating reflux provides better results. - In patients with an obstructing ureterocele, early endoscopic decompression is indicated. In half, to two-thirds of children with an extravesical ureterocele a secondary procedure is needed (compared to 20-25% of those with an intravesical ureterocele). - In patients with a non-functioning moiety and symptoms, heminephrectomy is indicated. 	3	B
Ectopic ureter	Diagnosis	Ultrasound, DMSA scan, VCUG, MRI should be used for a definitive diagnosis	3	B
	Treatment	Choice of treatment option will depend on the function of the upper urinary tract: <ul style="list-style-type: none"> - in poorly or non-functioning moieties, (hemi-) nephroureterectomy is an definite solution. - in patients with a functioning renal moiety, ureteral reimplantation, ureteroureterostomy and ureteropyelostomy are reliable options, especially in cases in which the upper pole has function worth preserving. 	3	B

16.6 References

1. Uson AC, Lattimer JK, Melicow MM. Ureteroceles in infants and children: a report based on 44 cases. *Pediatrics* 1961 Jun;27:971-83.
<http://www.ncbi.nlm.nih.gov/pubmed/13779382>
2. Prewitt LH Jr, Lebowitz RL. The single ectopic ureter. *AJR Am J Roentgenol* 1976 Dec;127(6):941-8.
<http://www.ncbi.nlm.nih.gov/pubmed/998831>

3. Ahmed S, Barker A. Single-system ectopic ureters: a review of 12 cases. *J Pediatr Surg* 1992 Apr;27(4):491-6.
<http://www.ncbi.nlm.nih.gov/pubmed/1522464>
4. Schulman CC. The single ectopic ureter. *Eur Urol* 1976;2(2):64-9.
<http://www.ncbi.nlm.nih.gov/pubmed/971675>
5. Chwalla R. The process of formation of cystic dilatation of the vesical end of the ureter and of diverticula at the ureteral ostium. *Urol Cutan Ren* 1927;31:499.
6. Stephens D. Caecoureterocele and concepts on the embryology and aetiology of ureteroceles. *Aust N Z J Surg* 1971 Feb;40(3):239-48.
<http://www.ncbi.nlm.nih.gov/pubmed/5279434>
7. Tokunaka S, Gotoh T, Koyanagi T, et al. Muscle dysplasia in megaureters. *J Urol* 1984 Feb;131(2):383-90.
<http://www.ncbi.nlm.nih.gov/pubmed/6699978>
8. Sen S, Ahmed S. Single system ureteroceles in childhood. *Aust N Z J Surg* 1988 Nov;58(11):903-7.
<http://www.ncbi.nlm.nih.gov/pubmed/3074770>
9. Zerlin JM, Baker DR, Casale JA. Single-system ureteroceles in infants and children: imaging features. *Pediatr Radiol* 2000 Mar;30(3):139-46.
<http://www.ncbi.nlm.nih.gov/pubmed/10755749>
10. Monfort G, Guys JM, Coquet M, et al. Surgical management of duplex ureteroceles. *J Pediatr Surg* 1992 May;27(5):634-8.
<http://www.ncbi.nlm.nih.gov/pubmed/1625138>
11. Upadhyay J, Bolduc S, Braga L, et al. Impact of prenatal diagnosis on the morbidity associated with ureterocele management. *J Urol* 2002 Jun;167(6):2560-5.
<http://www.ncbi.nlm.nih.gov/pubmed/11992089>
12. Bolduc S, Upadhyay J, Sherman C, et al. Histology of upper pole is unaffected by prenatal diagnosis in duplex system ureteroceles. *J Urol* 2002 Sep;168(3):1123-6.
<http://www.ncbi.nlm.nih.gov/pubmed/12187250>
13. Ellerker AG. The extravesical ectopic ureter. *Br J Surg* 1958 Jan;45(192):344-53.
<http://www.ncbi.nlm.nih.gov/pubmed/13536326>
14. Di Benedetto V, Monfort G. How prenatal ultrasound can change the treatment of ectopic ureterocele in neonates? *Eur J Pediatr Surg* 1997 Dec;7(6):338-40.
<http://www.ncbi.nlm.nih.gov/pubmed/9493984>
15. Pfister C, Ravasse P, Barret E, et al. The value of endoscopic treatment for ureteroceles during the neonatal period. *J Urol* 1998 Mar;159(3):1006-9.
<http://www.ncbi.nlm.nih.gov/pubmed/9474217>
16. Bozorgi F, Connolly LP, Bauer SB, et al. Hypoplastic dysplastic kidney with a vaginal ectopic ureter identified by technetium-99m-DMSA scintigraphy. *J Nucl Med* 1998 Jan;39(1):113-5.
<http://www.ncbi.nlm.nih.gov/pubmed/9443748>
17. Pattaras JG, Rushton HG, Majd M. The role of 99mtechnetium dimercapto-succinic acid renal scans in the evaluation of occult ectopic ureters in girls with paradoxical incontinence. *J Urol* 1999;162(3 Pt 1):821-5.
<http://www.ncbi.nlm.nih.gov/pubmed/10458388>
18. Connolly LP, Connolly SA, Drubach LA, et al. Ectopic ureteroceles in infants with prenatal hydronephrosis: use of renal cortical scintigraphy. *Clin Nucl Med* 2002 Mar;27(3):169-75.
<http://www.ncbi.nlm.nih.gov/pubmed/11852302>
19. Bellah RD, Long FR, Canning DA. Ureterocele eversion with vesicoureteral reflux in duplex kidneys: findings at voiding cystourethrography. *AJR Am J Roentgenol* 1995 Aug;165(2):409-13.
<http://www.ncbi.nlm.nih.gov/pubmed/7618568>
20. Carrico C, Lebowitz RL. Incontinence due to an infrasphincteric ectopic ureter: why the delay in diagnosis and what the radiologist can do about it. *Pediatr Radiol* 1998 Dec;28(12):942-9.
<http://www.ncbi.nlm.nih.gov/pubmed/9880638>
21. Ehammer T, Riccabona M, Maier E. High resolution MR for evaluation of lower urogenital tract malformations in infants and children: feasibility and preliminary experiences. *Eur J Radiol* 2011 Jun;78(3):388-93.
<http://www.ncbi.nlm.nih.gov/pubmed/20138451>
22. Diard F, Chateil JF, Bondonny JM, et al. [Pseudo-ureteroceles resulting from the impression of a loop of a megaureter with an ectopic subvesical orifice]. *J Radiol* 1987 Mar;68(3):177-84.
<http://www.ncbi.nlm.nih.gov/pubmed/3298636>

23. Sumfest JM, Burns MW, Mitchell ME. Pseudoureterocele: potential for misdiagnosis of an ectopic ureter as a ureterocele. *Br J Urol* 1995 Mar;75(3):401-5.
<http://www.ncbi.nlm.nih.gov/pubmed/7735809>
24. Beganovic A, Klijn AJ, Dik P, et al. Ectopic ureterocele: long-term results of open surgical therapy in 54 patients. *J Urol* 2007 Jul;178(1):251-4.
<http://www.ncbi.nlm.nih.gov/pubmed/17499769>
25. Decter RM, Roth DR, Gonzales ET. Individualized treatment of ureteroceles. *J Urol* 1989 Aug;142(2 Pt 2):535-7.
<http://www.ncbi.nlm.nih.gov/pubmed/2746775>
26. Husmann D, Strand B, Ewalt D, et al. Management of ectopic ureterocele associated with renal duplication: a comparison of partial nephrectomy and endoscopic decompression. *J Urol* 1999 Oct;162(4):1406-9.
<http://www.ncbi.nlm.nih.gov/pubmed/10492225>
27. Byun E, Merguerian PA. A meta-analysis of surgical practice patterns in the endoscopic management of ureteroceles. *J Urol* 2006 Oct;176(4 Pt 2):1871-7.
<http://www.ncbi.nlm.nih.gov/pubmed/16945677>
28. Chertin B, Mohanan N, Farkas A, et al. Endoscopic treatment of vesicoureteral reflux associated with ureterocele. *J Urol* 2007 Oct;178(4 Pt 2):1594-7.
<http://www.ncbi.nlm.nih.gov/pubmed/17707044>
29. Moscovici J, Galinier P, Berrogain N, et al. [Management of ureteroceles with pyelo-ureteral duplication in children. Report of 64 cases]. *Ann Urol (Paris)* 1999;33(5):369-76.
<http://www.ncbi.nlm.nih.gov/pubmed/10544742>
30. Castagnetti M, El-Ghoneimi A. Management of duplex system ureteroceles in neonates and infants. *Nat Rev Urol* 2009 Jun;6(6):307-15.
<http://www.ncbi.nlm.nih.gov/pubmed/19498409>
31. Han MY, Gibbons MD, Belman AB, et al. Indications for nonoperative management of ureteroceles. *J Urol*. 2005 Oct;174(4 Pt 2):1652-5.
<http://www.ncbi.nlm.nih.gov/pubmed/16148674>
32. Cooper CS, Passerini-Glazel G, Hutcheson JC, et al. Long-term followup of endoscopic incision of ureteroceles: intravesical versus extravesical. *J Urol* 2000 Sep;164(3 Pt 2):1097-9.
<http://www.ncbi.nlm.nih.gov/pubmed/10958751>
33. Jayanthi VR, Koff SA. Long-term outcome of transurethral puncture of ectopic ureteroceles: initial success and late problems. *J Urol* 1999 Sep;162(3 Pt 2):1077-80.
<http://www.ncbi.nlm.nih.gov/pubmed/10458435>
34. Hendren WH, Mitchell ME. Surgical correction of ureteroceles. *J Urol* 1979 May;121(5):590-7.
<http://www.ncbi.nlm.nih.gov/pubmed/439252>
35. Scherz HC, Kaplan GW, Packer MG, et al. Ectopic ureteroceles: surgical management with preservation of continence--review of 60 cases. *J Urol* 1989 Aug;142(2 Pt 2):538-41.
<http://www.ncbi.nlm.nih.gov/pubmed/2746776>
36. Adorasio O, Elia A, Landi L, et al. Effectiveness of primary endoscopic incision in treatment of ectopic ureterocele associated with duplex system. *Urology* 2011 Jan;77(1):191-4.
<http://www.ncbi.nlm.nih.gov/pubmed/21168903>
37. Pohl HG. Recent advances in the management of ureteroceles in infants and children: why less may be more. *Curr Opin Urol* 2011 Jul;21(4):322-7.
<http://www.ncbi.nlm.nih.gov/pubmed/21519275>
38. Pearce R, Subramaniam R. Partial nephroureterectomy in a duplex system in children: the need for additional bladder procedures. *Pediatr Surg Int* 2011 Dec;27(12):1323-6.
<http://www.ncbi.nlm.nih.gov/pubmed/21877243>
39. Jesus LE, Farhat WA, Amarante AC, et al. Clinical evolution of vesicoureteral reflux following endoscopic puncture in children with duplex system ureteroceles. *J Urol* 2011 Oct;186(4):1455-9.
<http://www.ncbi.nlm.nih.gov/pubmed/21862045>
40. DeFoor W, Minevich E, Tackett L, et al. Ectopic ureterocele: clinical application of classification based on renal unit jeopardy. *J Urol* 2003 Mar;169(3):1092-4.
<http://www.ncbi.nlm.nih.gov/pubmed/12576859>
41. Husmann DA, Ewalt DH, Glenski WJ, et al. Ureterocele associated with ureteral duplication and a nonfunctioning upper pole segment: management by partial nephroureterectomy alone. *J Urol* 1995 Aug;154(2 Pt 2):723-6.
<http://www.ncbi.nlm.nih.gov/pubmed/7609163>

42. el Ghoneimi A, Miranda J, Truong T, et al. Ectopic ureter with complete ureteric duplication: conservative surgical management. *J Pediatr Surg* 1996 Apr;31(4):467-72.
<http://www.ncbi.nlm.nih.gov/pubmed/8801293>
43. Smith FL, Ritchie EL, Maizels M, et al. Surgery for duplex kidneys with ectopic ureters: ipsilateral ureteroureterostomy versus polar nephrectomy. *J Urol* 1989 Aug;142(2 Pt 2):532-4.
<http://www.ncbi.nlm.nih.gov/pubmed/2746774>
44. Storm DW, Modi A, Jayanthi VR. Laparoscopic ipsilateral ureteroureterostomy in the management of ureteral ectopia in infants and children. *J Pediatr Urol* 2011 Oct;7(5):529-33.
<http://www.ncbi.nlm.nih.gov/pubmed/20869918>
45. Johnin K, Narita M, Kim CJ, et al. Bilateral single ectopic ureters with hypoplastic bladder: how should we treat these challenging entities? *J Pediatr Urol* 2007 Jun;3(3):243-6.
<http://www.ncbi.nlm.nih.gov/pubmed/18947744>
46. Roy Choudhury S, Chadha R, Bagga D, et al. Spectrum of ectopic ureters in children. *Pediatr Surg Int*. 2008 Jul;24(7):819-23.
<http://www.ncbi.nlm.nih.gov/pubmed/18463883>
47. Herndon CD, Ferrer FA, McKenna PH. A complex urologic problem demonstrates how far pediatric urology has progressed. *Conn Med* 1999 Dec;63(12):707-11.
<http://www.ncbi.nlm.nih.gov/pubmed/10659470>
48. Jayanthi VR, Churchill BM, Khoury AE, et al. Bilateral single ureteral ectopia: difficulty attaining continence using standard bladder neck repair. *J Urol* 1997 Nov;158(5):1933-6.
<http://www.ncbi.nlm.nih.gov/pubmed/9334642>

17. DISORDERS OF SEX DEVELOPMENT

17.1 Background

The formerly called 'intersex disorders' were recently the subject of a consensus document in which it was decided that the term 'intersex' should be changed to 'disorders of sex development' (DSD) (1,2).

The new classification has arisen because of advances in knowledge of the molecular genetic causes of abnormal sexual development, controversies inherent to clinical management and ethical issues. Controversial and pejorative terminology, e.g. 'pseudohermaphroditism' and 'hermaphroditism', have been renamed according to the new pathophysiological insights. Furthermore, some conditions presenting with severe male genital malformation, such as penile agenesis, cloacal exstrophy, which could not be categorised, have also been included. The term 'disorders of sex development' is proposed to indicate congenital conditions with atypical development of chromosomal, gonadal or anatomical sex. This will also include the idiopathic micropenis which is added here as a separate heading in this chapter on DSD.

We refer to the consensus document as a general guideline, while this chapter will focus on what is relevant for the practising paediatric urologist. As the urologist is likely to be involved in both surgical and nonsurgical neonatal work, this chapter will discuss the neonatal emergency and the diagnostic and therapeutic role of the paediatric urologist.

Overall, there is a low evidence base for the published literature on DSD. There are no randomised controlled trials and most studies are based on retrospective clinical descriptive studies (grade 4 level of evidence) or are expert opinion. An exception is the risk of gonadal cancer, for which the level of evidence is higher.

Disorders of sex development require a multidisciplinary approach to diagnosis and treatment, which should include geneticists, neonatologists, paediatric and adult endocrinologists, gynaecologists, psychologists, ethicists and social workers. Each team member should be specialised in DSD and a team should have enough new patients to ensure experience.

17.2 Micropenis

17.2.1 Background

Micropenis is a small but otherwise normally formed penis with a stretched length of less than 2.5 SD below the mean (1-3).

Besides an idiopathic micropenis, two major causes of abnormal hormonal stimulation have been identified:

- Hypogonadotropic hypogonadism (due to an inadequate secretion of GnRH);
- Hypergonadotropic hypogonadism (due to failure of the testes to produce testosterone).

17.2.2 **Diagnosis**

The penis is measured on the dorsal aspect, while stretching the penis, from the pubic symphysis to the tip of the glans (1). The corpora cavernosa are palpated, the scrotum is often small, and the testes may be small and descended. Micropenis should be distinguished from buried and webbed penis, which is usually of normal size.

The initial evaluation has to define whether the aetiology of the micropenis is central (hypothalamic/pituitary) or testicular. A paediatric endocrinology work-up has to be carried out immediately. Karyotyping is mandatory in all patients with a micropenis.

Endocrine testicular function is assessed (baseline and stimulated testosterone, LH and FSH serum levels). Stimulated hormone levels may also give an idea of the growth potential of the penis. In patients with non-palpable testes and hypogonadotropic hypogonadism, laparoscopy should be carried out to confirm vanishing testes syndrome or intra-abdominal undescended hypoplastic testes. This investigation can be delayed until the age of 1 year (2).

17.2.3 **Treatment**

Pituitary or testicular insufficiency are treated by the paediatric endocrinologist. In patients with testicular failure and proven androgen sensitivity, androgen therapy is recommended during childhood and at puberty to stimulate the growth of the penis (4-7) (LE: 2; GR: B). In the presence of androgen insensitivity, good outcome of sexual function is questioned and gender conversion can be considered (8-10).

17.3 **The neonatal emergency**

The first step is to recognise the possibility of DSD (Table 12) and to refer the newborn baby immediately to a tertiary paediatric centre, fully equipped with neonatal, genetics, endocrinology and paediatric urology units. At the paediatric centre, the situation should be explained to the parents fully and kindly. Registering and naming the newborn should be delayed as long as necessary.

17.3.1 **Family history and clinical examination**

A careful family history must be taken followed by a thorough clinical examination (Table 13).

Table 12: Findings in a newborn suggesting the possibility of DSD (adapted from the American Academy of Pediatrics)

Apparent male
Severe hypospadias associated with bifid scrotum
Undescended testis/testes with hypospadias
Bilateral non-palpable testes in a full-term apparently male infant
Apparent female
Clitoral hypertrophy of any degree, non-palpable gonads
Vulva with single opening
Indeterminate
Ambiguous genitalia

Table 13: Diagnostic work-up of neonates with ambiguous genitalia

History (family, maternal, neonatal)
Parental consanguinity
Previous DSD or genital anomalies
Previous neonatal deaths
Primary amenorrhoea or infertility in other family members
Maternal exposure to androgens
Failure to thrive, vomiting, diarrhoea of the neonate
Physical examination
Pigmentation of genital and areolar area
Hypospadias or urogenital sinus
Size of phallus

Palpable and/or symmetrical gonads
Blood pressure
Investigations
Blood analysis: 17-hydroxyprogesterone, electrolytes, LH, FSH, TST, cortisol, ACTH
Urine: adrenal steroids
Karyotype
Ultrasound
Genitogram
hCG stimulation test
Androgen-binding studies
Endoscopy

LH = luteinizing hormone; FSH = follicle stimulating hormone; TST = testosterone; ACTH = adrenocorticotrophic hormone; hCG = human chorionic gonadotrophin.

17.3.2 **Choice of laboratory investigations**

The following laboratory investigations are mandatory:

- Karyotype;
- Plasma 17-hydroxyprogesterone assay;
- Plasma electrolytes;
- Ultrasonography to evaluate the presence of Müllerian duct structures.

These investigations will provide evidence of congenital adrenal hyperplasia (CAH), which is the most frequently occurring DSD. If this evidence is found, no further investigation is needed. If not, then the laboratory work-up should proceed further.

The hCG stimulation test is particularly helpful in differentiating the main syndromes of 46XYDSD by evaluating Leydig cell potential. When testosterone metabolism is evaluated, the presence or absence of metabolites will help to define the problem. An extended stimulation can help to define phallic growth potential and to induce testicular descent in some cases of associated cryptorchidism.

17.4 **Gender assignment**

This is a very complicated task. It should take place after a definitive diagnosis has been made. The idea that an individual is sex-neutral at birth and that rearing determines gender development is no longer the standard approach. Instead, gender assignment decisions should be based upon:

- age at presentation;
- fertility potential;
- size of the penis;
- presence of a functional vagina;
- endocrine function;
- malignancy potential;
- antenatal testosterone exposure;
- general appearance;
- psychosocial well-being and a stable gender identity.
- sociocultural aspect
- parental opinions.

Each patient presenting with DSD should be assigned a gender as quickly as a thorough diagnostic evaluation permits. Minimal time needed is 48 hrs. During this period any referral to gender should be avoided, better to address the patient as “the child”, “your child”.

17.5 **Role of the paediatric urologist**

The role of the paediatric urologist can be divided into a diagnostic role and a therapeutic role (Table 14). Each of these roles will be discussed briefly.

Table 14: Role of the paediatric urologist

<i>Diagnostic role</i>
<ul style="list-style-type: none">• Clinical examination• Ultrasound• Genitography• Cystoscopy• Diagnostic laparoscopy
<i>Therapeutic role</i>
<ul style="list-style-type: none">• Masculinising surgery• Feminising surgery• Gonadectomy

17.5.1 **Diagnosis**

17.51.1 *Clinical examination*

A good clinical examination in a neonate presenting with ambiguous genitalia is important. As well as a good description of the ambiguous genitalia, some detailed information should be given on palpability and localisation of the gonads. Information gathered by the various examinations described below should help the team to come to a final diagnosis.

Palpable gonad. It must be remembered that if it is possible to feel a gonad, it is almost certainly a testis; this clinical finding therefore virtually excludes 46XXDSD.

Medical photography can be useful but requires sensitivity and consent (13).

Phallus. The phallus should be measured. A cotton bud placed at the suprapubic base of the implant of the stretched phallus allows for a good measurement of phallic length.

Urogenital sinus opening. The opening of the urogenital sinus must be well evaluated. Is there only one opening visible? Can a hymenal ring be seen? What does the fusion of the labioscrotal folds look like; do the folds show rugae or some discolouration?

17.5.1.2 *Investigations*

Ultrasound can help to describe the palpated gonads or to detect non-palpated gonads. However, the sensitivity and specificity are not high. On ultrasound, the Müllerian structures can be evaluated. Is there a vagina? Are there some abdominal gonads? Is there a vaginal or utricular structure visible? (14,15).

Genitography can provide some more information on the urogenital sinus. How low or how high is the confluence? Is there any duplication of the vagina? How does the urethra relate to the vagina?

General anaesthesia. In some cases, further examinations under general anaesthesia can be helpful. On cystoscopy, the urogenital sinus can be evaluated and the level of confluence between the bladder neck and the bladder. Cystoscopy can also be used to evaluate the vagina or utriculus, e.g. the presence of a cervix at the top of the vagina can be important information.

Laparoscopy is necessary to obtain a final diagnosis on the presence of impalpable gonads and on the presence of Müllerian structures. If indicated, a gonadal biopsy can be performed (16,17).

17.6 **Management**

Referring to the consensus document (1,2), it is clear that the timing of surgery is much more controversial than it used to be.

The rationale for early surgery includes:

- beneficial effects of oestrogen on infant tissue;
- avoiding complications from anatomical anomalies;
- minimising family distress;
- mitigating the risks of stigmatisation and gender-identity confusion (18).

However, adverse outcomes have led to recommendations to delay unnecessary surgery to an age when the patient can give informed consent. Surgery that alters appearance is not urgent. Early surgery should be reserved for those patients with high confluent urogenital tracts, girls with severely masculinised genitalia and boys with undervirilised genitals. Vaginoplasty should be delayed until puberty and milder forms of

masculinisation should not be treated surgically.

17.6.1 **Feminising surgery**

Clitororeduction. Reduction of an enlarged clitoris should be done with preservation of the neurovascular bundle. Clitoral surgery has been reported to have an adverse outcome on sexual function and clitoral surgery should therefore be limited to severely enlarged clitorises (19,20). Informed parental consent should be obtained. Although some techniques that conserve erectile tissue have been described, the long-term outcome is unknown (21).

Separation of the vagina and the urethra is preserved for high confluence anomalies. Many techniques for urogenital sinus repair have been described, but their outcome has not been evaluated prospectively (22,23).

Vaginoplasty should be performed during the teenage years. Every technique (self dilatation, skin or bowel substitution) has its specific advantages and disadvantages (24). All carry a potential for scarring that would require further surgery before sexual function was possible.

Aesthetic refinements. The goals of genital surgery are to maximise anatomy to allow sexual function and romantic partnering. Aesthetics are important in this perspective. The reconstruction of minor labiae from an enlarged clitoral hood is an example of aesthetic refinement.

17.6.2 **Masculinising surgery**

Hormone therapy early in life is advocated by many doctors. The level of evidence is low for restoration of normal penile size.

Hypospadias surgery. See section on hypospadias (Chapter 6).

Excision of Mullerian structures. In the DSD patient assigned a male gender, Müllerian structures should be excised. There is no evidence about whether utricular cysts need to be excised.

Orchiopexy. See section on orchidopexy (Chapter 3).

Phalloplasty. The increasing experience of phalloplasty in the treatment of female to male transsexual patients has led to reports about the reliability and feasibility of this technique. It has therefore become available to treat severe penile inadequacy in DSD patients.

Aesthetic refinements. These include correction of penoscrotal transposition, scrotoplasty and insertion of testicular prostheses.

Gonadectomy. Germ cell malignancy only occurs in patients with DSD who have Y-chromosomal material. The highest risk is seen in patients with gonadal dysgenesis and in patients with partial androgen insensitivity with intra-abdominal gonads (LE: 2). Intra-abdominal gonads of high-risk patients should be removed at the time of diagnosis (25) (GR: A).

17.7 **Guidelines for the treatment of disorders of sex development**

Disorders of sex development (DSD) are the example of conditions for which a multidisciplinary approach is mandatory and gold standard. These children should be referred to experienced centres where neonatology, paediatric endocrinology, paediatric urology, child psychology and transition to adult care are guaranteed.
Any neonate presenting with ambiguous genitalia is an emergency since salt-losing in a 46XX CAH girl can be fatal.
Gender assignment is imminent and should be based on multidisciplinary consensus taking into account the latest knowledge.
Timing of surgery will be dependent on the severity of the condition and on the assigned sex.
- In severe anomalies in girls early surgical treatment is indicated.
- In less severe cases, in consultation with the parents, a more conservative approach might be followed.
- In boys the surgical correction will mainly consist of hypospadias repair and orchiopexy, so the timing will follow the recommendations for hypospadias repair and orchiopexy (from 6 months onwards and before 2 years of age).

17.8 References

1. Lee PA, Houk CP, Ahmed SF, et al; International Consensus Conference on Intersex organized by the Lawson Wilkins Pediatric Endocrine Society and the European Society for Paediatric Endocrinology. Consensus statement on management of intersex disorders. International Consensus Conference on Intersex. *Pediatrics* 2006;118(2):e488-e500.
<http://www.ncbi.nlm.nih.gov/pubmed/16882788>
2. Houk CP, Hughes IA, Ahmed SF, et al; Writing Committee for the International Intersex Consensus Conference Participants. Summary of consensus statement on intersex disorders and their management. International Intersex Consensus Conference. *Pediatrics* 2006;118(2):753-7.
<http://www.ncbi.nlm.nih.gov/pubmed/16882833>
3. Feldman KW, Smith DW. Fetal phallic growth and penile standards for newborn male infants. *J Pediatr* 1975;86(3):395-8.
<http://www.ncbi.nlm.nih.gov/pubmed/1113226>
4. Aaronson IA. Micropenis; medical and surgical implications. *J Urol* 1994;152:4-14. [no abstract available]
<http://www.ncbi.nlm.nih.gov/pubmed/8201683>
5. Gonzales JR. Micropenis. *AUA Update Series* 1983;2:1.
6. Burstein S, Grumbach MM, Kaplan SL. Early determination of androgen-responsiveness is important in the management of micropenis. *Lancet* 1979;2(8150):983-6
<http://www.ncbi.nlm.nih.gov/pubmed/91775>
7. Choi SK, Han SW, Kim DH, et al. Transdermal dihydrotestosterone therapy and its effects on patients with micropenis. *J Urol* 1993;150(2 Pt 2):657-60.
<http://www.ncbi.nlm.nih.gov/pubmed/8326617>
8. Diamond M. Pediatric management of ambiguous and traumatized genitalia. *J Urol* 1999;162 (3 Pt 2):1021-8.
<http://www.ncbi.nlm.nih.gov/pubmed/10458424>
9. Bin-Abbas B, Conte FA, Grumbach MM, et al. Congenital hypogonadotropic hypogonadism and micropenis: effect of testosterone treatment on adult penile size. Why sex reversal is not indicated. *J Pediatr* 1999;134(5):579-83.
<http://www.ncbi.nlm.nih.gov/pubmed/10228293>
10. Callikoglu AS. Should boys with micropenis be reared as girls? *J Pediatr* 1999;134(5):537-8. [no abstract available]
<http://www.ncbi.nlm.nih.gov/pubmed/10228285>
11. Reilly JM, Woodhouse CR. Small penis and the male sexual role. *J Urol* 1989;142(2 Pt 2):569-71.
<http://www.ncbi.nlm.nih.gov/pubmed/2746779>
12. Husmann DA. The androgen insensitive micropenis: long-term follow-up into adulthood. *J Pediatr Endocrinol Metab* 2004;17(8):1037-41.
<http://www.ncbi.nlm.nih.gov/pubmed/15379413>
13. Creighton S, Alderson J, Brown S, et al. Medical photography: ethics, consent and the intersex patient. *BJU Int* 2002;89(1):67-1; discussion 71-2. [no abstract available]
<http://www.ncbi.nlm.nih.gov/pubmed/11849163>
14. Biswas K, Kapoor A, Karak AK, et al. Imaging in intersex disorders. *J Pediatr Endocrinol Metab* 2004;17(6):841-5.
<http://www.ncbi.nlm.nih.gov/pubmed/15270401>
15. Wright NB, Smith C, Rickwood AM, et al. Imaging children with ambiguous genitalia and intersex states. *Clin Radiol* 1995;50(12): 823-9. [no abstract available]
<http://www.ncbi.nlm.nih.gov/pubmed/8536391>
16. Chertin B, Koulikov D, Alberton J, et al. The use of laparoscopy in intersex patients. *Pediatr Surg Int* 2006;22(5):405-8.
<http://www.ncbi.nlm.nih.gov/pubmed/16521001>
17. Denes FT, Mendonca BB, Arap S. Laparoscopic management of intersexual states. *Urol Clin North Am* 2001;28(1):31-42.
<http://www.ncbi.nlm.nih.gov/pubmed/11277066>
18. [No authors listed] Timing of elective surgery on the genitalia of male children with particular reference to the risks, benefits, and psychological effects of surgery and anesthesia. *American Academy of Pediatrics. Pediatrics* 1996;97(4):590-4. [no abstract available]
<http://www.ncbi.nlm.nih.gov/pubmed/8632952>
19. Creighton SM. Adult female outcomes of feminising surgery for ambiguous genitalia. *Pediatr Endocrinol Rev* 2004;2(2):199-202.
<http://www.ncbi.nlm.nih.gov/pubmed/16429106>

20. Minto CL, Liao LM, Woodhouse CR, et al. The effect of clitoral surgery on sexual outcome in individuals who have intersex conditions with ambiguous genitalia: a cross-sectional study. *Lancet* 2003;361(9365):1252-7.
<http://www.ncbi.nlm.nih.gov/pubmed/12699952>
21. Crouch NS, Creighton SM. Minimal surgical intervention in the management of intersex conditions. *J Pediatr Endocrinol Metab* 2004;17(12):1591-6.
<http://www.ncbi.nlm.nih.gov/pubmed/15645692>
22. Jenak R, Ludwikowski B, Gonzalez R. Total urogenital sinus mobilization: a modified perineal approach for feminizing genitoplasty and urogenital sinus repair. *J Urol* 2001;165(6 Pt 2):2347-9.
<http://www.ncbi.nlm.nih.gov/pubmed/11371975>
23. Leclair MD, Gundetti M, Kiely EM, et al. The surgical outcome of total urogenital mobilization for cloacal repair. *J Urol* 2007;177(4):1492-5.
<http://www.ncbi.nlm.nih.gov/pubmed/17382761>
24. Schober JM. Feminizing genitoplasty: a synopsis of issues relating to genital surgery in intersex individuals. *J Pediatr Endocrinol Metab* 2004;17(5):697-703.
<http://www.ncbi.nlm.nih.gov/pubmed/15237702>
25. Cools M, Drop SL, Wolffenbuttel KP, Oosterhuis JW, Looijenga LH. Germ cell tumors in the intersex gonad: old paths, new directions, moving frontiers. *Endocr Rev* 2006;27(5):468-84.
<http://www.ncbi.nlm.nih.gov/pubmed/16735607>

18. POSTERIOR URETHRAL VALVES

18.1 Background

Posterior urethral valves (PUV) are one of the few life-threatening congenital anomalies of the urinary tract found during the neonatal period. Despite optimal treatment, PUV in children may result in renal insufficiency in nearly one-third of cases (1-3). PUV are found in 1 in 1,250 in a population undergoing foetal ultrasound screening (4). An incidence of PUV of 1 in 5,000-12,500 live-births has been estimated (5,6). In one report, up to 46% of foetuses with a PUV diagnosis were terminated, indicating a possible decrease in incidence (7).

18.2 Classification

18.2.1 Urethral valve

Despite recent attempts to introduce new classification terms, such as 'congenital obstructive posterior urethral membrane (COPUM) (8), the original classification by Hugh Hampton Young remains the most commonly used (9).

Hampton Young described three categories: type I, type II and type III. However, today, only type I and type III are found to be obstructive. As type II seems to be more like a fold and not obstructive, it is no longer referred to as a valve. Hampton Young's descriptions of type I and III are as follows:

Type I (90-95%). 'In the most common type there is a ridge lying on the floor of the urethra, continuous with the verumontanum, which takes an anterior course and divides into two fork-like processes in the region of the bulbo-membranous junction. These processes are continued as thin membranous sheets, direct upward and forward which may be attached to the urethra throughout its entire circumference. It is generally supposed that the valves have complete fusion anteriorly, leaving only an open channel at the posterior urethral wall. Yet the fusion of the valves anteriorly may not be complete in all cases, and at this point a slight separation of the folds exists (9).

Type III. 'There is a third type which has been found at different levels of the posterior urethra and which apparently bears no such relation to the verumontanum. This obstruction was attached to the entire circumference of the urethra, with a small opening in the centre (9).

The transverse membrane described has been attributed to incomplete dissolution from the urogenital portion of the cloacal membrane (10). The embryology of the urethral valves is poorly understood. The membrane may be an abnormal insertion of the mesonephric ducts into the foetal cloaca (11).

18.3 Diagnosis

An obstruction above the level of the urethra affects the whole urinary tract in varying degrees.

- The prostatic urethra is distended and the ejaculatory ducts may be dilated due to urinary reflux. The

bladder neck is hypertrophied and rigid.

- The hypertrophied bladder occasionally has multiple diverticula.
- Nearly all valve patients have dilatation of both upper urinary tracts. This may be due to the valve itself and the high pressure in the bladder, or due to obstruction of the ureterovesical junction by the hypertrophied bladder.
- If there is secondary reflux, the affected kidney functions poorly in most cases.

During prenatal ultrasonography screening, bilateral hydronephrosis and a distended bladder are suspicious signs of a urethral valve. If a dilated posterior urethra and a thick-walled bladder ('keyhole' sign) are seen, a PUV is likely. In the presence of increased echogenicity of the kidney, dilatation of the urinary tract and oligohydramnion, the diagnosis of a PUV should strongly be considered.

VCUG confirms a PUV diagnosis. This study is essential whenever there is a question of an infravesical obstruction, as the urethral anatomy is well outlined during voiding. A secondary reflux is observed in at least 50% of patients with PUV (12). Reflux is consistently associated with renal dysplasia in patients with PUV. It is generally accepted that reflux in the renal units acts as a 'pressure pop-off valve', which would protect the other kidney, leading to a better prognosis (13). Other types of pop-off mechanism include bladder diverticula and urinary extravasation, with or without urinary ascites (14). However, in the long-term, a supposed protective effect did not show a significant difference compared to other patients with PUV (15,16).

Nuclear renography with split renal function is important to assess kidney function. Creatinine, blood urea nitrogen and electrolytes should be monitored closely during the first few days. A nadir creatinine of 80 $\mu\text{mol/L}$ is correlated with a better prognosis (3).

18.4 Treatment

18.4.1 Antenatal treatment

About 40-60% of PUV are discovered before birth (17). The intrauterine obstruction leads to a decreased urine output, which could result in an oligohydramnios. Amnion fluid is necessary for normal development of the lung and its absence may lead to pulmonary hypoplasia, causing a life-threatening problem. Intrauterine attempts have been made to treat a foetus with PUV.

As renal dysplasia is not reversible, it is important to identify those foetuses with good renal function. A sodium level below 100 mmol/L, a chloride value of < 90 mmol/L and an osmolality below 200 mOsm/L found in three foetal urine samples gained on three different days are associated with a better prognosis (18).

The placing of a vesicoamniotic shunt has a complication rate of 21-59%, dislocation of the shunt occurs in up to 44%, mortality lies between 33% and 43%, and renal insufficiency is above 50% (18-20). Although shunting is effective in reversing oligohydramnios, it makes no difference to the outcome and long-term results of patients with PUV (19,20).

18.4.2 Postnatal treatment

Bladder drainage. If a boy is born with suspected PUV, drainage of the bladder and, if possible, an immediate VCUG is necessary. A neonate can be catheterised with a 3.5-5 F catheter. Balloon catheters are not available in this size. A VCUG is performed to see if the diagnosis is correct and whether the catheter is within the bladder and not in the posterior urethra. An alternative option is to place a suprapubic catheter, perform a VCUG and leave the tube until the neonate is stable enough to perform an endoscopic incision or resection of the valve.

Valve ablation. When the medical situation of the neonate has stabilised and the creatinine level decreased, the next step is to remove the intravesical obstruction. Small paediatric cystoscopes and resectoscopes are now available either to incise or to resect the valve at the 4-5, 7-8 or 12 o'clock position, or at all three positions, depending on the surgeon's preference. It is important to avoid extensive electrocoagulation, as the most common complication of this procedure is stricture formation. One recently published study demonstrated a significant lower urethral stricture rate using the cold knife compared to diathermy (21).

Vesicostomy. If the child is too small and/or too ill to undergo endoscopic surgery, a vesicostomy is used to drain the bladder temporarily. If initially a suprapubic tube has been inserted, this can be left in place for 6-12 weeks. Otherwise, a cutaneous vesicostomy provides an improvement or stabilisation of upper urinary tracts in over 90% of cases (22). Although there has been concern that a vesicostomy could decrease bladder compliance or capacity, so far there are no valid data to support these expectations (23,24).

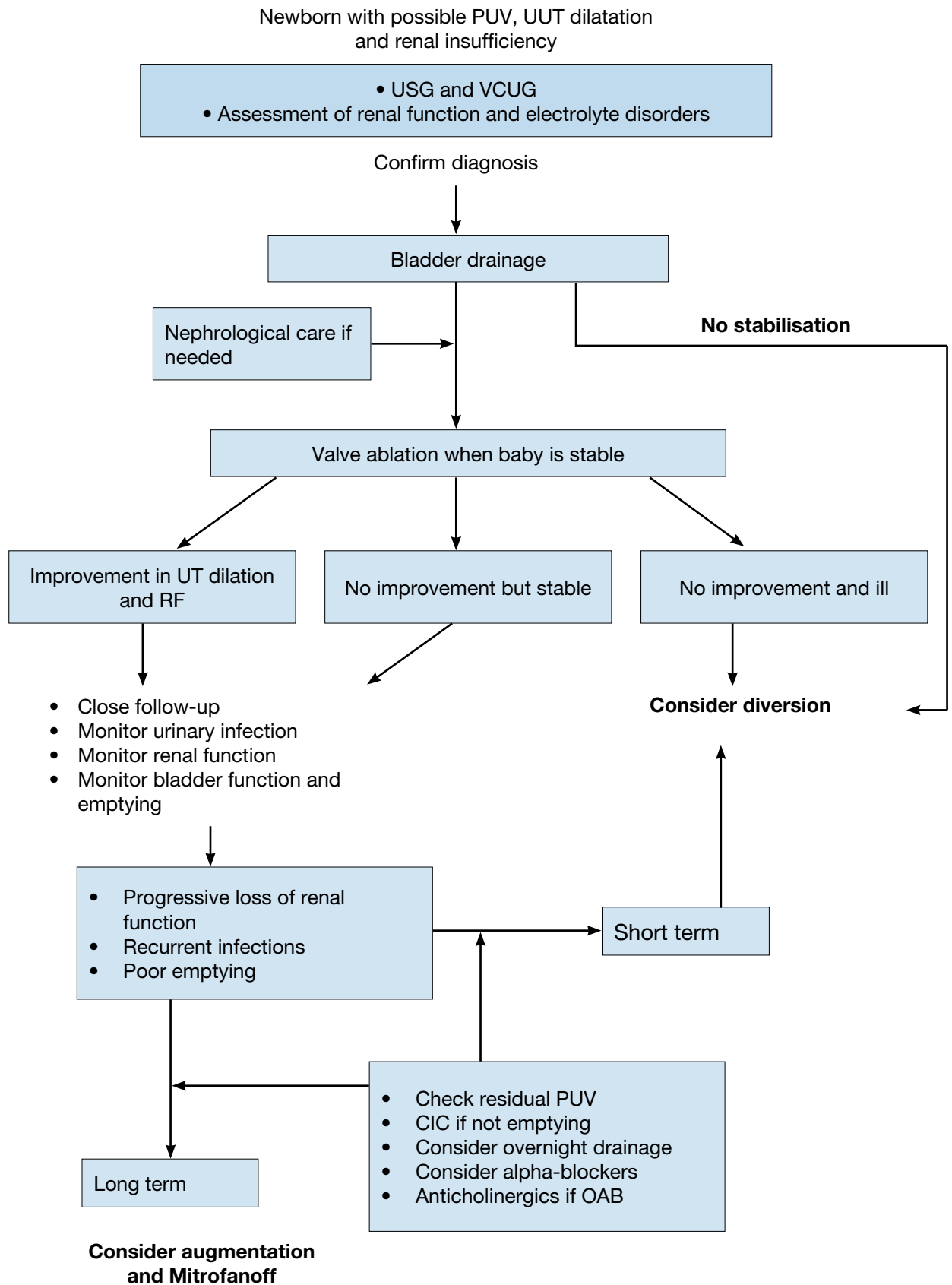
High diversion. If bladder drainage is insufficient to drain the upper urinary tract, high urinary diversion should be considered. Diversion may be suitable if there are recurrent infections of the upper tract, no improvement in renal function and/or an increase in upper tract dilatation, despite adequate bladder drainage. The choice

of urinary diversion depends on the surgeon's preference for high loop ureterostomy, ring ureterostomy, end ureterostomy or pyelostomy, with each technique having advantages and disadvantages (25-27). Reconstructive surgery should be delayed until the upper urinary tract has improved as much as can be expected.

Reflux is very common in PUV patients (up to 72%) and it is described bilaterally in up to 32% (28). During the first months of life, antibiotic prophylaxis may be given especially in those with high grade reflux (29) and in those with a phimosis, circumcision can be discussed in order to reduce the risk of urinary tract infections (30). However, there are no randomized studies to support this for patients with PUV. High-grade reflux is associated with a poor functioning kidney and is considered a poor prognostic factor (1,31). However, early removal of the renal unit seems to be unnecessary, as long as it causes no problems. It may be necessary to augment the bladder and in this case the ureter may be used (32).

Life-long monitoring of these patients is mandatory, as bladder dysfunction is not uncommon and the delay in day- and night-time continence is a major problem (12,3). Poor bladder sensation and compliance, detrusor instability and polyuria (especially at night) and their combination are responsible for bladder dysfunction. In those with bladder instability, anticholinergic therapy can improve bladder function. However, with a low risk of reversible myogenic failure (3 out of 37 patients in one study) (33,34). Between 10% and 47% of patients may develop end-stage renal failure (1-3). Renal transplantation in these patients can be performed safely and effectively (35,36). Deterioration of the graft function is mainly related to lower urinary tract dysfunction (37,38).

Figure 6. An algorithm providing information on assessment, treatment and follow up of newborns with possible PUV



PUV = posterior urethral valve; UUT = upper urinary tract; USG = urinary specific gravity; VCUG = voiding cystourethrogram; UT = urinary tract; RF = renal function; CIC = clean intermittent catheterization; OAB = overactive bladder.

18.5 Summary

Posterior urethral valves (PUV) are one of the few life-threatening congenital anomalies of the urinary tract found during the neonatal period and despite optimal treatment result in renal insufficiency in nearly one-third of cases. Bilateral hydronephrosis and a distended bladder are suspicious signs of a PUV in the neonates. A voiding cystourethrography (VCUG) confirms a PUV diagnosis. Nuclear renography with split renal function assess kidney function and serum creatinine nadir above 80 µmol/L is correlated with a poor prognosis.

Postnatal treatment includes bladder drainage either transurethral or suprapubic and if the child is stable enough, endoscopic incision of the valve is performed. If a child too small and/or too ill to undergo endoscopic surgery, a vesicostomy is an option for bladder drainage. If bladder drainage is insufficient to drain the upper urinary tract, high urinary diversion should be considered.

In all patients life-long monitoring is mandatory, as bladder dysfunction is quite common and may cause progressive upper tract deterioration, if not managed properly. In the long run between 10% and 47% of patients may develop end-stage renal failure. Renal transplantation in these patients can be performed safely and effectively.

18.6 Conclusions and recommendations posterior urethral valves

PUV		LE	GR
Diagnosis	An ultrasound can indicate an anomaly, but a VCUG is required to confirm the diagnosis. - Split renal function is to be assessed by DMSA scan. - Serum creatinine is the prognostic marker.	3	B
Treatment antenatal	A vesico-amniotic shunt is effective in reversing oligohydramnios, but it has a relatively high complication rate. There is no difference in the renal outcome and long-term results.	3	B
Treatment postnatal	After bladder drainage and stabilization of the child, endoscopic valve ablation should be performed. - In case the child is too small, a vesicostomy is an option for bladder drainage. - If bladder drainage is insufficient to drain the upper urinary tract, high urinary diversion should be considered (see Fig. 6).	3	B
Follow-up	Life-long monitoring is mandatory (bladder dysfunction; end-stage renal failure) in all patients. - Those with serum creatinine nadir above 80µmol/L have a poor prognosis. Despite optimal treatment 10-47% of cases develop end-stage renal failure. - Renal transplantation can safely be performed if bladder function is stable.	3	B

DMSA = dimercaptosuccinic acid scan; VCUG = voiding cystourethrogram.

18.7 References

1. Heikkila, J, Holmberg, C, Kyllonen, L, et al. Long-term risk of end stage renal disease in patients with posterior urethral valves. J Urol 2011 Dec;186(6):2392-6.
<http://www.ncbi.nlm.nih.gov/pubmed/22014822>
2. Reinberg, Y, de Castano, I, Gonzalez, R. Influence of initial therapy on progression of renal failure and body growth in children with posterior urethral valves. J Urol 1992 Aug;148(2 Pt 2):532-3.
<http://www.ncbi.nlm.nih.gov/pubmed/1640516>
3. Smith, GH, Canning, DA, Schulman, SL, et al. The long-term outcome of posterior urethral valves treated with primary valve ablation and observation. J Urol 1996 May;155(5):1730-4.
<http://www.ncbi.nlm.nih.gov/pubmed/8627873>
4. Gunn TR, Mora JD, Pease P. Antenatal diagnosis of urinary tract abnormalities by ultrasonography after 28 weeks' gestation: incidence and outcome. Am J Obstet Gynecol 1995 Feb;172(2 Pt 1):479-86.
<http://www.ncbi.nlm.nih.gov/pubmed/7856673>
5. Atwell JD. Posterior urethral valves in the British Isles: a multicenter BAPS review. J Pediatr Surg 1983 Feb;18(1):70-4.
<http://www.ncbi.nlm.nih.gov/pubmed/6834230>

6. Casale AJ. Early ureteral surgery for posterior urethral valves. *Urol Clin North Am* 1990 May;17(2): 361-72.
<http://www.ncbi.nlm.nih.gov/pubmed/2186541>
7. Cromie WJ, Lee K, Houde K, et al. Implications of prenatal ultrasound screening in the incidence of major genitourinary malformations. *J Urol* 2001 May;165(5):1677-80.
<http://www.ncbi.nlm.nih.gov/pubmed/11342955>
8. Dewan PA, Zappala SM, Ransley PG, et al. Endoscopic reappraisal of the morphology of congenital obstruction of the posterior urethra. *Br J Urol* 1992 Oct;70(4):439-44.
<http://www.ncbi.nlm.nih.gov/pubmed/1450856>
9. Young HH, Frontz WA, Baldwin JC. Congenital obstruction of the posterior urethra. *J Urol*,3:289-365, 1919. *J Urol* 2002 Jan;167(1):265-7.
<http://www.ncbi.nlm.nih.gov/pubmed/11743334>
10. Rosenfeld B, Greenfield SP, Springate JE, et al. Type III posterior urethral valves: presentation and management. *J Pediatr Surg* 1994 Jan;29(1):81-5.
<http://www.ncbi.nlm.nih.gov/pubmed/8120770>
11. Stephens FD, Gupta D. Pathogenesis of the prune belly syndrome. *J Urol* 1994 Dec;152(6 Pt 2): 2328-31.
<http://www.ncbi.nlm.nih.gov/pubmed/7966734>
12. Churchill BM, McLorie GA, Khoury AE, et al. Emergency treatment and longterm follow-up of posterior urethral valves. *Urol Clin North Am* 1990 May;17(2):343-60.
<http://www.ncbi.nlm.nih.gov/pubmed/2186540>
13. Hoover DL, Duckett JW Jr. Posterior urethral valves, unilateral reflux and renal dysplasia: a syndrome. *J Urol* 1982 Nov;128(5):994-7.
<http://www.ncbi.nlm.nih.gov/pubmed/7176067>
14. Rittenberg MH, Hulbert WC, Snyder HM 3rd, et al. Protective factors in posterior urethral valves. *J Urol* 1988 Nov;140(5):993-6.
<http://www.ncbi.nlm.nih.gov/pubmed/3139895>
15. Cuckow PM, Dinneen MD, Risdon RA, et al. Long-term renal function in the posterior urethral valves, unilateral reflux and renal dysplasia syndrome. *J Urol* 1997 Sep;158(3 Pt 2):1004-7.
<http://www.ncbi.nlm.nih.gov/pubmed/9258130>
16. Kleppe S, Schmitt J, Geipel A, et al. Impact of prenatal urinomas in patients with posterior urethral valves and postnatal renal function. *J Perinat Med* 2006;34(5):425-8.
<http://www.ncbi.nlm.nih.gov/pubmed/16965232>
17. Dinneen MD, Dhillon HK, Ward HC, et al. Antenatal diagnosis of posterior urethral valves. *Br J Urol* 1993 Sep;72(3):364-9.
<http://www.ncbi.nlm.nih.gov/pubmed/8220998>
18. Freedman AL, Johnson MP, Gonzalez R. Fetal therapy for obstructive uropathy: past, present, future? *Pediatr Nephrol* 2000 Feb;14(2):167-76.
<http://www.ncbi.nlm.nih.gov/pubmed/10684370>
19. McLorie G, Farhat W, Khoury A, et al. Outcome analysis of vesicoamniotic shunting in a comprehensive population. *J Urol* 2001 Sep;166(3):1036-40.
<http://www.ncbi.nlm.nih.gov/pubmed/11490292>
20. Salam MA. Posterior urethral valve: Outcome of antenatal intervention. *Int J Urol* 2006 Oct;13(10):1317-22.
<http://www.ncbi.nlm.nih.gov/pubmed/17010011>
21. Babu R, Kumar R. Early outcome following diathermy versus cold knife ablation of posterior urethral valves. *J Pediatr Urol* 2012 Mar 12. [Epub ahead of print]
<http://www.ncbi.nlm.nih.gov/pubmed/22417679>
22. Krahn CG, Johnson HW. Cutaneous vesicostomy in the young child: indications and results. *Urology* 1993 Jun;41(6):558-63.
<http://www.ncbi.nlm.nih.gov/pubmed/8516992>
23. Kim YH, Horowitz M, Combs A, et al. Comparative urodynamic findings after primary valve ablation, vesicostomy or proximal diversion. *J Urol* 1996 Aug;156(2 Pt 2):673-6.
<http://www.ncbi.nlm.nih.gov/pubmed/8683757>
24. Podesta M, Ruarte AC, Gargiulo C, et al. Bladder function associated with posterior urethral valves after primary valve ablation or proximal urinary diversion in children and adolescents. *J Urol* 2002 Oct;168(4 Pt 2):1830-5; discussion 1835.
<http://www.ncbi.nlm.nih.gov/pubmed/12352370>

25. Novak ME, Gonzales ET Jr. Single-stage reconstruction of urinary tract after loop cutaneous ureterostomy. *Urology* 1978 Feb;11(2):134-8.
<http://www.ncbi.nlm.nih.gov/pubmed/628990>
26. Sober I. Pelviureterostomy-en-Y. *J Urol* 1972 Mar;107(3):473-5. [no abstract available]
<http://www.ncbi.nlm.nih.gov/pubmed/5010719>
27. Williams DI, Cromie WJ. Ring ureterostomy. *Br J Urol* 1975;47(7):789-92.
<http://www.ncbi.nlm.nih.gov/pubmed/1222345>
28. Scott JE. Management of congenital posterior urethral valves. *Br J Urol* 1985 Feb;57(1):71-7.
<http://www.ncbi.nlm.nih.gov/pubmed/3971107>
29. Brandstrom, P, Esbjorner, E, Herthelius, M, et al. The Swedish reflux trial in children: III. Urinary tract infection pattern. *J Urol* 2010 Jul;184(1):286-91.
<http://www.ncbi.nlm.nih.gov/pubmed/20488494>
30. Singh-Grewal D, Maccessi J, Craig J. Circumcision for the prevention of urinary tract infection in boys: a systematic review of randomised trials and observational studies. *Arch Dis Child* 2005 Aug;90(8):853-8.
<http://www.ncbi.nlm.nih.gov/pubmed/15890696>
31. Cozzi, DA, Morgante, D, Frediani, S, et al. Posterior urethral valves: relationship between vesicoureteral reflux and renal function. *Urology* 2011 May;77(5):1209-12.
<http://www.ncbi.nlm.nih.gov/pubmed/21109298>
32. Bellinger MF. Ureterocystoplasty: a unique method for vesical augmentation in children. *J Urol* 1993 Apr;149(4):811-3.
<http://www.ncbi.nlm.nih.gov/pubmed/8455246>
33. Misseri, R, Combs, AJ, Horowitz, M, et al. Myogenic failure in posterior urethral valve disease: real or imagined? *J Urol*. 2002 Oct;168(4 Pt 2):1844-8; discussion 8.
<http://www.ncbi.nlm.nih.gov/pubmed/12352373>
34. Kim, YH, Horowitz, M, Combs, AJ, et al. Management of posterior urethral valves on the basis of urodynamic findings. *J Urol* 1997 Sep;158(3 Pt 2):1011-6.
<http://www.ncbi.nlm.nih.gov/pubmed/9258132>
35. Kamal MM, El-Hefnawy AS, Soliman S, et al. Impact of posterior urethral valves on pediatric renal transplantation: a single-center comparative study of 297 cases. *Pediatr Transplant* 2011 Aug;15(5):482-7.
<http://www.ncbi.nlm.nih.gov/pubmed/21599816>
36. Fine MS, Smith KM, Shrivastava D, et al. Posterior urethral valve treatments and outcomes in children receiving kidney transplants. *J Urol* 2011 Jun;185(6 Suppl):2507-11.
<http://www.ncbi.nlm.nih.gov/pubmed/21527196>
37. DeFoor W, Tackett L, Minevich E, et al. Successful renal transplantation in children with posterior urethral valves. *J Urol* 2003 Dec;170(6 Pt 1):2402-4.
<http://www.ncbi.nlm.nih.gov/pubmed/14634437>
38. Salomon L, Fontaine E, Guest G, et al. Role of the bladder in delayed failure of kidney transplants in boys with posterior urethral valves. *J Urol* 2000 Apr;163(4):1282-5.
<http://www.ncbi.nlm.nih.gov/pubmed/10737529>

19. PAEDIATRIC UROLOGICAL TRAUMA

19.1 Background

Trauma is the leading cause of morbidity and mortality in children and is responsible for more childhood deaths than the total of all other causes (1). In about 3% of children seen at paediatric hospital trauma centres, there is significant involvement of the genitourinary tract (2). This is caused by either blunt injuries from falls, car accidents, sports injuries, physical assault, and sexual abuse, or penetrating injuries, usually due to falls onto sharp objects or from gunshot or knife wounds.

19.2 Paediatric renal trauma

In blunt abdominal trauma, the kidney is the most commonly affected organ, accounting for about 10% of all blunt abdominal injuries (1).

Children are more likely than adults to sustain renal injuries after blunt trauma because of their anatomy. Compared to an adult kidney, a child's kidney is larger in relation to the rest of the body and often retains foetal lobulations, so that blunt trauma is more likely to lead to a local parenchymal disruption. The

paediatric kidney is also less well protected than the adult kidney. Children have less perirenal fat, much weaker abdominal muscles, and a less ossified and therefore much more elastic and compressible thoracic cage (3).

Blunt renal trauma is usually a result of sudden deceleration of the child's body, particularly due to sport accidents, falls, and contact with blunt objects. Deceleration or crush injuries result in contusion, laceration or avulsion of the less well-protected paediatric renal parenchyma.

19.2.1 **Diagnosis**

In a child who has sustained blunt abdominal trauma, renal involvement can often be predicted from the history, physical examination and laboratory evaluation. Renal involvement may be associated with abdominal or flank tenderness, lower rib fractures, fractures or vertebral pedicles, trunk contusions and abrasions, and haematuria.

19.2.1.1 *Haematuria*

Haematuria may be a reliable finding. In severe renal injuries, 65% suffer gross haematuria and 33% micro-haematuria, while only 2% have no haematuria at all (4).

The radiographic evaluation of children with suspected renal trauma remains controversial. Some centres rely on the presence of haematuria to diagnose renal trauma, with a threshold for renal involvement of 50 RBCs/HPF. Although this may be a reliable threshold for significant micro-haematuria in trauma, there have been many reports of significant renal injuries that manifest with little or even no blood in the urine (5). It is therefore compulsory to consider all the clinical aspects involved, including the history, physical examination, consciousness of the child, overall clinical status and laboratory findings to decide on the diagnostic algorithm and whether or not a child needs further imaging studies.

19.2.1.2 *Blood pressure*

It is important to consider that children, unlike adults, are able to maintain their blood pressure, even in the presence of hypovolaemia, due to compliance of the vascular tree and mechanisms for cardiac compensation (6).

Because blood pressure is an unreliable predictor of renal involvement in children, some centres recommend imaging of the urinary tract in children with any degree of haematuria following significant abdominal trauma.

19.2.1.2 *Choice of imaging method*

Nowadays, computed tomography (CT) is the best imaging method for renal involvement in children. CT scanning is the cornerstone of modern staging of blunt renal injuries especially when it comes to grading the severity of renal trauma. Renal injuries are classified according to the kidney injury scale of the American Association for the Surgery of Trauma (Table 15) (7).

CT scanning is quite rapid and usually performed with the injection of contrast media. To detect extravasation, a second series of images is necessary since the initial series usually finishes 60 seconds after injection of the contrast material and may therefore fail to detect urinary extravasation (8).

In acute trauma ultrasound may be used as a screening tool and for reliably following the course of renal injury. However, ultrasound is of limited value in the initial and acute evaluation of trauma. The standard IVP is a good alternative imaging method if a CT scan is not available. It is superior to ultrasound but not as good as CT scanning for diagnostic purposes.

Table 15: Renal injury classified according to the kidney injury scale of the American Association for the Surgery of Trauma (7).

Grade	Type of injury	Description
I	Contusion	Microscopic or gross haematuria
	Haematoma	Normal urological studies
II	Haematoma	Non-expanding subcapsular haematoma
	Laceration	Laceration of the cortex of less than 1.0 cm
III	Laceration	Laceration > 1.0 cm without rupture of collecting system
IV	Laceration	Through the cortex, medulla and collecting system
	Vascular	Vascular injury
V	Laceration	Completely shattered kidney
	Vascular	Avulsion of the renal hilum

19.2.2 Treatment

The modern management of trauma is multidisciplinary, requiring paediatricians, emergency physicians, surgeons, urologists, and other specialties as required.

Non-surgical conservative management with bed rest, fluids and monitoring has become the standard approach for treating blunt renal trauma. Even in high-grade renal injuries, a conservative approach is effective and recommended for stable children. However, this approach requires close clinical observation, serial CT scans, and frequent re-assessment of the patient's overall condition.

Absolute indications for surgery include persistent bleeding into an expanding or unconfined haematoma. Relative indications for surgery are massive urinary extravasation and extensive non-viable renal tissue (9).

19.2.3 Guidelines for the diagnosis and treatment of paediatric renal trauma

Recommendation	GR
Imaging is recommended in all children who have sustained a blunt or penetrating trauma with any level of haematuria, especially when the history reveals a deceleration trauma, direct flank trauma or a fall from a height.	B
Rapid spiral CT scanning is the cornerstone in the diagnostic work-up and allows accurate staging.	B
Most injured kidneys can be managed conservatively.	B
Haemodynamic instability and a Grade V renal injury are absolute indications for surgical intervention.	A

19.3 Paediatric ureteral trauma

Injuries to the ureter are rare. The ureter is well protected; the upper part is protected by its close approximation to the vertebral column and paraspinal muscles and the lower part by its route through the bony pelvis. In addition, the ureter is a small target, and both flexible and mobile. This also means that ureteral injuries are caused more often by penetrating trauma than blunt trauma (10). Since the ureter is the sole conduit for urinary transport between the kidney and the bladder, any ureteral injury can threaten the function of the ipsilateral kidney.

19.3.1 Diagnosis

Since there are no classical clinical symptoms suggestive of ureteral trauma, it is important to carry out a careful diagnostic work-up using different imaging modalities. Unfortunately, initial imaging studies, such as IVP and routine CT scans, are unreliable; a study of 11 disruptions of the ureteropelvic junction found that 72% had a normal or non-diagnostic IVP on initial studies (10). Diagnostic accuracy of CT scanning can be improved by performing a delayed CT scan up to 10 minutes after injection of the contrast material (11). The most sensitive diagnostic test is a retrograde pyelogram.

Quite a few patients present several days after the injury, when the urinoma produces flank and abdominal pain, nausea and fever.

Because the symptoms may often be quite vague, it is important to remain suspicious for a potential undiagnosed urinary injury following significant blunt abdominal trauma in a child.

19.3.2 Treatment

Immediate repair during abdominal exploration is rare. Minimally invasive procedures are the method of choice, especially since many ureteral injuries are diagnosed late after the traumatic event. Percutaneous or nephrostomy tube drainage of urinomas can be successful, as well as internal stenting of ureteral injuries (12).

If endoscopic management is not possible, primary repair of partial lacerations should be followed by internal stenting. The management of complete lacerations, avulsions or crush injuries depends on the amount of ureter lost and its location. If there is an adequate healthy length of ureter, a primary ureteroureterostomy can be performed. If primary re-anastomosis is not achievable, distal ureteral injuries can be managed using a psoas bladder hitch, Boari flap or even nephropexy. Proximal injuries can be managed using transureteroureterostomy, autotransplantation or ureteral replacement with bowel or appendix (13).

19.3.3 Guidelines for the diagnosis and treatment of paediatric ureteral trauma

Recommendations	GR
Retrograde pyelogram is the most sensitive diagnostic method and is the method of choice. However, in the initial phase of an injury, it is very likely that ureteral injuries will not be detected by routine imaging methods, including contrast-enhanced spiral CT.	A
Endoscopic treatment is the method of choice, such as internal stenting or drainage of a urinoma, either percutaneously or via a nephrostomy tube.	B
For distal and proximal ureteral injuries, open procedures are the methods of choice.	B
For distal injuries, they include direct re-anastomosis and ureteroneocystostomy.	B
For proximal injuries, they include transureteroureterostomy, ureteral replacement with bowel or appendix, or even autotransplantation.	B

19.4 Paediatric bladder injuries

The paediatric bladder is less protected than the adult bladder, and is therefore more susceptible to injuries than the adult bladder, especially when it is full, due to:

- The paediatric bladder has a higher position in the abdomen and is exposed above the bony pelvis.
- The abdominal wall provides less muscular protection.
- There is less pelvic and abdominal fat surrounding the bladder to cushion it in trauma.

Blunt trauma is the most common cause of significant bladder injury. In adults, bladder injury is often associated with pelvic fractures. This is less common in children because the paediatric bladder sits above the pelvic ring. Thus, only 57% of children with pelvic fractures also had a bladder injury compared to 89% of adults (14).

19.4.1 Diagnosis

The characteristic signs of bladder injury are suprapubic pain and tenderness, an inability to urinate, and gross haematuria (95% of injuries). Patients with a pelvic fracture and gross haematuria present with a bladder rupture in up to 45% of cases (15).

The diagnosis of bladder rupture can be difficult in some cases. The bladder should be imaged both when fully distended and after drainage using standard radiography or a CT scan. The best results can be achieved by retrograde filling of the bladder using a catheter. Despite advances in CT imaging, the bladder must still be filled to capacity to accurately diagnose a possible bladder injury (16).

Blunt injuries to the bladder are categorized as:

- contusions with damage to the bladder mucosa or muscle, without loss of bladder wall continuity or extravasation, or,
- ruptures, which are either intraperitoneal or extraperitoneal.

Intraperitoneal bladder ruptures are more common in children because of the bladder's exposed position and the acute increase in pressure during trauma. These cause the bladder to burst at its weakest point, i.e. the dome.

Extraperitoneal lesions occur in the lower half of the bladder and are almost always associated with pelvic fractures. A cystogram will show extravasation into the perivesical soft tissue in a typical flame pattern and the contrast material is confined to the pelvis.

19.4.2 Treatment

Contusions usually present with varying degrees of haematuria and are treated with catheter drainage alone.

19.4.2.1 Intraperitoneal injuries

The accepted management of intraperitoneal bladder ruptures is open surgical exploration and primary repair. Post-operative drainage with a suprapubic tube is mandatory. Recent data suggest that transurethral drainage may be as effective, with fewer complications, resulting in shorter periods of diversion (17). Usually, after about 7-10 days, a repeat cystogram is performed to ensure healing is taking place properly.

19.4.2.2 Extraperitoneal injuries

Non-operative management with catheter drainage for 7-10 days alone is the method of choice for extraperitoneal bladder rupture. However, if there are bone fragments within the bladder, these must be removed and the bladder must then be repaired and drained, according to the principles for treating intraperitoneal ruptures (18).

19.4.3 Guidelines for the diagnosis and treatment of paediatric bladder injuries

Recommendations	GR
Retrograde cystography will allow for an accurate diagnosis, provided that the bladder has been filled full to its capacity and an additional film is taken after drainage.	A
Extraperitoneal bladder ruptures are usually managed conservatively with a transurethral catheter left in place for 7-10 days.	A
Intraperitoneal bladder ruptures require immediate surgical exploration and repair as well as post-operative drainage for 7-10 days.	A

19.5 Paediatric urethral injuries

Except for the penile part of the urethra, the paediatric urethra is quite well protected. In addition, its shape and elasticity mean the urethra is seldom injured by trauma. However, a urethral injury should be suspected in any patient with a pelvic fracture or significant trauma to the perineum until confirmed otherwise by a diagnostic work-up.

19.5.1 Diagnosis

Patients with suspected urethral trauma and pelvic fractures usually present with a history of severe trauma, often involving other organ systems.

Signs of urethral injury are blood at the meatus, gross haematuria, and pain during voiding or an inability to void. There may also be perineal swelling and haematoma involving the scrotum.

A rectal examination to determine the position and fixation of the prostate is important in any male with a suspected urethral injury. The prostate, as well as the bladder, may be displaced up out of the pelvis, especially in membranous urethral trauma,

Radiographic evaluation of the urethra requires a retrograde urethrogram. It is important to expose the entire urethral length, including the bladder neck. If a catheter has already been placed by someone else and there is suspected urethral trauma, the catheter should be left in place and should not be removed. Instead, a small infant feeding tube can be placed into the distal urethra along the catheter to allow the injection of contrast material for a diagnostic scan (19).

19.5.2 Treatment

Since many of these patients are unstable, the urologist's initial responsibility is to provide a method of draining and monitoring urine output.

A transurethral catheter should only be inserted if there is a history of voiding after the traumatic event, and if a rectal and pelvic examination, as described above, has not suggested a urethral rupture. If the catheter does not pass easily, an immediate retrograde urethrogram should be performed.

A suprapubic tube may be placed in the emergency department percutaneously, or even in the operating room, if the patient has to undergo immediate exploration because of other life-threatening injuries.

There are often no associated injuries with a bulbous urethral or straddle injury and management is therefore usually straightforward. In these cases, a transurethral catheter is the best option for preventing urethral bleeding and/or painful voiding (20).

The initial management of posterior urethral injuries remains controversial, mainly regarding the long-term results with primary realignment compared to simple suprapubic drainage with later reconstruction.

The main goals in the surgical repair of posterior urethral injuries are:

- providing a stricture-free urethra
- avoiding the complications of urinary incontinence and impotence.

Suprapubic drainage and late urethral reconstruction was first attempted because immediate surgical repair had a poor outcome, with significant bleeding and high rates of incontinence (21%) and impotence in up to 56% of cases (21). In adults, a study of the success rates of delayed repair reported re-structure rates of 11-30%, continence rates of 90-95% and impotence rates of 62-68% (22). However, in children, there is much less experience with delayed repair. The largest paediatric series of delayed repair in 68 boys reported a success rate of 90% (23). Another study reported strictures and impotence in 67% of boys, although all the boys were continent (22).

An alternative to providing initial suprapubic drainage and delayed repair is primary realignment of the urethra via a catheter. The catheter is usually put in place during open cystostomy by passing it from either the bladder neck or meatus and through the injured segment. In a series of 14 children undergoing this procedure,

this resulted in a stricture rate of 29% and incontinence in 7% (24).

19.5.3 Guidelines for the diagnosis and treatment of paediatric trauma

Recommendations	GR
Imaging of the urethra with a retrograde urethrogram is mandatory in suspected urethral trauma.	A
Rectal examination is recommended to determine the position of the prostate.	B
Bulbous urethral injuries can usually be managed conservatively with a transurethral catheter.	B
There is still controversy about the optimal management for posterior urethral disruption. The options include primary reconstruction; primary drainage with a suprapubic catheter alone and delayed repair; primary re-alignment with a transurethral catheter.	C

19.6 References

- McAninch JW, Carroll PR, Klosterman PW, et al. Renal reconstruction after injury. *J Urol* 1991 May;145(5):932-7.
<http://www.ncbi.nlm.nih.gov/pubmed/2016804>
- McAleer IM, Kaplan GW, Scherz HC, et al. Genitourinary trauma in the pediatric patient. *Urology* 1993 Nov;42(5):563-7; discussion 567-8.
<http://www.ncbi.nlm.nih.gov/pubmed/8236601>
- Miller RC, Sterioff S Jr, Drucker WR, et al. The incidental discovery of occult abdominal tumors in children following blunt abdominal trauma. *J Trauma* 1966 Jan;6(1):99-106. [No abstract available].
<http://www.ncbi.nlm.nih.gov/pubmed/5901856>
- Stalker HP, Kaufman RA, Stedje K. The significance of hematuria in children after blunt abdominal trauma. *AJR Am J Roentgenol* 1990 Mar;154(3):569-71.
<http://www.ncbi.nlm.nih.gov/pubmed/2106223>
- Mee SL, McAninch JW, Robinson AL, et al. Radiographic assessment of renal trauma: a 10-year prospective study of patient selection. *J Urol* 1989 May;141(5):1095-8.
<http://www.ncbi.nlm.nih.gov/pubmed/2709493>
- Stein JP, Kaji DM, Eastham J, et al. Blunt renal trauma in the pediatric population: indications for radiographic evaluation. *Urology* 1994 Sep;44(3):406-10.
<http://www.ncbi.nlm.nih.gov/pubmed/8073555>
- Moore EE, Shackford SR, Pachter HL, et al. Organ injury scaling: spleen, liver, and kidney. *J Trauma*. 1989 Dec;29(12):1664-6.
<http://www.ncbi.nlm.nih.gov/pubmed/2593197>
- Carpio F, Morey AF. Radiographic staging of renal injuries. *World J Urol* 1999 Apr;17(2):66-70.
<http://www.ncbi.nlm.nih.gov/pubmed/10367363>
- Radmayr C, Oswald J, Müller E, et al. Blunt renal trauma in children: 26 years clinical experience in an alpine region. *Eur Urol* 2002 Sep;42(3):297-300.
<http://www.ncbi.nlm.nih.gov/pubmed/12234516>
- Presti JC Jr, Carroll PR, McAninch JW. Ureteral and renal pelvic injuries from external trauma: diagnosis and management. *J Trauma* 1989 Mar;29(3):370-4.
<http://www.ncbi.nlm.nih.gov/pubmed/2926851>
- Mulligan JM, Cagiannos I, Collins JP, et al. Ureteropelvic junction disruption secondary to blunt trauma: excretory phase imaging (delayed films) should help prevent a missed diagnosis. *J Urol* 1998 Jan;159(1):67-70.
<http://www.ncbi.nlm.nih.gov/pubmed/9400439>
- al-Ali M, Haddad LF. The late treatment of 63 overlooked or complicated ureteral missile injuries: the promise of nephrostomy and role of autotransplantation. *J Urol* 1996 Dec;156(6):1918-21.
<http://www.ncbi.nlm.nih.gov/pubmed/8911355>
- Fernandez Fernandez A, Soria Ruiz S, Gomez Martinez I, et al. Blunt traumatic rupture of the high right ureter, repaired with appendix interposition. *Urol Int* 1994;53(2):97-8.
<http://www.ncbi.nlm.nih.gov/pubmed/7801425>
- Sivit CJ, Cutting JP, Eichelberger MR. CT diagnosis and localization of rupture of the bladder in children with blunt abdominal trauma: significance of contrast material extravasation in the pelvis. *AJR Am J Roentgenol* 1995 May;164(5):1243-6.
<http://www.ncbi.nlm.nih.gov/pubmed/7717239>
- Hochberg E, Stone NN. Bladder rupture associated with pelvic fracture due to blunt trauma. *Urology* 1993 Jun;41(6):531-3.
<http://www.ncbi.nlm.nih.gov/pubmed/8516988>

16. Haas CA, Brown SL, Spirnak JP. Limitations of routine spiral computerized tomography in the evaluation of bladder trauma. *J Urol* 1999 Jul;162(1):51-2.
<http://www.ncbi.nlm.nih.gov/pubmed/10379738>
17. Volpe MA, Pachter EM, Scalea TM, et al. Is there a difference in outcome when treating traumatic intraperitoneal bladder rupture with or without a suprapubic tube? *J Urol* 1999 Apr;161(4):1103-5.
<http://www.ncbi.nlm.nih.gov/pubmed/10081847>
18. Richardson JR Jr, Leadbetter GW Jr. Non-operative treatment of the ruptured bladder. *J Urol* 1975 Aug;114(2):213-6.
<http://www.ncbi.nlm.nih.gov/pubmed/1159910>
19. Cass AS, Godec CJ. Urethral injury due to external trauma. *Urology* 1978 Jun;11(6):607-11.
<http://www.ncbi.nlm.nih.gov/pubmed/675928>
20. Pokorny M, Pontes JE, Pierce JM Jr. Urological injuries associated with pelvic trauma. *J Urol* 1979 Apr;121(4):455-7.
<http://www.ncbi.nlm.nih.gov/pubmed/439217>
21. Elliott DS, Barrett DM. Long-term followup and evaluation of primary realignment of posterior urethral disruptions. *J Urol* 1997 Mar;157(3):814-6.
<http://www.ncbi.nlm.nih.gov/pubmed/9072573>
22. Boone TB, Wilson WT, Husmann DA. Postpubertal genitourinary function following posterior urethral disruptions in children. *J Urol* 1992 Oct;148(4):1232-4.
<http://www.ncbi.nlm.nih.gov/pubmed/1404642>
23. Koraitim MM. Posttraumatic posterior urethral strictures in children: a 20-year experience. *J Urol* 1997 Feb;157(2):641-5.
<http://www.ncbi.nlm.nih.gov/pubmed/8996388>
24. Avanoğlu A, Ulman I, Herek O, et al. Posterior urethral injuries in children. *Br J Urol* 1996 Apr;77(4):597-600.
<http://www.ncbi.nlm.nih.gov/pubmed/8777627>

20. POST-OPERATIVE FLUID MANAGEMENT

20.1 Background

It is often stated that children are not simply small adults. Children are growing and developing organisms, with specific metabolic features. Compared to adults, children have a different total body fluid distribution, renal physiology and electrolyte requirements, as well as weaker cardiovascular compensation mechanisms (1). Because they are developing organisms, children have a high metabolic rate and low body stores of fat and other nutrients, which means they are more susceptible to metabolic disturbances caused by surgical stress (2). The metabolic response to anaesthesia and surgery in infants and children is related to the severity of the operation (3).

20.2 Pre-operative fasting

Pre-operative fasting has been advocated for elective surgery to avoid the complications associated with pulmonary aspiration during induction of anaesthesia. Table 16 gives the current guidelines for pre-operative fasting for elective surgery (4,5).

Table 16: Pre-operative fasting times for elective surgery

Ingested material	Minimum fasting period (h)
Clear liquids	2
Breast milk	4
Infant formula	4 (< 3 months old) to 6 (> 3 months old)
Non-human milk	6
Light meal	6

Although hypoglycaemia is an important issue in children, research has shown that hypoglycaemia is uncommon if children are still fed up to 4 h before the induction of anaesthesia (6). Newborns often have low glycogen stores and impaired gluconeogenesis, both of which can be helped by limiting the period of pre-operative starvation and feeding with glucose-containing solutions. It is important to monitor blood glucose

and to adjust the glucose supply continuously in neonates and those children who are small for their age, as this helps to prevent excessive fluctuation in blood glucose levels (7).

20.3 Maintenance therapy and intra-operative fluid therapy

Generally, the anaesthetist is responsible for intra-operative management and the surgeon is responsible for post-operative instructions. The goal of intra-operative fluid management is to sustain homeostasis by providing the appropriate amount of parenteral fluid; this maintains adequate intravascular volume, cardiac output and oxygen delivery to tissues at a time when normal physiological functions have been altered by surgical stress and anaesthetic agents (7).

The fluids for maintenance therapy replace losses from two sources: insensible (evaporation) and urinary loss. They do not take replace blood loss or third-space fluid loss into the interstitial space or gut. The main formulae for calculating the daily maintenance requirement for water requirement have not changed in the past 50 years (Table 17) (8). Calculations have shown that anaesthetised and non-anaesthetised children have similar fluid requirements (9).

The combination of maintenance fluid and electrolyte requirements results in a hypotonic electrolyte solution. The usual intravenous maintenance fluid given to children by paediatricians is one-quarter to one-third strength saline (4,10).

Table 17: Hourly and daily fluid requirements according to body weight

Body weight	Hourly	Daily
< 10 kg	4 mL/kg	100 mL/kg
10-20 kg	40 mL + 2 mL/kg; > 10 kg	1000 mL + 50 mL/kg; > 10 kg
> 20 kg	60 mL + 1 mL/kg; > 20 kg	1500 mL + 20 mL/kg; > 20 kg

The fasting deficit is calculated by multiplying the hourly maintenance fluid requirement by the number of hours of fluid restriction. It is recommended that 50% of the fasting deficit is replaced in the first hour and 25% in the second and third hours (11). Berry (1986) proposed simplified guidelines for fluid administration according to the child's age and severity of surgical trauma (12) (Table 18).

Table 18: Intra-operative fluid management adapted for children fasted for 6-8 h, following the classical recommendation 'nil per oral after midnight'

Furman, et al. (11)			
Hour of fluid replacement	Maintenance fluid	Fasting deficit replacement	Persistent losses
First hour	As Table 16	50%	Third space + blood loss replacement
Second hour	As Table 16	25%	Third space + blood loss replacement
Third hour	As Table 16	25%	Third space + blood loss replacement
Berry (12)			
First hour	≤ 3 years: 25 mL/kg ≥ 4 years: 15 mL/kg		Blood replacement 1:1 with blood or colloid or 3:1 with crystalloids
All other hours	Maintenance volume = 4 mL/kg/h Maintenance + mild trauma = 6 mL/kg/h Maintenance + moderate trauma = 8 mL/kg/h Maintenance + severe trauma = 10 mL/kg/h		Blood replacement 1:1 with blood or colloid or 3:1 with crystalloids

* Reduce the amount of fluid given during the first hour if children are fasting for a shorter period of time, or if the child was already being given intravenous fluid prior to surgery.

Five percent dextrose with one-quarter- to half-normal saline is often used as a maintenance fluid, while balanced salt solution or normal saline is used as replacement fluid. Blood losses are replaced with a 1:1 ratio of blood or colloid or a 3:1 ratio of crystalloid. However, the administration of a large volume of normal saline can cause dilutional acidosis or hyperchloremic acidosis, while a large volume of balanced salt solution, such as lactated Ringer's solution, can decrease serum osmolality, which is not beneficial in patients with decreased

intracranial compliance. If appropriate, albumin, plasma, synthetic colloids, and blood should be administered (7).

Third-space losses may vary from 1 mL/kg/h for a minor surgical procedure to 15-20 mL/kg/h for major abdominal procedures, or even up to 50 mL/kg/h for surgery of necrotising enterocolitis in premature infants. Third-space losses should be replaced with crystalloids (normal saline or Ringer's lactate) (4).

Most of the fluids required during surgery are needed to replace fasting deficit or third-space losses, which are mainly extracellular fluids. Hydrating solutions should contain high concentrations of sodium and chloride and low concentrations of bicarbonate, calcium and potassium.

Intra-operative hypoglycaemia is rare in children. In contrast, hyperglycaemia is commonly encountered during anaesthesia and surgery. The replacement fluid should be free of dextrose or should not have > 1% dextrose. Current recommendations include the use of low-dextrose-containing solutions for maintenance fluid therapy, except in patients who are at high risk of hypoglycaemia (1,10). Intra-operative administration of glucose-free isotonic hydrating solutions should be the routine practice for most procedures in children over 4-5 years of age. In infants and young children, 5% dextrose solutions should be avoided, but it is appropriate to use 1% or 2% dextrose in lactated Ringer's solution (4).

20.4 Post-operative fluid management

During the post-operative period, the fundamental principle is to monitor gastrointestinal function and to continue oral or enteral nutrition as much as possible (2), while remembering that withholding oral fluids post-operatively from children undergoing day surgery helps prevent vomiting (13). In minor surgical procedures, intra-operative administration of large volumes of crystalloids is associated with a reduced incidence of post-operative nausea and vomiting after anaesthesia in both paediatric and adult patients (14). Berry's fluid replacement guidelines can be followed, provided the child is given lactated Ringer's solution or polyionique B66, which has an osmolarity similar to plasma (15).

It is not obligatory to check serum chemistry after uncomplicated surgery in children with normal pre-operative renal and hepatic function. However, if oral intake has been postponed for > 24 h (e.g. as in intestinal surgery), there is an increased risk of electrolyte abnormalities, requiring further assessment and subsequent management, particularly with potassium. Post-operative findings, such as decreased bowel movements and ileus, may be signs of hypokalemia, which may be corrected with a solution of 20 mmol/L potassium and an infusion rate of not more than 3 mmol/kg/day. The potassium should be given via peripheral venous access if the duration of infusion is not expected to exceed 5 days, or via central venous access when long-term parenteral nutrition is necessary.

The goals of fluid therapy are to provide basic metabolic requirements and to compensate for gastrointestinal and additional losses. If hypovolemia is present, it should be treated rapidly. Hyponatremia is the most frequent electrolyte disorder in the post-operative period (15,16). This means that hypotonic fluid should not be routinely administered to hospitalised children because they have several stimuli for producing arginine vasopressin and are therefore at high risk for developing hyponatremia (4,15,17-20). The preferred fluids for maintenance therapy are 0.45% saline with dextrose or isotonic fluids, in the absence of a specific indication for 0.25% saline. It is also advisable to administer isotonic fluids intra-operatively and also immediately post-operatively, albeit at two-thirds of the calculated maintenance rate in the recovery room. Fluid composition should balance high sodium requirements, energy requirements and solution osmolarity. The extra losses from gastric or chest tubes should be replaced with lactated Ringer's solution. Fluid that has been given to dilute medications must also be taken into account (4).

Children who undergo interventions to relieve any kind of obstructive diseases deserve particular attention, especially the risk of polyuria due to post-obstructive diuresis. In children who develop polyuria, it is important to monitor fluid intake and urine output, as well as renal function and serum electrolytes.

If necessary, clinicians should not feel any hesitation about consulting with a paediatric nephrologist.

20.5 Post-operative fasting

It has been reported that fasting reduces the risk of vomiting by up to 50% (13,21,22). However, a recent study has found that, if children were freely allowed to drink and eat when they felt ready or requested it, the incidence of vomiting did not increase and the children felt happier and were significantly less bothered by pain than children who were fasting (23). The mean times until first drink and first eating in the children who were free to eat or drink were 108 and 270 min, respectively, which were 4 h and 3 h earlier than in the fasting group. Previous studies have suggested that gastric motility returns to normal 1 h after emergence from anaesthesia in children who have undergone non-abdominal surgery (24). The first oral intake in children at 1 h after emergence from anaesthesia for minor surgery did not cause an increase in the incidence of vomiting, provided that the fluid ingested was at body temperature (25). The EAU Panel members therefore recommend encouraging an early intake of fluid in children who have undergone minor or non-abdominal urological surgery.

20.6 Summary conclusions and recommendations

Conclusion	LE
Children are not simply smaller physiological versions of adults. They have their own unique metabolic features, which must be considered during surgery.	2

Recommendations	GR
Pre-operative fasting periods for elective surgeries (up to 4 h) can be shorter than normally used.	B
Care should be taken for hyperglycaemia, which is common in children, compared to intra-operative hypoglycaemia, which is very rare. Fluids with lower dextrose concentrations should therefore be considered.	B
Avoid the routine use of hypotonic fluid in hospitalised children because they are at high risk of developing hyponatremia.	A
There is an increased risk of electrolyte abnormalities in children undergoing surgery. It is therefore essential to measure the baseline and daily levels of serum electrolytes, glucose, urea and/or creatinine in every child who receives intravenous fluids, especially in intestinal surgery (e.g. ileal augmentation), regardless of the type of solution chosen.	B
In patients treated with minor surgical procedures, early oral fluid intake should be encouraged.	A

20.7 References

- Nair SG, Balachandran R. Perioperative fluid and electrolyte management in pediatric patients. *Indian J Anaesth* 2004;48(5):355-64.
<http://medind.nic.in/iadt/t04/i5/iadt04i5p355.pdf>
- Imura K, Okada A. Perioperative nutrition and metabolism in pediatric patients. *World J Surg* 2000 Dec;24(12):1498-502.
<http://www.ncbi.nlm.nih.gov/pubmed/11193714>
- Ward Platt MP, Tarbit MJ, Aynsley-Green A. The effects of anesthesia and surgery on metabolic homeostasis in infancy and childhood. *J Pediatr Surg* 1990 May;25(5):472-8.
<http://www.ncbi.nlm.nih.gov/pubmed/2191106>
- Murat I, Dubois MC. Perioperative fluid therapy in pediatrics. *Paediatr Anaesth* 2008 May;18(5):363-70.
<http://www.ncbi.nlm.nih.gov/pubmed/18312509>
- ASA Task Force on preoperative fasting. Practice guidelines for preoperative fasting and the use of pharmacologic agents to reduce the risk of pulmonary aspiration: application to healthy patients undergoing elective procedures. *Anesthesiology* 1999 Mar;90(3):896-905.
<http://www.ncbi.nlm.nih.gov/pubmed/10078693>
- Redfern N, Addison GM, Meakin G. Blood glucose in anaesthetised children: comparison of blood glucose concentrations in children fasted for morning and afternoon surgery. *Anaesthesia* 1986 Mar;41(3):272-5.
<http://www.ncbi.nlm.nih.gov/pubmed/3963330>
- Leelanukrom R, Cunliffe M. Intraoperative fluid and glucose management in children. *Paediatr Anaesth* 2000;10(4):353-9.
<http://www.ncbi.nlm.nih.gov/pubmed/10886690>
- Holliday M, Segar W. The maintenance need for water in parenteral fluid therapy. *Pediatrics* 1957 May;19(5):823-32. [no abstract available]
<http://www.ncbi.nlm.nih.gov/pubmed/13431307>
- Lindahl SG. Energy expenditure and fluid and electrolyte requirements in anesthetized infants and children. *Anesthesiology* 1988 Sep;69(3):377-82.
<http://www.ncbi.nlm.nih.gov/pubmed/3415017>
- Bailey AG, McNaull PP, Jooste E, et al. Perioperative crystalloid and colloid fluid management in children: where are we and how did we get here? *Anesth Analg* 2010 Feb 1;110(2):375-90.
<http://www.ncbi.nlm.nih.gov/pubmed/19955503>
- Furman EB, Roman DG, Lemmer LA, et al. Specific therapy in water, electrolyte and blood-volume replacement during pediatric surgery. *Anesthesiology* 1975 Feb;42(2):187-93.
<http://www.ncbi.nlm.nih.gov/pubmed/1115368>
- Berry F. Practical aspects of fluid and electrolyte therapy. In: Berry F, ed. *Anesthetic Management of Difficult and Routine Pediatric Patients*. New York: Churchill Livingstone, 1986: pp. 107-135.

13. Kearney R, Mack C, Entwistle L. Withholding oral fluids from children undergoing day surgery reduces vomiting. *Paediatr Anaesth* 1998;8(4):331-6.
<http://www.ncbi.nlm.nih.gov/pubmed/9672932>
14. Goodarzi M, Matar MM, Shafa M, et al. A prospective randomized blinded study of the effect of intravenous fluid therapy on postoperative nausea and vomiting in children undergoing strabismus surgery. *Pediatr Anesth* 2006 Jan;16(1):49-53.
<http://www.ncbi.nlm.nih.gov/pubmed/16409529>
15. Moritz ML, Ayus JC. Intravenous fluid management for the acutely ill child. *Curr Opin Pediatr* 2011 Apr;23(2):186-93.
<http://www.ncbi.nlm.nih.gov/pubmed/21415832>
16. Yung M, Keeley S. Randomised controlled trial of intravenous maintenance fluids. *J Paediatr Child Health* 2009 Jan-Feb;45(1-2):9-14.
<http://www.ncbi.nlm.nih.gov/pubmed/18036144>
17. Moritz ML, Ayus JC. Prevention of hospital-acquired hyponatremia: a case for using isotonic saline. *Pediatrics* 2003 Feb;111(2): 227-30.
<http://www.ncbi.nlm.nih.gov/pubmed/12563043>
18. Duke T, Molyneux EM. Intravenous fluids for seriously ill children: time to reconsider. *Lancet* 2003 Oct 18;362(9392):1320-3.
<http://www.ncbi.nlm.nih.gov/pubmed/14575980>
19. Holliday MA, Ray PE, Friedman AL. Fluid therapy for children: facts, fashions and questions. *Arch Dis Child* 2007 Jun;92(6):546-50.
<http://www.ncbi.nlm.nih.gov/pubmed/17175577>
20. Greenbaum L. The pathophysiology of body fluids and fluid therapy. In: Kliegman R, Behrman R, Jenson H, Stanton B, eds. *Kliegman: Nelson textbook of pediatrics*. 18th ed. Philadelphia, PA: Saunders Elsevier, 2007.
21. Messner AH, Barbita JA. Oral fluid intake following tonsillectomy. *Int J Pediatr Otorhinolaryngol* 1997 Feb 14;39(1):19-24.
<http://www.ncbi.nlm.nih.gov/pubmed/9051436>
22. Schreiner MS, Nicolson SC, Martin T, et al. Should children drink before discharge from day surgery? *Anesthesiology* 1992 Apr;76(4):528-33.
<http://www.ncbi.nlm.nih.gov/pubmed/1550277>
23. Radke OC, Biedler A, Kolodzie K, et al. The effect of postoperative fasting on vomiting in children and their assessment of pain. *Paediatr Anaesth* 2009 May;19(5):494-9.
<http://www.ncbi.nlm.nih.gov/pubmed/19453581>
24. Cheng W, Chow B, Tam PK. Electrogastrographic changes in children who undergo day-surgery anesthesia. *J Pediatr Surg* 1999 Sep;34(9):1336-8.
<http://www.ncbi.nlm.nih.gov/pubmed/10507424>
25. Mercan A, El-Kerdawy H, Bhavsar B, et al. The effect of timing and temperature of oral fluids ingested after minor surgery in preschool children on vomiting: a prospective, randomized, clinical study. *Paediatr Anaesth* 2011 Oct;21(10):1066-70.
<http://www.ncbi.nlm.nih.gov/pubmed/21668799>

21. POST-OPERATIVE PAIN MANAGEMENT IN CHILDREN: GENERAL INFORMATION

21.1 Introduction

The provision of adequate pain control requires proper pain evaluation, accurate choice of drug and route of administration, and consideration of age, physical condition and type of surgery and anaesthesia (1). However, there is still no standardised algorithm for management of post-operative pain in children (2). There is an urgent need for a post-operative pain management protocol in children, particularly for guidance on the frequency of pain assessment, use of parenteral opioids, introduction of regional anaesthesia, and the application of rescue analgesics (3).

Traditional medical beliefs that neonates are incapable of experiencing pain have now been abandoned following recent and better understanding of how the pain system matures in humans, better pain assessment methods and a knowledge of the clinical consequences of pain in neonates (4-8). Many studies have indicated that deficient or insufficient analgesia may be the cause of future behavioural and somatic

sequelae (9-13). Our current understanding of pain management in children depends fully on the belief that all children, irrespective of age, deserve adequate treatment.

21.2 Assessment of pain

Assessment of pain is the first step of pain management. Validated pain assessment tools are needed for this purpose and it is important to select the appropriate pain assessment technique. Several pain assessment tools have been developed according to the child's age, cultural background, mental status, communication skills and physiological reactions (14,15).

One of the most important topics in paediatric pain management is informing and involving the child and parents during this process. Parents and patients can manage post-operative pain at home or in hospital if provided with the correct information. Parents and patients, if they are old enough, can actively take part in pain management in patient-family-controlled analgesia applications (16-21).

21.3 Drugs and route of administration

Pre-emptive analgesia is an important concept that aims to induce the suppression of pain before neural hypersensitization occurs (22). Local anaesthetics or non-steroidal analgesics are given intra-operatively to delay post-operative pain and to decrease post-operative analgesic consumption. Analgesics must be titrated until an appropriate response is achieved. Opioids can be administered to children by the oral, mucosal, transdermal, subcutaneous, intramuscular or intravenous routes (18). The combination of opioids with non-steroidal anti-inflammatory drugs (NSAIDs) or local anaesthetics (balanced or multimodal analgesia) can be used to increase the quality of analgesia and decrease undesired effects related to opioids (23). The same combination of local anaesthetics, opioids, and non-opioid drugs used in adults can also be used in children taking into account their age, body weight and individual medical status.

The World Health Organization's 'pain ladder' is a useful tool for the pain management strategy (24). A three-level strategy seems practical for clinical use. Post-operative management should be based on sufficient intra-operative pre-emptive analgesia with regional or caudal blockade followed by balanced analgesia.

Paracetamol and NSAIDs are the drugs of choice at the first level. As they become insufficient to prevent pain, weak and strong opioids are added to oral drugs to achieve balanced analgesia. Every institute must build their own strategy for post-operative analgesia. A proposed strategy for post-operative analgesia may be as follows:

1. Intra-operative regional or caudal block
2. Paracetamol + NSAID
3. Paracetamol + NSAID + weak opioid (e.g. tramadol or codeine)
4. Paracetamol + NSAID + strong opioid (e.g. morphine, fentanyl, oxycodone or pethidine)

21.4 Circumcision

Circumcision without anaesthesia, irrespective of age, is not recommended. Circumcision requires proper pain management (28). Despite this, adequate pain management is still below expectation (29). Potential analgesic interventions during circumcision include the use of a dorsal penile nerve block (DPNB) or ring block, topical anaesthetics (e.g. lidocaine-prilocaine cream, or 4% liposomal lidocaine cream), a less painful clamp (e.g. Mogen clamp), a pacifier, sucrose, and swaddling, preferably in combination (30-35).

Although DPNB and topical anaesthetics seem to have a similar post-operative analgesic effect, DPNB is still the most preferred method (33) (LE: 1a). Ultrasonographic guidance may improve the results, with an increase in procedural time (36,37). Caudal blockade methods have similar efficacy compared to DPNB. However, parents should be informed about the more frequent incidence of post-operative motor weakness and micturition problems (38-43).

21.5 Penile, inguinal and scrotal surgery

Caudal block is the most studied method for analgesia following surgery for hypospadias. Several agents with different doses, concentrations and administration techniques have been used with similar outcomes (44-58). Both single and combined use of these agents is effective (46,48,53,54,56,57).

Penile blocks can be used for post-operative analgesia and have similar post-operative analgesic properties as caudal blocks (59). Two penile blocks at the beginning and end of surgery seems to provide better pain relief (60). Severe bladder spasms caused by the presence of the bladder catheter may sometimes cause more problems than pain and is managed with antimuscarinic medications.

For inguinoscrotal surgery, all anaesthetic methods, such as caudal blocks (61-65), nerve block (66,67), wound infiltration or instillation, and irrigation with local anaesthetics (68-70), have been shown to have adequate post-operative analgesic properties. Combinations may improve the results (71).

Table 19: List of several drugs used in post-operative pain management in children (5,13,19,25-27)

Name	Route of administration	Dose	Side effects	General remarks	Caution
Non-narcotics					
Acetaminophen	Rectal Oral Intravenous	40 mg/kg loading, 20 mg/kg/dose 4 times/day 15-40 mg/kg, followed by 30 mg/kg/8 h Propacetamol (prodrug)	Nephrotoxicity, hepatotoxicity (neonates)	Most common used analgesic Antipyretic effect Opioid-sparing effect Wide safety range	Slow onset time and variable absorption via the rectal route; dividing the vehicle is not recommended. Total dose should not exceed: 100 mg/kg for children; 75 mg/kg for infants; 60 mg/kg for term and preterm neonates > 32 weeks post-conceptual age; and 40 mg/kg for preterm neonates < 32 weeks post-conceptual age Safety not established for infants < 6 months old
Ibuprofen	Oral, rectal	4-10 mg/kg/dose 3-4 times/day		Better analgesic than paracetamol	
Diclofenac	Tablet, syrup, suppository	1-1.5 mg/kg 2-3 times/day	Nephrotoxicity, gastrointestinal disturbances	Better than ibuprofen	> 6 years old
Ketorolac	Oral, IV, IM	0.2-0.5 mg/kg every 6 h (48 h) Total dose < 2 mg/kg/day, maximum 5 days		Opioid-sparing effect	
Ketamine	Oral, rectal, IM, SC, IV, intraspinal	< 2 mg/kg (IM) < 1 mg/kg (IV, epidural)			
Metamizole, dipyrone	Oral, IM Oral drop	10-15 mg/kg/dose (max 40 mg/kg total) 10-15 mg/kg 1 drop/kg/dose, up to 4 times/day	Risk of agranulocytosis, not clarified definitely	Very effective antipyretic	Not approved in some countries including USA, Sweden, Japan and Australia
Narcotics					
Opioids			Nausea, vomiting, dyspepsia, constipation, urinary retention, respiratory depression, drowsiness, euphoria		
Tramadol (weak opioid)	Oral, rectal, IV, IM (dose can be repeated 4-6 times/day)	2-3 mg/kg/dose (oral, drop) 1-2 mg/kg/dose (oral, tablet) 1.5-3 mg/kg/dose (rectal) 0.75-2 mg/kg/dose (IM) 2-2.5 mg/kg/dose (IV) 0.1-0.25 mg/kg/h (continuous)	Nausea, vomiting, pruritus and rash	Does not inhibit prostaglandin synthesis	An IM injection is not recommended. Slow IV infusion. Be careful in patients taking psychoactive medications and with seizures

Codeine	Oral	1 mg/kg, single dose	Respiratory depression not seen after single dose	Both antitussive and analgesic effect	
Morphine	IM, IV	6-12 months: 0.1 mg/kg, IM 0.05 mg/kg, IV		Most commonly used opioid, but not the most suitable opioid for pain relief in children	IM injection not recommended < 2 months old: be careful
Nalbuphine	IV	< 3 months old: 0.05 mg/kg/dose > 3 months old: 0.05-0.10 mg/kg/dose (4-6 times/day)			
Piritramide	IV	0.05-0.10 mg/kg/dose (4-6 times/day)			
Dextromethorphan	Oral, syrup	1 mg/kg			
Pethidine/meperidine	IM, IV	1.5-2 mg/kg IM as premedicant 1 mg/kg IV as analgesic	No advantage over morphine		
Fentanyl	IV	1-2 µg/kg			
Buprenorphine	IV	3-5 mg/kg			
Pentazocine	IV, IM	1 mg/kg IM 0.5-0.75 mg/kg IV	In small infants, observe respiration after IV administration		
Regional (local) anaesthetics					
bupivacaine		Maximum single bolus dose: 2.5-3.0 mg/kg Maximum infusion: 0.4-0.5 mg/kg/h (10-20 mg/kg/day) in older infants and children; 0.2-0.25 mg/kg/h (5-6 mg/kg/day) in neonates	Cardiotoxicity, convulsion		
Levobupivacaine	IV, IM	0.2-0.25% 1-2.5 mg/kg for single-shot epidural 0.2-0.4 mg/kg/h for IV continuous administration	Less toxic than bupivacaine		
Ropivacaine	IV, IM	0.2-0.25% 1-2.5 mg/kg for single-shot epidural 0.2-0.4 mg/kg/h for IV continuous administration	Less toxic than levobupivacaine		

21.6 Bladder and kidney surgery

Continuous epidural infusion of local anaesthetics (72-74), as well as systemic (intravenous) application of analgesics (75), has been shown to be effective. Ketorolac is an effective agent that is underused. It decreases the frequency and severity of bladder spasms and the length of post-operative hospital stay and costs (76-81).

Open kidney surgery is particularly painful because all three muscle layers are cut during conventional loin incision. A dorsal lumbotomy incision may be a good alternative because of the shorter post-operative hospital stay and earlier return to oral intake and unrestricted daily activity (82).

Caudal blocks plus systemic analgesics (83), and continuous epidural analgesia, are effective in terms of decreased post-operative morphine requirement after renal surgery (84,85). However, when there is a relative contraindication to line insertion, a less experienced anaesthetist is available, or parents prefer it (86), non-invasive regimens composed of intra-operative and post-operative analgesics may be the choice. Particularly in this group of patients, stepwise analgesia protocols can be developed (87). For laparoscopic approaches, intraperitoneal spraying of local anaesthetic before incision of the perirenal fascia may be beneficial (88).

Table 20: A simple pain management strategy for paediatric urological surgery

Intensity of surgery	First step	Second step	Third step
Mild (inguinal, scrotal, penile)	Paracetamol and wound infiltration with local anaesthetics	NSAIDs	Regional block/weak opioid or intravenous strong opioid with small increments as rescue analgesia (nalbuphine, fentanyl, meperidine, morphine etc.)
Moderate (lower abdominal)			Peripheral nerve block (single shot or continuous infusion)/opioid injection (IV PCA)
Severe (upper abdominal or lombotomy)			Epidural local/major peripheral nerve/plexus block/opioid injection (IV PCA)

IV PCA = intravenous patient-controlled analgesia.

21.7 Conclusions and recommendations

Conclusions	LE
Neonates experience pain.	3
Pain may cause behavioural and somatic sequelae.	3
Every institute must develop their own well-structured strategy for post-operative analgesia.	4

Recommendations	GR
Pain must be prevented/treated in children of all ages.	B
Pain must be evaluated by age-compatible assessment tools.	B
Patients and parents must be informed accurately.	B
Pre-emptive analgesia is important and balanced analgesia should be used in order to decrease the side effects of opioids.	B

21.8 References

- Ivani G, Tonetti F. Postoperative analgesia in infants and children: new developments. *Minerva Anesthesiol* 2004 May;70(5):399-403.
<http://www.ncbi.nlm.nih.gov/pubmed/15181422>
- Karling M, Renström M, Ljungman G. Acute and postoperative pain in children: a Swedish nationwide survey. *Acta Paediatr* 2002;91(6):660-6.
<http://www.ncbi.nlm.nih.gov/pubmed/12162598>
- Stamer UM, Mpasios N, Maier C, et al. Postoperative analgesia in children--current practice in Germany. *Eur J Pain* 2005 Oct;9(5):555-60.
<http://www.ncbi.nlm.nih.gov/pubmed/16139184>
- Taylor BJ, Robbins JM, Gold JI, et al. Assessing postoperative pain in neonates: a multicentre observational study. *Pediatrics* 2006 Oct;118(4):e992-1000.
<http://www.ncbi.nlm.nih.gov/pubmed/17015519>

5. Everett LL. Pain management for pediatric ambulatory anesthesia. *Curr Opin Anaesthesiol* 2002 Dec;15(6):609-13.
<http://www.ncbi.nlm.nih.gov/pubmed/17019260>
6. Simons SHP, van Dijk M, Anand KJS, et al. Do we still hurt newborn babies? A prospective study of procedural pain and analgesia in neonates. *Arch Pediatr Adolesc Med* 2003 Nov;157(11):1058-64.
<http://www.ncbi.nlm.nih.gov/pubmed/14609893>
7. American Academy of Pediatrics; Canadian Paediatric Society. Prevention and management of pain and stress in the neonate. *Pediatrics* 2000 Feb;105(2):454-61.
<http://www.ncbi.nlm.nih.gov/pubmed/10654977>
8. Anand KJS; International Evidence-Based Group for Neonatal Pain. Consensus statement for the prevention and management of pain in the newborn. *Arch Pediatr Adolesc Med* 2001 Feb;155(2):173-80.
<http://www.ncbi.nlm.nih.gov/pubmed/11177093>
9. Taddio A, Katz J, Ilersich AL, et al. Effect of neonatal circumcision on pain response during subsequent routine vaccination. *Lancet* 1997 Mar 1;349(9052):599-603.
<http://www.ncbi.nlm.nih.gov/pubmed/9057731>
10. Grunau RE, Oberlander TF, Whitfield MF, et al. Demographic and therapeutic determinants of pain reactivity in very low birth weight neonates at 32 weeks' postconceptional age. *Pediatrics* 2001 Jan;107(1):105-12.
<http://www.ncbi.nlm.nih.gov/pubmed/11134442>
11. Peters JW, Schouw R, Anand KJ, et al. Does neonatal surgery lead to increased pain sensitivity in later childhood? *Pain* 2005 Apr;114(3):444-54.
<http://www.ncbi.nlm.nih.gov/pubmed/15777869>
12. Kain ZN, Mayes LC, Caldwell-Andrews AA, et al. Preoperative anxiety, postoperative pain, and behavioral recovery in young children undergoing surgery. *Pediatrics* 2006 Aug;118(2):651-8.
<http://www.ncbi.nlm.nih.gov/pubmed/16882820>
13. Bozkurt P. The analgesic efficacy and neuroendocrine response in paediatric patients treated with two analgesic techniques: using morphine-epidural and patient-controlled analgesia. *Paed Anaesth* 2002 Mar;12(3):248-54.
<http://www.ncbi.nlm.nih.gov/pubmed/11903939>
14. Young KD. Pediatric procedural pain. *Ann Emerg Med* 2005 Feb;45(2):160-71.
<http://www.ncbi.nlm.nih.gov/pubmed/15671974>
15. Ghai B, Makkar JK, Wig J. Postoperative pain assessment in preverbal children and children with cognitive impairment. *Paediatr Anaesth* 2008 Jun;18(6):462-77.
<http://www.ncbi.nlm.nih.gov/pubmed/18363630>
16. Kankkunen P, Pietilä AM, Vehviläinen-Julkunen K. Families' and children's postoperative pain--literature review. *J Pediatr Nurs* 2004 Apr;19(2):133-9.
<http://www.ncbi.nlm.nih.gov/pubmed/15077212>
17. Jonas DA. Parent's management of their child's pain in the home following day surgery. *J Child Health Care* 2003 Sep;7(3):150-62.
<http://www.ncbi.nlm.nih.gov/pubmed/14516009>
18. Schechter WP, Farmer D, Horn JK, et al. Special considerations in perioperative pain management: audiovisual distraction, geriatrics, pediatrics, and pregnancy. *J Am Coll Surg* 2005 Oct;201(4):612-8.
<http://www.ncbi.nlm.nih.gov/pubmed/16183502>
19. Gehdoo RP. Postoperative pain management in pediatric patients. *Indian J. Anesth* 2004 48(5):406-14.
<http://medind.nic.in/iadt/t04/i5/iadt04i5p406.pdf>
20. Ellis JA, Martelli B, LaMontagne C, et al. Evaluation of a continuous epidural analgesia program for postoperative pain in children. *Pain Manag Nurs* 2007 Dec;8(4):146-55.
<http://www.ncbi.nlm.nih.gov/pubmed/18036502>
21. Birmingham PK, Wheeler M, Suresh S, et al. Patient-controlled epidural analgesia in children: can they do it? *Anesth Analg* 2003 Mar;96(3):686-91.
<http://www.ncbi.nlm.nih.gov/pubmed/12598244>
22. Woolf CJ, Chong MS. Preemptive analgesia-treating postoperative pain by preventing the establishment of central sensitization. *Anesth Analg* 1993 Aug;77(2):362-79.
<http://www.ncbi.nlm.nih.gov/pubmed/8346839>
23. Kehlet H, Dahl JB. The value of "multimodal" or "balanced analgesia" in postoperative pain treatment. *Anesth Analg* 1993 Nov;77(5):1048-56.
<http://www.ncbi.nlm.nih.gov/pubmed/8105724>

24. World Health Organisation. Cancer Pain Relief and Palliative Care in Children. Geneva: World Health Organization, 1998.
<http://apps.who.int/bookorders/anglais/detart1.jsp?sesslan=1&codlan=1&codcol=15&codcch=459>
25. Arana A, Morton NS, Hansen TG. Treatment with paracetamol in infants. *Acta Anaesthesiol Scand* 2001 Jan;45(1):20-9.
<http://www.ncbi.nlm.nih.gov/pubmed/11152028>
26. Messerer B, Gutmann A, Weinberg A, et al. Implementation of a standardized pain management in a pediatric surgery unit. *Pediatr Surg Int* 2010 Sep;26(9):879-89.
<http://www.ncbi.nlm.nih.gov/pubmed/20625751>
27. Vergheze ST, Hannallah RS. Acute pain management in children. *J Pain Res* 2010 Jul 15;3:105-23.
<http://www.ncbi.nlm.nih.gov/pubmed/21197314>
28. Anand KJ, Johnston CC, Oberlander TF, et al. Analgesia and local anesthesia during invasive procedures in the neonate. *Clin Ther* 2005 Jun;27(6):844-76.
<http://www.ncbi.nlm.nih.gov/pubmed/16117989>
29. Yawman D, Howard CR, Auinger P, et al. Pain relief for neonatal circumcision: a follow-up of residency training practices. *Ambul Pediatr* 2006 Jul-Aug;6(4):210-4.
<http://www.ncbi.nlm.nih.gov/pubmed/16843252>
30. Taddio A, Ohlsson A, Einarson TR, et al. A systematic review of lidocaine-prilocaine cream (EMLA) in the treatment of acute pain in neonates. *Pediatrics* 1998 Feb;101(2):E1.
<http://www.ncbi.nlm.nih.gov/pubmed/9445511>
31. Smith DP, Gjellum M. The efficacy of LMX versus EMLA for pain relief in boys undergoing office meatotomy. *J Urol* 2004 Oct;172(4 Pt 2):1760-1.
<http://www.ncbi.nlm.nih.gov/pubmed/15371808>
32. Choi WY, Irwin MG, Hui TW, et al. EMLA cream versus dorsal penile nerve block for postcircumcision analgesia in children. *Anesth Analg* 2003 Feb;96(2):396-9.
<http://www.ncbi.nlm.nih.gov/pubmed/12538184>
33. Brady-Fryer B, Wiebe N, Lander JA. Pain relief for neonatal circumcision. *Cochrane Database Syst Rev.* 2004 Oct 18;(4):CD004217.
<http://www.ncbi.nlm.nih.gov/pubmed/15495086>
34. Lehr VT, Cepeda E, Frattarelli DA, et al. Lidocaine 4% cream compared with lidocaine 2.5% and prilocaine 2.5% or dorsal penile block for circumcision. *Am J Perinatol* 2005 Jul;22(5):231-7.
<http://www.ncbi.nlm.nih.gov/pubmed/16041631>
35. Matsota P, Papageorgiou-Brousta M. Intraoperative and postoperative analgesia with subcutaneous ring block of the penis with levobupivacaine for circumcision in children. *Eur J Pediatr Surg* 2004 Jun;14(3):198-202.
<http://www.ncbi.nlm.nih.gov/pubmed/15211412>
36. Faraoni D, Gilbeau A, Lingier P, et al. Does ultrasound guidance improve the efficacy of dorsal penile nerve block in children? *Paediatr Anaesth* 2010 Oct;20(10):931-6.
<http://www.ncbi.nlm.nih.gov/pubmed/20849498>
37. Sandeman DJ, Reiner D, Dilley AV, et al. A retrospective audit of three different regional anaesthetic techniques for circumcision in children. *Anaesth Intensive Care* 2010 May;38(3):519-24.
<http://www.ncbi.nlm.nih.gov/pubmed/20514962>
38. Beyaz SG. Comparison of Postoperative Analgesic Efficacy of Caudal Block versus Dorsal Penile Nerve Block with Levobupivacaine for Circumcision in Children. *Korean J Pain* 2011 Mar;24(1):31-5.
<http://www.ncbi.nlm.nih.gov/pubmed/21390176>
39. Sharpe P, Klein JR, Thompson JP, et al. Analgesia for circumcision in a paediatric population: comparison of caudal bupivacaine alone with bupivacaine plus two doses of clonidine. *Paediatr Anaesth* 2001 Nov;11(6):695-700.
<http://www.ncbi.nlm.nih.gov/pubmed/11696146>
40. Gauntlett I. A comparison between local anaesthetic dorsal nerve block and caudal bupivacaine with ketamine for paediatric circumcision. *Paediatr Anaesth* 2003 Jan;13(1):38-42.
<http://www.ncbi.nlm.nih.gov/pubmed/12535037>
41. Weksler N, Atias I, Klein M, et al. Is penile block better than caudal epidural block for postcircumcision analgesia? *J Anesth* 2005;19(1):36-9.
<http://www.ncbi.nlm.nih.gov/pubmed/15674514>
42. Margetts L, Carr A, McFadyen G, et al. A comparison of caudal bupivacaine and ketamine with penile block for paediatric circumcision. *Eur J Anaesthesiol* 2008 Dec;25(12):1009-13.
<http://www.ncbi.nlm.nih.gov/pubmed/18652709>

43. Cyna AM, Middleton P. Caudal epidural block versus other methods of postoperative pain relief for circumcision in boys. *Cochrane Database Syst Rev* 2008 Oct 8;(4):CD003005.
<http://www.ncbi.nlm.nih.gov/pubmed/18843636>
44. Abdulatif M, El-Sanabary M. Caudal neostigmine, bupivacaine, and their combination for postoperative pain management after hypospadias surgery in children. *Anesth Analg* 2002 Nov;95(5):1215-8.
<http://www.ncbi.nlm.nih.gov/pubmed/12401596>
45. Samuel M, Hampson-Evans D, Cunningham P. Prospective to a randomized double-blind controlled trial to assess efficacy of double caudal analgesia in hypospadias repair. *J Pediatr Surg* 2002 Feb;37(2):168-74.
<http://www.ncbi.nlm.nih.gov/pubmed/11819193>
46. Ozyuvaci E, Altan A, Yucel M, et al. Evaluation of adding preoperative or postoperative rectal paracetamol to caudal bupivacaine for postoperative analgesia in children. *Paediatr Anaesth* 2004 Aug;14(8):661-5.
<http://www.ncbi.nlm.nih.gov/pubmed/15283825>
47. Bhardwaj N, Yaddanapudi S, Ghai B, et al. Neostigmine does not prolong the duration of analgesia produced by caudal bupivacaine in children undergoing urethroplasty. *J Postgrad Med* 2007 Jul-Sep;53(3):161-5.
<http://www.ncbi.nlm.nih.gov/pubmed/17699988>
48. Ozbek H, Bilen A, Ozcengiz D, et al. The comparison of caudal ketamine, alfentanil and ketamine plus alfentanil administration for postoperative analgesia in children. *Paediatr Anaesth* 2002 Sep;12(7):610-6.
<http://www.ncbi.nlm.nih.gov/pubmed/12358657>
49. De Negri P, Ivani G, Tirri T, et al. A comparison of epidural bupivacaine, levobupivacaine, and ropivacaine on postoperative analgesia and motor blockade. *Anesth Analg* 2004 Jul;99(1):45-8.
<http://www.ncbi.nlm.nih.gov/pubmed/15281501>
50. Thies KC, Driessen J, Gwan Kho H, et al. Longer than expected-duration of caudal analgesia with two different doses of levobupivacaine in children undergoing hypospadias repair. *J Pediatr Urol* 2010 Dec;6(6):585-8.
<http://www.ncbi.nlm.nih.gov/pubmed/20171143>
51. Hansen TG, Henneberg SW, Walther-Larsen S, et al. Caudal bupivacaine supplemented with caudal or intravenous clonidine in children undergoing hypospadias repair: a double-blind study. *Br J Anaesth* 2004 Feb;92(2):223-7.
<http://www.ncbi.nlm.nih.gov/pubmed/14722172>
52. Günes Y, Gündüz M, Unlügenç H, et al. Comparison of caudal vs intravenous tramadol administered either preoperatively or postoperatively for pain relief in boys. *Paediatr Anaesth* 2004 Apr;14(4):324-8.
<http://www.ncbi.nlm.nih.gov/pubmed/15078378>
53. Laiq N, Khan MN, Tahmeedullah, et al. Comparison of caudal bupivacaine and bupivacaine-tramadol for postoperative analgesia in children undergoing hypospadias surgery. *J Coll Physicians Surg Pak* 2009 Nov;19(11):678-81.
<http://www.ncbi.nlm.nih.gov/pubmed/19889260>
54. Apiliogullari S, Duman A, Gok F, et al. Efficacy of a low-dose spinal morphine with bupivacaine for postoperative analgesia in children undergoing hypospadias repair. *Paediatr Anaesth* 2009 Nov;19(11):1078-83.
<http://www.ncbi.nlm.nih.gov/pubmed/19708911>
55. Silvani P, Camporesi A, Agostino MR, et al. Caudal anesthesia in pediatrics: an update. *Minerva Anesthesiol* 2006 Jun;72(6):453-9.
<http://www.ncbi.nlm.nih.gov/pubmed/16682915>
56. Gunduz M, Ozalevli M, Ozbek H, et al. Comparison of caudal ketamine with lidocaine or tramadol administration for postoperative analgesia of hypospadias surgery in children. *Paediatr Anaesth* 2006 Feb;16(2):158-63.
<http://www.ncbi.nlm.nih.gov/pubmed/16430412>
57. Cho JE, Kim JY, Hong JY, et al. The addition of fentanyl to 1.5 mg/ml ropivacaine has no advantage for paediatric epidural analgesia. *Acta Anaesthesiol Scand* 2009 Sep;53(8):1084-7.
<http://www.ncbi.nlm.nih.gov/pubmed/19572930>
58. Al-Zaben KR, Qudaisat IY, Al-Ghanem SM, et al. Intraoperative administration of dexmedetomidine reduces the analgesic requirements for children undergoing hypospadias surgery. *Eur J Anaesthesiol* 2010 Mar;27(3):247-52.
<http://www.ncbi.nlm.nih.gov/pubmed/19952754>

59. Metzelder ML, Kuebler JF, Glueer S, et al. Penile block is associated with less urinary retention than caudal anesthesia in distal hypospadias repair in children. *World J Urol* 2010 Feb;28(1):87-91.
<http://www.ncbi.nlm.nih.gov/pubmed/19466428>
60. Chhibber AK, Perkins FM, Rabinowitz R, et al. Penile block timing for postoperative analgesia of hypospadias repair in children. *J Urol* 1997 Sep;158(3 Pt 2):1156-9.
<http://www.ncbi.nlm.nih.gov/pubmed/9258161>
61. Conroy JM, Othersen HB Jr, Dorman BH, et al. A comparison of wound instillation and caudal block for analgesia following pediatric inguinal herniorrhaphy. *J Pediatr Surg* 1993 Apr;28(4):565-7.
<http://www.ncbi.nlm.nih.gov/pubmed/8483071>
62. Breschan C, Jost R, Krumpolz R, et al. A prospective study comparing the analgesic efficacy of levobupivacaine, ropivacaine and bupivacaine in pediatric patients undergoing caudal blockade. *Paediatr Anaesth* 2005 Apr;15(4):301-6.
<http://www.ncbi.nlm.nih.gov/pubmed/15787921>
63. Taheri R, Shayeghi S, Razavi SS, et al. Efficacy of bupivacaine-neostigmine and bupivacaine-tramadol in caudal block in pediatric inguinal herniorrhaphy. *Paediatr Anaesth* 2010 Sep;20(9):866-72.
<http://www.ncbi.nlm.nih.gov/pubmed/20716080>
64. Akin A, Ocalan S, Esmoğlu A, et al. The effects of caudal or intravenous clonidine on postoperative analgesia produced by caudal levobupivacaine in children. *Paediatr Anaesth* 2010 Apr;20(4):350-5.
<http://www.ncbi.nlm.nih.gov/pubmed/20158620>
65. Hong JY, Han SW, Kim WO, et al. Effect of dexamethasone in combination with caudal analgesia on postoperative pain control in day-case paediatric orchiopey. *Br J Anaesth* 2010 Oct;105(4):506-10.
<http://www.ncbi.nlm.nih.gov/pubmed/20659915>
66. Jagannathan N, Sohn L, Sawardekar A, et al. Unilateral groin surgery in children: will the addition of an ultrasound-guided ilioinguinal nerve block enhance the duration of analgesia of a single-shot caudal block? *Paediatr Anaesth* 2009 Sep;19(9):892-8.
<http://www.ncbi.nlm.nih.gov/pubmed/19627532>
67. Fredrickson MJ, Paine C, Hamill J. Improved analgesia with the ilioinguinal block compared to the transversus abdominis plane block after pediatric inguinal surgery: a prospective randomized trial. *Paediatr Anaesth* 2010 Nov;20(11):1022-7.
<http://www.ncbi.nlm.nih.gov/pubmed/20964768>
68. Shenfeld O, Eldar I, Lotan G, et al. Intraoperative irrigation with bupivacaine for analgesia after orchiopey and herniorrhaphy in children. *J Urol* 1995 Jan;153(1):185-7.
<http://www.ncbi.nlm.nih.gov/pubmed/7966769>
69. Machotta A, Risse A, Bercker S, et al. Comparison between instillation of bupivacaine versus caudal analgesia for postoperative analgesia following inguinal herniotomy in children. *Paediatr Anaesth* 2003 Jun;13(5):397-402.
<http://www.ncbi.nlm.nih.gov/pubmed/12791112>
70. Demiraran Y, Ilce Z, Kocaman B, et al. Does tramadol wound infiltration offer an advantage over bupivacaine for postoperative analgesia in children following herniotomy? *Paediatr Anaesth* 2006 Oct;16(10):1047-50.
<http://www.ncbi.nlm.nih.gov/pubmed/16972834>
71. Saeed A, Khan AR, Lee V, et al. Pain management for unilateral orchidopexy in children: an effective regimen. *World J Surg* 2009 Mar;33(3):603-6.
<http://www.ncbi.nlm.nih.gov/pubmed/19115030>
72. Cain MP, Husmann DA, McLaren RH, et al. Continuous epidural anesthesia after ureteroneocystostomy in children. *J Urol* 1995 Aug;154(2 Pt 2):791-3.
<http://www.ncbi.nlm.nih.gov/pubmed/7609181>
73. Merguerian PA, Sutters KA, Tang E, et al. Efficacy of continuous epidural analgesia versus single dose caudal analgesia in children after intravesical ureteroneocystostomy. *J Urol* 2004 Oct;172(4 Pt 2):1621-5.
<http://www.ncbi.nlm.nih.gov/pubmed/15371775>
74. Tripi PA, Palmer JS, Thomas S, et al. Clonidine increases duration of bupivacaine caudal analgesia for ureteroneocystostomy: a double-blind prospective trial. *J Urol* 2005 Sep;174(3):1081-3.
<http://www.ncbi.nlm.nih.gov/pubmed/16094063>
75. Hong JY, Kim WO, Koo BN, et al. Fentanyl-sparing effect of acetaminophen as a mixture of fentanyl in intravenous parent-/nurse-controlled analgesia after pediatric ureteroneocystostomy. *Anesthesiology* 2010 Sep;113(3):672-7.
<http://www.ncbi.nlm.nih.gov/pubmed/20693884>

76. Gonzalez A, Smith DP. Minimizing hospital length of stay in children undergoing ureteroneocystostomy. *Urology* 1998 Sep;52(3):501-4.
<http://www.ncbi.nlm.nih.gov/pubmed/9730469>
77. Chauhan RD, Idom CB, Noe HN. Safety of ketorolac in the pediatric population after ureteroneocystostomy. *J Urol* 2001 Nov;166(5):1873-5.
<http://www.ncbi.nlm.nih.gov/pubmed/11586252>
78. Miller OF, Bloom TL, Smith LJ, et al. Early hospital discharge for intravesical ureteroneocystostomy. *J Urol* 2002 Jun;167(6):2556-9.
<http://www.ncbi.nlm.nih.gov/pubmed/11992088>
79. Park JM, Houck CS, Sethna NF, et al. Ketorolac suppresses postoperative bladder spasms after pediatric ureteral reimplantation. *Anesth Analg* 2000 Jul;91(1):11-5.
<http://www.ncbi.nlm.nih.gov/pubmed/10866879>
80. Jo YY, Hong JY, Choi EK, et al. Ketorolac or fentanyl continuous infusion for post-operative analgesia in children undergoing ureteroneocystostomy. *Acta Anaesthesiol Scand* 2011 Jan;55(1):54-9.
<http://www.ncbi.nlm.nih.gov/pubmed/21083540>
81. Routh JC, Graham DA, Nelson CP. Ketorolac is underutilized after ureteral reimplantation despite reduced hospital cost and reduced length of stay. *Urology* 2010 Jul;76(1):9-13.
<http://www.ncbi.nlm.nih.gov/pubmed/20138342>
82. Kumar R, Smith G. Dorsal lumbotomy incision for pediatric pyeloplasty--a good alternative. *Pediatr Surg Int* 1999;15(8):562-4.
<http://www.ncbi.nlm.nih.gov/pubmed/10631734>
83. Piedrahita YK, Palmer JS. Is one-day hospitalization after open pyeloplasty possible and safe? *Urology* 2006 Jan;67(1):181-4.
<http://www.ncbi.nlm.nih.gov/pubmed/16413360>
84. Lönnqvist PA, Olsson GL. Paravertebral vs epidural block in children. Effects on postoperative morphine requirement after renal surgery. *Acta Anaesthesiol Scand* 1994 May;38(4):346-9.
<http://www.ncbi.nlm.nih.gov/pubmed/8067221>
85. Berta E, Spanhel J, Smakal O, et al. Single injection paravertebral block for renal surgery in children. *Paediatr Anaesth* 2008 Jul;18(7):593-7.
<http://www.ncbi.nlm.nih.gov/pubmed/18482238>
86. Ben-Meir D, Livne PM, Katz J, et al. Continuous epidural versus nonepidural analgesia for postpyeloplasty pain in children. *J Urol* 2009 Oct;182(4 Suppl):1841-4.
<http://www.ncbi.nlm.nih.gov/pubmed/19692062>
87. Dingemann J, Kuebler JF, Wolters M, et al. Perioperative analgesia strategies in fast-track pediatric surgery of the kidney and renal pelvis: lessons learned. *World J Urol* 2010 Apr;28(2):215-9.
<http://www.ncbi.nlm.nih.gov/pubmed/19565247>
88. Freilich DA, Houck CS, Meier PM, et al. The effectiveness of aerosolized intraperitoneal bupivacaine in reducing postoperative pain in children undergoing robotic-assisted laparoscopic pyeloplasty. *J Pediatr Urol* 2008 Oct;4(5):337-40.
<http://www.ncbi.nlm.nih.gov/pubmed/18790415>

22. ABBREVIATIONS USED IN THE TEXT

This list is not comprehensive for the most common abbreviations

AGS	adrenogenital syndrome
ACTH	adrenocorticotrophic hormone
AMH	anti-Müllerian hormone
ARM	anorectal malformation
CAH	congenital adrenal hyperplasia
CIC	clean self-intermittent catheterisation
CNS	central nervous system
COPUM	congenital obstructive posterior urethral membrane
CRP	C-reactive protein
CT	computed tomography
DDAVP	desmopressin
DHTST	dihydrotestosterone
DMSA	dimercaptosuccinic acid
EMG	electromyography
ESR	erythrocyte sedimentation rate
FSH	follicle stimulating hormone
GnRH	gonadotrophin-releasing hormone
hCG	human chorionic gonadotrophin
IC	intermittent catheterisation
ICCS	International Children's Continence Society
IVU	intravenous urogram
LH	luteinizing hormone
LHRH	luteinizing hormone releasing hormone
LUTD	lower urinary tract dysfunction
LUT(S)	lower urinary tract (symptoms)
MRI	magnetic resonance imaging
NDS	neurogenic detrusor-sphincter dysfunction
OAB	overactive bladder
PNL	percutaneous litholapaxy
RCT	randomised controlled trial
RN	reflux nephropathy
RNC	radionuclide cystography
RTA	renal tubular acidosis
SWL	(extracorporeal) shockwave lithotripsy
Tc-MAG3 (99m)	technetium-99m mercaptoacetyltriglycine (MAG3)
TIP	tubularised incised plate urethroplasty
TST	testosterone
UPJ	ureteropelvic junction
URS	ureterorenoscopy
US	ultrasound
UTIs	urinary tract infections
VCUG	voiding cystourethrography
VR	vesicorenal reflux
VUR	vesicoureteral reflux
VUS	voiding urosonography

Conflict of interest

All members of the Paediatric Urology Guidelines working panel have provided disclosure statements on all relationships that they have that might be perceived to be a potential source of a conflict of interest. This information is publically accessible through the European Association of Urology website. This guidelines document was developed with the financial support of the European Association of Urology. No external sources of funding and support have been involved. The EAU is a non-profit organisation, and funding is limited to administrative assistance and travel and meeting expenses. No honoraria or other reimbursements have been provided.