

## MANAGEMENT OF ENCRUSTED URETERAL STENTS IMPACTED IN UPPER TRACT

MATTHEW F. BULTITUDE, RICHARD C. TIPTAFT, JONATHAN M. GLASS, AND PROKAR DASGUPTA

### ABSTRACT

**Objectives.** To present our series of patients with ureteral stent encrustation and give indwelling times and management. Encrustation is one of the most serious complications of ureteral stents.

**Methods.** A retrospective review was undertaken of all encrusted stents during a 4-year period. The inclusion criterion was a stent that required some form of intervention above the ureteral orifice to remove it. Combinations of extracorporeal shock wave lithotripsy, ureteroscopy, percutaneous nephrolithotomy, and open surgery were used to achieve stent removal.

**Results.** Forty-nine impacted encrusted stents were treated in 41 patients. Of these, 75.5% had become encrusted within 6 months and 42.8% within 4 months. The mean indwelling time was 5.6 months. Forty-seven stents were removed by endourologic techniques, with 4 requiring extracorporeal shock wave lithotripsy alone, 28 ureteroscopy, and 10 a combination of both. Five patients underwent successful percutaneous nephrolithotomy. One patient underwent open surgery, and in one removal failed. The mean number of procedures per patient was 1.94.

**Conclusions.** Stent encrustation can pose a serious challenge to the endourologist, and indwelling times should be minimized to avoid problems. Patients often require multiple treatments and a combination of extracorporeal shock wave lithotripsy and ureteroscopy offers highly successful outcomes and often avoids the need for more invasive techniques. UROLOGY 62: 622–626, 2003. © 2003 Elsevier Inc.

In 1967, Zimskind *et al.*<sup>1</sup> reported on 13 cases in which silicone ureteral splints were inserted cystoscopically to relieve ureteral obstruction. At the time, they reported 2 cases of encrustation. These stents are now commonplace in all aspects of urology, either to relieve intrinsic or extrinsic obstruction or to protect the ureter postoperatively. Stent design has developed enormously, with the now familiar J hook at either end,<sup>2</sup> and modern stents usually have a hydrophilic coating that aids in their ease of use. The development of softer materials and tailed stents<sup>3</sup> has improved patient tolerance; however, they are still associated with considerable morbidity. Common side effects include dysuria, loin pain, hematuria, and urinary frequency and urgency. Bacteruria is frequent, and patients often require courses of antibiotics. More serious complications are stent migration, fragmentation, and

encrustation. These are well described and can lead to increased morbidity, renal impairment,<sup>4</sup> and repeated procedures for removal. Current published data regarding stent encrustation tend to focus on only a handful of severe cases.<sup>4–10</sup> Although heavily encrusted stents clearly do pose significant problems, minor encrustations can also challenge the endourologist, particularly if occurring frequently and repetitively. We present our experience of patients with impacted ureteral stents. The indwelling time is reported, management discussed, and an algorithm proposed.

### MATERIAL AND METHODS

It was believed that a significant number of impacted stents were being treated in our endourology unit, which receives more than 800 tertiary referrals with renal calculi annually. A retrospective review was undertaken of impacted stents treated since January 1999. Ethical approval was not required. The definition for inclusion was any stent that could not be removed without some form of intervention to the stent above the level of the ureteral orifice. Stents requiring intervention only for encrustations on the lower part below the ureteral orifice were excluded from the analysis. Despite preoperative imaging, a proportion of impacted stents were only identified at the time of surgery, and this influenced the choice of treat-

From the Department of Urology, Guy's and St. Thomas' Hospital, London, United Kingdom

Reprint requests: Matthew F. Bultitude, M.D., Department of Urology, Guy's and St. Thomas' Hospital, St. Thomas Street, London SE1 9RT, United Kingdom

Submitted: February 19, 2003, accepted (with revisions): May 7, 2003

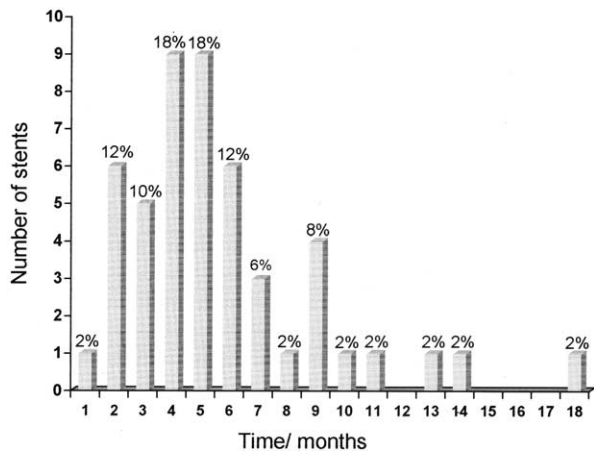


FIGURE 1. Number of stents versus time to stent encrustation (percentages included as data labels to nearest whole number). GA = general anesthetic.

ment. The endourologic techniques used for removal were extracorporeal shock wave lithotripsy (ESWL) using the Storz Modulith SL20 or SLX, rigid or flexible ureteroscopy (URS), and percutaneous nephrolithotomy (PCNL). Electrohydraulic lithotripsy, lithoclasty, and the holmium laser were used as appropriate to dislodge the encrustation, with the latter available since January 2001.

## RESULTS

Between January 1999 and December 2002, 49 impacted encrusted stents were treated in 41 patients in our endourology unit. Five patients had more than one encrusted stent treated. Of the 41 patients, 28 (68%) were men, and the mean age was 48.1 years (range 19 to 80). Of the 41 patients, 34 were tertiary referrals, of which 9 were referred for additional treatment of already encrusted stents. Stent removal in these patients had failed at their parent hospitals. The reasons for stent insertion were stone disease in 34 (82.9%); relief of obstruction (from endometriosis, benign uterine enlargement, lymphoma [2 patients], and retroperitoneal fibrosis) in 5 (12.1%); after balloon dilation of ureteropelvic junction obstruction in 1 (2.4%); and after pyeloplasty in 1 (2.4%). Of the 49 stents, 24 were inserted at our institution; the rest had been inserted at the referring hospital. Stents inserted in our department were hydrogel-coated Percuflex (Microvasive, Boston Scientific) double-J or tailed stents. Nineteen patients were documented as requiring treatment at the lower end of the stent as well as at the top.

Thirty-seven stents (75.5%) had become encrusted within 6 months, and the mean time from stent insertion to encrustation for the whole series was 5.6 months (range 1 to 18). Twenty-one of the stents (42.8%) had become encrusted within 4 months (Fig. 1). The mean indwelling time for the 7 patients without stone formation but with stent

TABLE I. Successful multimodal treatments used

Treatment Modality	Stents (n)	Mean Procedures (n)
ESWL alone	4 (8.3)	2.5
ESWL + URS	10 (20.8)	3.5
URS alone (flexible/rigid)	28 (58.3)	1.2
PCNL (primary)	2 (4.2)	1
PCNL (secondary)	3 (6.2)	3.7
Open stent removal	1 (2.1)	7

KEY: ESWL = extracorporeal shock wave lithotripsy; URS = ureteroscopy; PCNL = percutaneous nephrolithotomy.  
Numbers in parentheses are percentages.

encrustation was 5.4 months (range 2 to 11). The mean time for encrustation for the hydrogel-coated Percuflex stents (Microvasive, Boston Scientific) was 4.9 months. This slightly lower figure may be attributable to the more aggressive stone disease that we see at our center. Thirteen stents had been in place for longer than 6 months; four were delayed at the referring hospital because of late recall for stent change; four because of poor patient compliance; one because of morbid obesity with concomitant medical problems; one because of urgent contralateral treatment; one because the patient was lost to follow-up; and two because of delay after ESWL (both at 7 months).

Overall, 47 of the 49 stents were successfully removed by endourologic techniques. A multimodal approach to treatment was used (Table I). Fourteen patients were treated with ESWL, of whom 10 also required ureteroscopic intervention. Twenty-eight stents were successfully removed with ureteroscopy alone. Five patients underwent PCNL, of which two were primary procedures. The mean number of procedures required per patient (including each session of ESWL) was 1.94 (range 1 to 6). However, of the 38 ureteroscopic removals, 27 (71.1%) were achieved in one procedure. Two stents could not be removed by endoscopic techniques. One patient with non-Hodgkin's lymphoma developed radiolucent uric acid encrustation after chemotherapy. This could not be removed ureteroscopically. The stent was fragmented and impacted at the level of the vessels in the ureter. He underwent open removal with a surgical approach as one would perform ureterolithotomy. One stent in this series could not be removed. This was in an elderly lady who had had long-term stenting for ureteral obstruction from benign uterine enlargement. She had undergone six failed ESWL and ureteroscopic procedures and was deemed unfit for further intervention. A decision was made after discussion with the patient to leave the stent in situ and monitor renal function.

Stone analysis was only available for 20 of the 34 stone formers. Most stones were either calcium oxalate or phosphate, but 2 patients had cystine and 1 uric acid encrustation. These pose special problems with management, because the encrustation is usually radiolucent and thus only diagnosed at the time of surgery. The stone is usually hard and difficult to break, and patients are at risk of early repeated encrustation. Medical management is vital. Both cystinuric patients in this series had their stents removed with one ureteroscopic procedure.

Five patients had recurrent encrusted stents despite reducing indwelling times during the course of their treatment, and these were included in this analysis. Most stone formers in this series subsequently required additional endoscopic interventions for their stone disease but all were stone free or asymptomatic requiring no further treatment at last follow-up. Two patients have undergone regular stent change for relief of their ureteral obstruction (retroperitoneal fibrosis and endometriosis). Both patients with lymphoma had their stents removed.

### COMMENT

The formation of encrustation is well documented,<sup>4-11</sup> but recent data tend to focus on massive encrustations only with the associated problems in management. Mohan-Pillai *et al.*<sup>4</sup> reported 4 cases of encrustation, all associated with renal failure. Borboroglu and Kane<sup>5</sup> reported on six encrusted stents in 4 patients with a large associated stone burden. Stent encrustation occurred at a mean of 7 months, and 3 of the 4 patients were pregnant. Monga *et al.*<sup>6</sup> reported 31 complicated stent removals, of which 15 were calcified. All 15 had been forgotten (longer than 6 months). More recently, Singh *et al.*<sup>7</sup> attempted to calculate the amount of encrustation, and treatment was tailored to this. They reported 15 massively encrusted stents removed successfully with a combination of treatments, including three open removals and five percutaneous procedures. Lam and Gupta<sup>11</sup> described 26 retained stents that were treated in an average of 2.7 endourologic procedures. Both of these reports proposed treatment algorithms.

The cause of encrustation is multifactorial. Known risk factors for stent encrustation are long indwelling time (often because of poor compliance), urinary sepsis, history of, or concurrent, stone disease, chemotherapy, pregnancy, chronic renal failure, and metabolic or congenital abnormalities. In our series, the predominant causative factor was lithogenic history, although sepsis, pregnancy, chemotherapy, cystinuria, renal tubular acidosis, and congenital abnormalities were also implicated. The indwelling time is obviously

of paramount importance, and 75.5% of our stents had become encrusted within 6 months. More surprising perhaps is that 42.8% had become encrusted within 4 months and 14.3% at 2 months. As shown in Figure 1, the peak time at which stents were encrusted was 4 and 5 months (18 stents [36.7%]). Although it is not possible to calculate an incidence of encrustation, these data certainly suggest that stents should be changed at least within 4 months and optimally every 2 months. The stent that had encrusted by 1 month was in a pregnant woman with a ureteropelvic junction stone. She was treated with insertion of a second stent alongside the encrusted stent until she delivered, after which the stent was removed by rigid ureteroscopy.

Five patients had more than one encrusted stent, with a total of 13 encrusted stents. Eliminating the stents for which treatment was delayed by non-compliance (1 patient, two stents), the mean stent time for their first encrusted stent was 6.0 months. The second encrustation occurred at a mean of 3.3 months. Two (28.6%) of the seven recurrent stents had encrusted by 2 months. This emphasizes the need to minimize stent indwelling times in patients with a history of encrustation, and in these patients, stent change should ideally occur every 6 weeks.

When treating impacted stents, it is not always possible to identify them preoperatively. We have attempted to form a simplified algorithm for management (Fig. 2). Treatment should be prompt, and when there is any doubt about function, a renogram should be performed. Nephrostomy or the placement of a second stent may be necessary. Where encrustation is minimal, correct management is by attempted removal under general anesthesia, followed by ureteroscopic intervention if the stent cannot be removed easily. All attempts to remove impacted stents must be under fluoroscopic control. Conversely, if encrustation is marked or removal under anesthesia has failed, ESWL is a valuable and successful first-line treatment. Shocks should be focused on the maximal area of encrustation. Ureteroscopy can then be repeated as required. Using this approach to treatment, 42 (85.7%) of our 49 stents were successfully treated with an average number of procedures of 1.86 per patient. Safety guidewires should be used during ureteroscopy, and it is frequently necessary to pass a second stent alongside the impacted one when ureteroscopy is not initially successful. PCNL is used as second-line treatment unless stone load, particularly at the upper end, warrants PCNL as the primary procedure. Table I shows that the mean number of procedures required to remove stents is lower with primary treatment using URS or PCNL. This is as might be

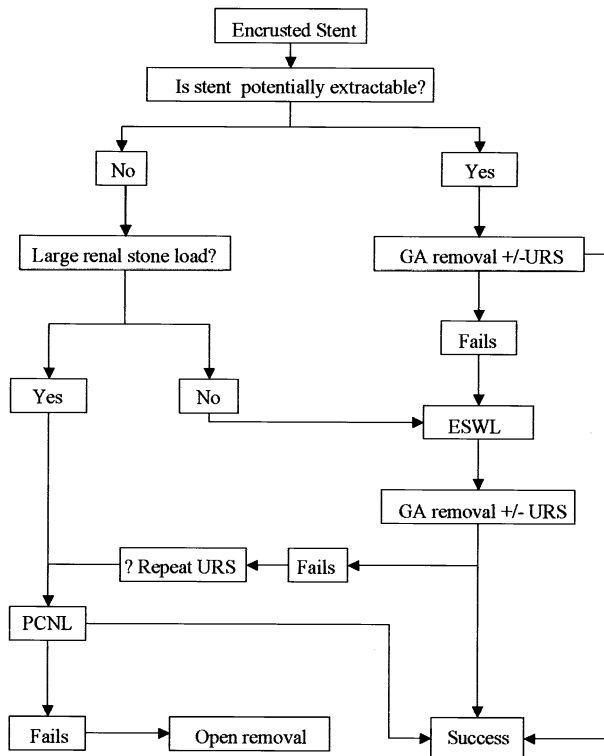


FIGURE 2. Algorithm for treatment of encrusted stents. GA = general anesthetic.

expected, because both are highly efficacious. However, we have found the adjunctive use of ESWL with URS useful, because it can target the encrustations on the proximal end of the stent, which are the hardest to reach with a retrograde approach. This does mean a higher number of interventions, but this is due to the sessions of ESWL, which are the least invasive. Despite being highly successful, primary PCNL should not be used for simple impacted stents. Where PCNL is used, URS may be required at the same time to remove more distal encrustation, and this approach was used once in our series. Open surgery is rarely necessary and should be reserved for resistant cases.

The stent material certainly appears to have an impact on the risk of encrustation. Polyethylene is no longer used, because it is brittle and at risk of fragmentation. Silicone is inert and relatively resistant to encrustation; however, it is extremely flexible and consequently difficult to use in many circumstances. Polyurethane is commonly used and combines the benefits of polyethylene and silicone. Many modern stents use a hydrophilic coating (hydrogel). These retain water within their structure, making the stent easier to use, because they are softer, with less friction and consequently more slippery.<sup>12</sup> There are conflicting reports regarding the hydrophilic coating and the risk of encrustation. Cormio *et al.*<sup>13</sup> reported that in a pig model,

hydrophilic surfaces were less likely to encrust. Conversely, Desgrandchamps *et al.*<sup>14</sup> found that hydrophilic stents may carry an increased risk of encrustation. More recently, Choong *et al.*<sup>15</sup> validated an in vitro model using human urine and tested commonly used stents. Their results suggested that hydrogel coatings significantly increase the risk of encrustation compared with the same stent without the hydrogel coating or in a silicone control. In our experience, the encrustations seem initially to form around the black bismuth markings on the stent. The pores on stents can cause problems, as this appears to be the weakest point and can lead to fragmentation. Clearly although stent design has advanced, a lot of work is still to be done both in basic design and biomaterials.

## CONCLUSIONS

Stent encrustation constitutes a serious complication of ureteral stent use and can result in difficult stent removal. Our series was not biased to the heaviest encrustations only and therefore represents the day-to-day management of these stents. The principal treatment must be aimed at avoiding encrustation, and this can be achieved by minimizing the indwelling time, especially in those with specific risks. All patients should be counseled with respect to the complications of long-term use and advised when their stent should be changed. Any patient with a previous history of encrustation should have their stent changed every 6 weeks. Stent logs and stent registries are useful to achieve this and to avoid delayed removal. When patients do recurrently form encrustations on their stents, a different type of stent with a different material can be used. ESWL and ureteroscopy, either alone or in combination, offer highly successful outcomes and are recommended as first-line treatments, resorting to PCNL only if these fail.

## REFERENCES

1. Zimskind PD, Fetter TR, and Wilkerson JL: Clinical use of long-term indwelling silicone rubber ureteral splints inserted cystoscopically. *J Urol* 97: 840–841, 1967.
2. Finney RP: Experience with new double J ureteral catheter stent. *J Urol* 120: 678–681, 1978.
3. Dunn MD, Portis AJ, Kahn SA, *et al*: Clinical effectiveness of new stent design: randomised single-blind comparison of tail and double-pigtail stents. *J Endourol* 14: 195–202, 2000.
4. Mohan-Pillai K, Keeley FX Jr, Moosa SA, *et al*: Endourological management of severely encrusted ureteral stents. *J Endourol* 13: 377–379, 1999.
5. Borboroglu PG, and Kane CJ: Current management of severely encrusted ureteral stents with a large associated stone burden. *J Urol* 164: 648–650, 2000.
6. Monga M, Klein E, Castañeda-Zūñiga WR, *et al*: The forgotten indwelling ureteral stent: a urological dilemma. *J Urol* 153: 1817–1819, 1995.

7. Singh I, Gupta NP, Hemal AK, *et al*: Severely encrusted polyurethane ureteral stents: management and analysis of potential risk factors. *Urology* 58: 526–531, 2001.
8. Schulze KA, Wettlaufer JN, and Oldani G: Encrustation and stone formation: complication of indwelling ureteral stents. *Urology* 25: 616–619, 1985.
9. Spirnak JP, and Resnick MI: Stone formation as a complication of indwelling ureteral stents: a report of 5 cases. *J Urol* 134: 349–351, 1985.
10. Somers WJ: Management of forgotten or retained indwelling ureteral stents. *Urology* 47: 431–435, 1996.
11. Lam JS, and Gupta MD: Tips and tricks for the management of retained ureteral stents. *J Endourol* 16: 733–741, 2002.
12. Denstedt JD, Wollin TA, and Reid G: Biomaterials used in urology: current issues of biocompatibility, infection and encrustation. *J Endourol* 12: 493–500, 1998.
13. Cormio L, Talja M, Koivusalo A, *et al*: Biocompatibility of various indwelling double-J stents. *J Urol* 153: 494–496, 1995.
14. Desgrandchamps F, Moulinier F, Daudon M, *et al*: An in vitro comparison of urease-induced encrustation of JJ stents in human urine. *Br J Urol* 79: 24–27, 1997.
15. Choong SKS, Wood S, and Whitfield HN: A model to quantify encrustation on ureteric stents, urethral catheters and polymers intended for urological use. *Br J Urol Int* 86: 414–421, 2000.