



Platinum Priority – Kidney Cancer

Editorial by Maria J. Ribal on pp. 91–92 of this issue

Natural History of Renal Angiomyolipoma (AML): Most Patients with Large AMLs >4 cm Can Be Offered Active Surveillance as an Initial Management Strategy

Jaimin R. Bhatt^{a,b}, Patrick O. Richard^a, Nicole S. Kim^a, Antonio Finelli^a,
Karthikeyan Manickavachagam^a, Laura Legere^a, Andrew Evans^c, York Pei^d,
Jenna Sykes^e, Kartik Jhaveri^f, Michael A.S. Jewett^{a,*}

^aDepartments of Surgical Oncology and Surgery (Urology), Princess Margaret Cancer Centre, University Health Network, and the University of Toronto, Toronto, Ontario, Canada; ^bDepartment of Urology, University Hospital Ayr, Scotland, UK; ^cDepartment of Pathology, Princess Margaret Cancer Centre, University Health Network, and the University of Toronto, Toronto, Ontario, Canada; ^dDepartment of Medicine, Princess Margaret Cancer Centre, University Health Network, and the University of Toronto, Toronto, Ontario, Canada; ^eDepartment of Biostatistics, Princess Margaret Cancer Centre, University Health Network, and the University of Toronto; ^fJoint Department of Medical Imaging, Princess Margaret Cancer Centre, University Health Network, and the University of Toronto, Toronto, Ontario, Canada

Article info

Article history:

Accepted January 26, 2016

Associate Editor:

Christian Gratzke

Keywords:

Renal angiomyolipoma
Active surveillance
Large size
>4 cm

Abstract

Background: The natural history of renal angiomyolipoma (AML) is unknown. Treatment recommendations are based on smaller case series, with selection bias towards symptomatic patients.

Objective: To define the natural history of renal AML, including growth rates, size, and clinical presentation.

Design, setting, and participants: We used a unique radiology data-mining system (Montage; Montage Healthcare Systems, Philadelphia, PA, USA) to retrospectively review the radiology database in an academic health centre between 2002 and 2013 to identify all renal AMLs. Of 2741 patients identified, 447 with 582 AMLs had three or more imaging studies suitable for analysis.

Intervention: Angioembolisation, surgery, radiofrequency ablation, and mammalian target of rapamycin inhibitors.

Outcome measurements and statistical analysis: The primary end point was the growth rate of untreated AMLs. We used a linear mixed-effects model to determine change in growth rate over time. We evaluated the association among growth rate, size, and patient factors as well as interventions.

Results and limitations: The majority of untreated AMLs (>92%) had not grown at a median follow-up of 43 mo, with no difference in growth rates between AMLs ≤4 and >4 cm. Most AMLs occurred in female participants (80%) and were asymptomatic (91%). Tuberous sclerosis complex (TSC) was confirmed in 3.8% (n = 17) and presented at an earlier age. Median size was 1 cm but was significantly larger for TSC (5.5 cm; p < 0.001). Interventions were performed in 5.6% of patients. Limitations of our study include the retrospective design, selection against fat-poor AMLs, and lack of histology.

Conclusions: This large, single-institution series on AMLs confirms that lesions >4 cm do not require early intervention based on size alone. The vast majority are sporadic, asymptomatic, and initially harmless, with a negligible growth rate. Our findings support a policy of initial active surveillance for all asymptomatic AMLs.

Patient summary: We evaluated the natural history and growth rates of renal AMLs. We found no difference in growth rates between AMLs >4 and ≤4 cm. Initial AS appears to be a safe management option.

© 2016 European Association of Urology. Published by Elsevier B.V. All rights reserved.

* Corresponding author. Division of Urology, Department of Surgical Oncology, Princess Margaret Cancer Centre, University Health Network, University of Toronto, 610 University Avenue, Suite 3-130, Toronto, Ontario M5G 2M9, Canada. Tel. +1 416 946 2909; Fax: +1 416 598 9997.
E-mail address: m.jewett@utoronto.ca (Michael A.S. Jewett).

1. Introduction

Renal angiomyolipoma (AML) is one of the most common solid benign renal tumours. Composed of varying proportions of fat, smooth muscle, and blood vessels, most AMLs occur sporadically, while 10% of AMLs occur in hereditary form [1]. The hereditary form of AML occurs in up to 75% of patients with tuberous sclerosis complex (TSC), a rare autosomal-dominant multiorgan hamartomatous disorder associated with constitutive activation of the mammalian target of rapamycin (mTOR) pathway [1]. With the increasing use of body imaging by ultrasound and computed tomography (CT), more incidental renal tumours are being detected [2]. Most AMLs have characteristic features because of the unequivocal appearance of fat [3].

Several case series and reviews of AMLs have appeared since Oesterling et al first published the frequently quoted review of the world literature with a Johns Hopkins cohort of 13 patients. The authors recommended a size limit ≤ 4 cm for observation of asymptomatic AMLs [4–6]. As a result, AMLs are often imaged intensively and treated empirically when they reach the 4-cm threshold. The true natural history may remain unknown because symptomatic cases are more likely to be identified and included in case series. The current European Association of Urology guidelines recommend treatment in well-selected cases, including large tumours, those in women of child-bearing age, and where follow-up or access to emergency care is inadequate [7]. A size threshold for treatment remains controversial, with previous recommendations suggesting 3–4 cm. We hypothesised that the majority of incidentally detected AMLs grow slowly, remain asymptomatic, and therefore do not require intensive follow-up or early intervention, regardless of initial size. The objective of this study is to evaluate clinical presentation, initial size, and growth rates of all reported AMLs with three or more images in our institution.

2. Patients and methods

Research and ethics board approval was granted for a retrospective review of all radiology reports in our academic health centre, which consists of two large city hospitals and the Princess Margaret Cancer Centre, from 2002 to 2013. The words *renal* and *angiomyolipoma* were used in the search, which was conducted with a unique radiology record-crawler system (Montage; Montage Healthcare Systems, Philadelphia, PA, USA) in patients who underwent abdominal imaging (CT or ultrasound) for any reason. The presence of AML was confirmed in the report, with evidence of fat in the lesion being diagnostic on CT. Montage is a leading software solution for health care data mining that enables subscribers to search entire databases using terms of interest and generates anonymised data reports with accession numbers, which are then used to retrieve patient identifier numbers in the radiology information system [8].

Detailed image report and chart reviews were performed in patients who had three or more abdominal scans with at least 1 yr between the first and last scans. Patient demographics (age, gender, proven TSC status, symptoms, imaging indication) and tumour characteristics (number of lesions, size of the dominant lesion initially and in follow-up scans) were recorded. We also looked at intervention rates, tumour

size, and demographics of the excluded 2294 patients with fewer than three images. Interventions (mTOR inhibitors, selective angioembolisation [SAE], radiofrequency ablation [RFA], and surgery) were noted.

2.1. Statistical analysis

We measured lesion size by maximum axial diameter and categorised it as either ≤ 4 or >4 cm. We recorded medians and ranges for continuous variables and frequencies and used proportions to describe categorical variables. We compared continuous variables (for the largest lesion per patient) using the Mann-Whitney test and categorical variables using the Fisher exact test. We calculated follow-up time per lesion as the number of years between the date of the first available scan that reported the mass to the date of the last scan. To calculate average growth per year, we divided the difference in growth from the last scan to the first scan by the number of years between the scans. The individual growth curves were plotted for at least three time points, with a locally weighted scatterplot smoothing (lowess) curve added to represent the average growth curve for each group [9]. A linear mixed-effects model was fit to the two groups to determine whether there was a difference in growth rate over time. We used patient identifier numbers as a random (cluster) effect. Maximum axial diameter was log-transformed to stabilise the variance.

All statistical tests were two-sided, and a p value <0.05 was deemed significant, with 95% confidence intervals (CIs) reported. All analyses were performed using the open source R version 3.0.1 (R Foundation for Statistical Computing, Vienna, Austria).

3. Results

A total of 2741 patients were identified with a radiology report that included a reference to renal AML. Filtering to those who had three or more abdominal imaging studies yielded 447 patients with 582 tumours followed up for a median of 43 mo (range: 14–144 mo). Patient and tumour characteristics are shown in Table 1. A flow diagram of the whole cohort of 2741 is provided in Supplementary Figure 1.

Ninety percent of AMLs measured ≤ 4 cm, but those >4 cm presented at a younger age and were more likely to be symptomatic, with a greater likelihood of TSC and intervention. Although the majority were asymptomatic in both groups, pain was the most common symptom. There was no difference between individual symptom types in either group (Table 2).

To measure natural growth rates, we measured all untreated AMLs. We also included cases that had intervention and measured sizes prior to treatment. Only three patients who had interventions had no preceding images, but we picked them up in the search because of multiple images following intervention. We therefore analysed 444 patients and plotted growth curves on 471 lesions, of which 414 (88%) were ≤ 4 cm and 57 (12%) were >4 cm (Supplementary Fig. 2). Smoothed lowess curves are shown in Figure 1. According to slope estimates, there was no difference in the average growth rate of lesions ≤ 4 cm compared to those >4 cm (0.002 cm/yr; 95% CI, -0.017 to 0.020; $p = 0.86$; Table 3).

Ninety-one percent of AMLs did not grow or grew slowly, with an average growth rate of 0.02 cm/yr. Forty-one AMLs (9%) grew with a 10-fold growth rate ≥ 0.25 cm/yr compared to an average of 0.021 cm/yr. We therefore define a grower as an AML with a growth rate ≥ 0.25 cm/yr.

Table 1 – Patient and lesion characteristics

Variable	Category	Frequency or value (%)
Patient specific		
	No.	447
Gender	Female	358 (80.1)
	Male	89 (19.9)
Age at diagnosis, yr	Median	58.1
	(Range)	(18.5–90.3)
Clinical presentation	Incidental	406 (90.8)
	Symptomatic	41 (9.2)
TSC status	Positive	17 (3.8)
	No/not tested	430 (96.2)
Epithelioid AML	Yes	2 (0.4)
	Not known	445 (99.6)
Intervention	None	422 (94.4)
	Yes	25 (5.6)
Size of lesion at baseline, cm	≤4	400 (89.5)
	>4	47 (10.5)
Laterality of lesion	Bilateral	73 (16.3)
	Left kidney	192 (43.0)
	Right kidney	182 (40.7)
No. of lesions per patient	1	346 (77.4)
	2	76 (17.0)
	3	19 (4.3)
	≥4	6 (1.3)
No. of lesions per patient	Median	1
	(Range)	(1–6)
Follow-up, mo	Median	43.2
	(Range)	(14.6–144.6)
Lesion specific		
	No.	582
Size of lesion at baseline, cm	≤4	524 (90.0)
	>4	58 (10.0)
	Median size	1
	(Range)	(0.2–29)
Laterality of lesion	Not specified	5 (0.9)
	Left kidney	288 (49.5)
	Right kidney	289 (49.7)

AML = angiomyolipoma; TSC = Tuberous sclerosis complex.

Table 4 shows the differences between those masses that were managed conservatively and those that underwent intervention.

Of 25 cases that had 30 interventions among the 447 patients (5.6%), 48% were asymptomatic and 28%

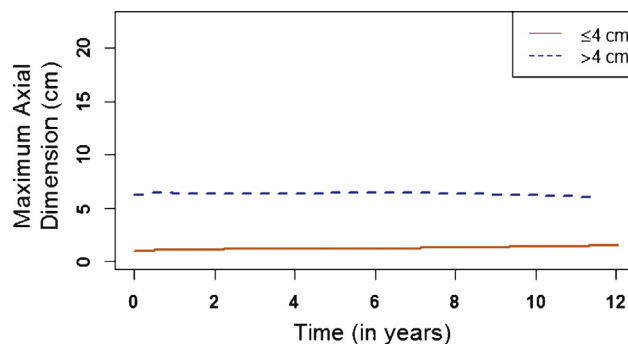


Fig. 1 – Locally weighted scatterplot smoothing (lowess) curves demonstrating average growth rates over time for renal angiomyolipomas ≤4 vs >4 cm.

Table 3 – Results from a mixed-effects model comparing the average growth slopes over time in angiomyolipomas ≤4 cm with those >4 cm, showing no significant difference between the two groups

Variable	Estimate	95% CI	p value
Baseline estimates:			
≤4 cm [†]	–0.061	–0.116 to –0.006	0.029
>4 cm	1.921	1.746–2.095	<0.0001
Slope estimates, cm/yr:			
≤4 cm [†]	0.021	0.015–0.026	<0.0001
>4 cm	0.0017	–0.017 to 0.020	0.859

CI = confidence interval.
[†] Reference group.

were ≤4 cm. The majority (93%) of interventions were elective. Two cases of retroperitoneal bleed were managed with emergency SAE. Patient and intervention details are shown in Supplementary Table 1. As demonstrated in Supplementary Figure 1, of the remaining 2294 who had fewer than 3 images, only 13 had an intervention (0.56%). Details of all the interventions by size are provided in Supplementary Table 2. Patients with proven TSC presented at a significantly younger age, had larger baseline lesions

Table 2 – Demographic comparison by angiomyolipoma size at baseline

Variable	Category	≤4 cm, n (%) (n = 400)	>4 cm, n (%) (n = 47)	Total	p value
Age at diagnosis, yr	Median	58.9	52.4	58.1	0.0057
	(range)	(18.5–90.3)	(19–89)	(18.5–90.3)	
Gender	Female	319 (79.8)	39 (83)	358 (80.1)	0.7
	Male	81 (20.2)	8 (17)	89 (19.9)	
TSC status	No/unknown	393 (98.2)	37 (78.7)	430 (96.2)	<0.0001
	Yes	7 (1.8)	10 (21.3)	17 (3.8)	
Clinical presentation	Incidental	374 (93.4)	32 (68.1)	406 (90.8)	<0.0001
	Symptomatic	26 (6.6)	15 (31.9)	41 (9.2)	
Symptom type	Pain	19 (73.1)	10 (66.7)	29 (70.7)	0.73
	Haematuria or bleeding	7 (26.9)	5 (33.3)	12 (29.3)	
Intervention	Yes	7 (1.8)	18 (38)	25 (5.6)	<0.0001
	No	393 (98.2)	29 (62)	422 (94.4)	

TSC = tuberous sclerosis complex.

Table 4 – Demographic comparison of 422 patients who did not have intervention with 25 patients who had an intervention

Variable	Category	No intervention, n (%) (n = 422)	Intervention, n (%) (n = 25)	Total, n (%) (n = 447)	p value
Age at diagnosis, yr	Median (range)	58.1 (18.5–90.3)	49 (20–66)	58.1 (18.5–90.3)	0.002
Gender	Female	336 (79.6)	22 (88)	358 (80.1)	0.44
	Male	86 (20.4)	3 (12)	89 (19.9)	
TSC status	No/not known	411 (97.3)	19 (76)	430 (96.2)	<0.0001
	Yes	11 (2.7)	6 (24)	17 (3.8)	
Clinical presentation	Incidental	394 (93)	12 (48)	406 (90.8)	<0.0001
	Symptomatic	28 (7)	13 (52)	41 (9.2)	
Initial size	≤4 cm	393 (93.1)	7 (28)	400 (89.5)	<0.0001
	>4 cm	29 (6.9)	18 (72)	47 (10.5)	
Growth rate (total 444)	≤0.25 cm/yr	389 (92)	17 (77)	406 (91.4)	0.03
	>0.25 cm/yr	33 (8)	5 (23)	38 (8.6)	

TSC = tuberous sclerosis complex.

Table 5 – Summary of historic and contemporary reviews and series reporting on angiomyolipomas

Author, yr	No. of patients	Age, yr	Age for TSC+, yr	TSC cases, %	Female, %	Incidental cases, %	Symptomatic cases, %	Intervention rate, %	Growth rate, cm/yr
Oesterling et al., 1986 [4]	253 (lit review)	43.1	30	20	81	36	64	43–95	NR
Oesterling et al., 1986 [4]	13 (own series)	NR	24	15	100	61	39	62.5	NR
Nelson and Sanda, 2002 [5]	336 (13 series)	48	30.3	19	86	41	59	49	NR
Lane et al., 2008 [21]	209	50	32	5.7	78	51	49	100	NR
Aydin et al., 2009 [22]	185	51.2	31.5	8.2	80	NR	NR	100	NR
Sooriakumaran et al., 2010 [23]	102	31	27	69	NR	85	15	34.3	NR
Mues et al., 2010 [6]	91	57	43	4.4	77	83.9	16.1	46.2	0.088
Ouzaid et al., 2014 [24]	130	53.3	NR	7.7	77.7	78.5	21.5	13	NR
Present series, 2016	447	58.1	26.9	3.8	80.1	90.8	9.2	5.6	0.021

NR = not reported; TSC = tuberous sclerosis complex.

and multiple tumours, were significantly more symptomatic, and underwent more interventions than the rest of the cohort (Supplementary Table 3).

4. Discussion

The management of renal AMLs has changed over the past four decades. Prior to 1976, nearly 93% of AML patients underwent nephrectomy [4]. Oesterling et al found in their 1986 literature review found that 82% of AMLs ≥4 cm were symptomatic and recommended that these masses should be considered for treatment [4]. A subsequent review of 13 series by Nelson and Sanda in 2002 revealed that treatment rates varied from 52% to 94% for symptomatic AMLs >4 cm [5]. In our series, we found that only 30% of AMLs >4 cm were symptomatic and that for the entire group, >90% were asymptomatic. Common symptoms include abdominal pain and haematuria. We found that abdominal pain (70–76%) was more common than haematuria or bleeding in the overall cohort and non-TSC subset (30% and 24%, respectively) compared to 57% of patients with TSC who reported haematuria or bleeding. This difference was not significant ($p = 0.16$). Table 5 summarises the published historical and contemporary reviews and series of AML.

Clinicians managing this condition are often concerned that AMLs >4 cm may rupture and cause life-threatening haemorrhage. A meta-analysis of 165 cases of spontaneous perirenal haemorrhage by Zhang and colleagues showed that 29.1% of these incidents were caused by AMLs, with a further 29.7% caused by renal malignancies [10]. The majority of these patients presented with acute flank pain, with 11% presenting in haemorrhagic shock. Most patients underwent a nephrectomy, but this meta-analysis was conducted on studies between 1985 and 1999. The majority of patients with a spontaneous perirenal bleed present without prior symptoms [1]. In our experience, this type of morbid presentation is relatively rare given the prevalence of AML. In our series, the rate of retroperitoneal bleeding was 0.4%, there were no fatalities, and both cases were managed by emergency arterial embolisation, with one case (29 cm) undergoing an elective nephrectomy 8 mo later. Both cases occurred in females, and both showed aneurysms in their AMLs, which were >13 cm. Only one patient was proven to have TSC.

Renal AML treatment recommendations have been made based on tumour size, the presence of symptoms, and estimated compliance with follow-up [7]. As most AMLs now present asymptotically (Table 5), clinicians are faced with a treatment dilemma when a patient has a

“large” (>4 cm), asymptomatic AML. Our observations do not support the 4-cm size threshold as a treatment trigger given that the majority of lesions >4 cm in our series were asymptomatic (up to 70%). We found no difference in growth rates for lesions ≤4 cm and >4 cm ($p = 0.86$). Our study has evaluated individual growth rates of AMLs with a median follow-up of 43 mo and confirms that AMLs grow slowly or not at all in >90% of cases. Only 9% grow at rates ≥ 0.25 cm/yr. These “growers” tend to be significantly more symptomatic than the slow-growers or nongrowers and also occur more frequently in the TSC group.

The intervention rate in our cohort is also lower than in other series (Supplementary Table 3). The most common intervention is SAE (73%) followed by surgery (13%). Our overall surgery rate is much lower than others (4 of 447, or 0.9%), with three partial nephrectomies for small, fat-poor AMLs and one radical nephrectomy for a 29-cm tumour after SAE. Furthermore, other, fat-poor AMLs that present as small enhancing renal masses may be missed by the radiologist and undergo renal tumour biopsies, resulting in a lower rate of surgical treatment. Of 496 biopsied small renal masses, 36 (7.3%) were fat-poor AMLs in a series by Richard and colleagues [11]. SAE is increasingly used prophylactically in those at risk of bleeding, with good results [12,13], but there is no consensus on the optimal size cut-off for embolisation. Earlier studies reported treatment of lesions ≥ 4 cm, while more recent series include tumours up to a mean of 10.3 cm [12–14]. RFA is another preemptive treatment alternative, and we used it in two lesions. RFA is traditionally reserved for smaller lesions but may be feasible in AMLs >6 cm when used with saline-cooled electrodes [15].

The diagnosis of AML during pregnancy is a rare occurrence, and the relative risk of rupture is currently unknown. Nevertheless, the guidelines have suggested that women of child-bearing age should be treated. The evidence for treating AMLs in pregnancy is based largely on case reports. A review of the literature by Zapardiel and colleagues yielded 13 case reports of ruptured AMLs [16]. We cannot make any conclusive recommendations from our cohort regarding AML in pregnancy because we do not provide obstetric services in our institutions.

As per earlier studies, most AMLs are sporadic, but previous series have shown higher rates of TSC overall, ranging from >5% to 20% in the review by Oesterling et al. The series by Sooriakumaran et al had a strong selection bias towards TSC patients, hence reporting 69% in their cohort of 102 patients [23]. Our series had proven TSC in 3.8% of patients, similar to the recent series by Mues et al (4.4%) [6], but much less than other studies, possibly because more incidental sporadic lesions are being picked up on abdominal imaging. It may be that the actual rate of TSC in our series is higher than reported because we focused only on genetically proven TSC cases, whereas up to 25% of TSC cases may not currently be identifiable with conventional genetic screening tests [17].

Two cases of proven metastatic epithelioid AML in our series were treated with mTOR inhibitors, a rare variant with potential for malignancy. Sirolimus has been used in TSC patients and produced tumour regression while the

patients remain on treatment, but there was an increase in tumour volume when the drug was discontinued [18]. Everolimus produced a response rate of 42% compared to placebo in the double-blind, randomised phase 3 Everolimus for Angiomyolipoma Associated with Tuberous Sclerosis Complex or Sporadic Lymphangiomyomatosis (EXIST-2) trial, with 80% of those patients showing >30% reduction in tumour volume by 24 wk [19]. Current recommendations for management of AMLs in TSC by the International TSC Consensus Group state that embolisation and corticosteroids should be used as first-line therapy for acute haemorrhage: Nephrectomy should be avoided. For asymptomatic, growing AMLs >3 cm, the group recommends using mTOR inhibitors as a first-line therapy followed by SAE or partial resection [20].

Our study is limited by its retrospective nature, a relatively short median follow-up of just under 4 yr, and the possible variability in radiology reporting. Cases of fat-poor AMLs may have not been captured by the Montage application. Furthermore, patients who had imaging or interventions outside our institution may have been missed. We excluded cases with fewer than three images to get a more accurate growth trajectory: This could represent a selection bias against those with less frequent imaging. Nevertheless, we addressed this potential bias and found that the intervention rate was even lower in those with fewer than two images (0.56%). We feel, however, that the majority of clinically significant AMLs would have had at least three images, including those who had an intervention (median: eight images). Finally, we did not have histopathologic data.

Nevertheless, this is the largest single-institution series of growth and events related to AMLs. It increases our knowledge of the natural history of AML with less selection bias than previous series. The longitudinal nature of the data provides important information about growth rates. We have used a dynamic measurement of growth rate per year to guide treatment recommendations rather than an absolute size. Our findings support active surveillance (AS) of renal AMLs regardless of initial size, including most AMLs >4 cm, with follow-up imaging at reduced intensity in stable cases. Some would argue that elective intervention may be necessary for patients who have large AMLs where access to emergency interventions is difficult.

A future challenge is to identify complicated AMLs that may grow rapidly or haemorrhage. Use of radiologic modalities such as contrast-enhanced ultrasound scanning to detect aneurysms may aid in detecting vulnerable patients. Studies of the composition and proportions of fat to blood vessels of the lesion on CT scan may also be potentially useful. Research from bedside to laboratory bench is needed to elucidate prognostic biomarkers in addition to radiologic features to predict those at risk of progression.

5. Conclusions

Our study confirms that most sporadic AMLs are asymptomatic and do not grow or grow slowly, regardless of initial size.

With the rising incidence of incidentally detected renal mass lesions resulting from widespread axial imaging, we propose that patients who have asymptomatic or mildly symptomatic AMLs, even if they are >4 cm, should be offered initial AS and that AS be continued in those whose masses do not grow. Patients should be aware of a small risk of progression and bleeding, particularly with fast growers (>0.25 cm/yr). Further research is needed for prognostic markers to predict the small proportion of lesions at risk of progression.

Author contributions: Michael A.S. Jewett had full access to all the data in the study and takes responsibility for the integrity of the data and the accuracy of the data analysis.

Study concept and design: Jewett, Finelli, Bhatt.

Acquisition of data: Bhatt, Richard, Kim, Manickavachagam.

Analysis and interpretation of data: Bhatt, Richard, Jewett, Sykes.

Drafting of the manuscript: Bhatt, Richard, Kim, Jewett.

Critical revision of the manuscript for important intellectual content: Bhatt, Richard, Kim, Finelli, Legere, Evans, Pei, Sykes, Jhaveri, Jewett.

Statistical analysis: Sykes.

Obtaining funding: None.

Administrative, technical, or material support: None.

Supervision: Jewett, Finelli.

Other (specify): None.

Financial disclosures: Michael A.S. Jewett certifies that all conflicts of interest, including specific financial interests and relationships and affiliations relevant to the subject matter or materials discussed in the manuscript (eg, employment/affiliation, grants or funding, consultancies, honoraria, stock ownership or options, expert testimony, royalties, or patents filed, received, or pending), are the following: None.

Funding/Support and role of the sponsor: None.

Acknowledgment: Babatunde Adenrele, Team Lead, Service and Support, RIS/PACS Specialist, Joint Department of Medical Imaging, University Health Network and University of Toronto.

Appendix A. Supplementary data

Supplementary data associated with this article can be found, in the online version, at <http://dx.doi.org/10.1016/j.eururo.2016.01.048>.

References

- [1] Bissler JJ, Kingswood JC. Renal angiomyolipomata. *Kidney Int* 2004;66:924–34.
- [2] Smith SJ, Bosniak MA, Megibow AJ, Hulnick DH, Horii SC, Raghavendra BN. Renal cell carcinoma: earlier discovery and increased detection. *Radiology* 1989;170:699–703.
- [3] Halpenny D, Snow A, McNeill G, Torreggiani WC. The radiological diagnosis and treatment of renal angiomyolipoma-current status. *Clin Radiol* 2010;65:99–108.
- [4] Oesterling JE, Fishman EK, Goldman SM, Marshall FF. The management of renal angiomyolipoma. *J Urol* 1986;135:1121–4.
- [5] Nelson CP, Sanda MG. Contemporary diagnosis and management of renal angiomyolipoma. *J Urol* 2002;168:1315–25.
- [6] Mues AC, Palacios JM, Haramis G, et al. Contemporary experience in the management of angiomyolipoma. *J Endourol* 2010;24:1883–6.
- [7] Ljungberg B, Bensalah K, Canfield S, et al. EAU guidelines on renal cell carcinoma: 2014 update. *Eur Urol* 2015;67:913–24.
- [8] MONTAGE search and analytics. Montage Healthcare Solutions Web site. <http://montagehealthcare.com/what>. Accessed January 23, 2016.
- [9] Fitzmaurice GM, Laird NM, Ware JH. *Applied longitudinal analysis*. Hoboken, NJ: Wiley; 2004.
- [10] Zhang JQ, Fielding JR, Zou KH. Etiology of spontaneous perirenal hemorrhage: a meta-analysis. *J Urol* 2002;167:1593–6.
- [11] Richard PO, Jewett MA, Bhatt JR, et al. Renal tumor biopsy for small renal masses: a single-center 13-year experience. *Eur Urol* 2015;68:1007–13.
- [12] Ramon J, Rimon U, Garniek A, et al. Renal angiomyolipoma: long-term results following selective arterial embolization. *Eur Urol* 2009;55:1155–62.
- [13] Kothary N, Soulen MC, Clark TW, et al. Renal angiomyolipoma: long-term results after arterial embolization. *J Vasc Interv Radiol* 2005;16:45–50.
- [14] Ewalt DH, Diamond N, Rees C, et al. Long-term outcome of transcatheter embolization of renal angiomyolipomas due to tuberous sclerosis complex. *J Urol* 2005;174:1764–6.
- [15] Gregory SM, Anderson CJ, Patel U. Radiofrequency ablation of large renal angiomyolipoma: median-term follow-up. *Cardiovasc Intervent Radiol* 2013;36:682–9.
- [16] Zapardiel I, Delafuente-Valero J, Bajo-Arenas JM. Renal angiomyolipoma during pregnancy: review of the literature. *Gynecol Obstet Invest* 2011;72:217–9.
- [17] Northrup H, Krueger DA, International Tuberous Sclerosis Complex Consensus Group. Tuberous sclerosis complex diagnostic criteria update: recommendations of the 2012 International Tuberous Sclerosis Complex Consensus Conference. *Pediatr Neurol* 2013;49:243–54.
- [18] Bissler JJ, McCormack FX, Young LR, et al. Sirolimus for angiomyolipoma in tuberous sclerosis complex or lymphangioleiomyomatosis. *New Engl J Med* 2008;358:140–51.
- [19] Bissler JJ, Kingswood JC, Radzikowska E, et al. Everolimus for angiomyolipoma associated with tuberous sclerosis complex or sporadic lymphangioleiomyomatosis (EXIST-2): a multicentre, randomised, double-blind, placebo-controlled trial. *Lancet* 2013;381:817–24.
- [20] Krueger DA, Northrup H, International Tuberous Sclerosis Complex Consensus Group. Tuberous sclerosis complex surveillance and management: recommendations of the 2012 International Tuberous Sclerosis Complex Consensus Conference. *Pediatr Neurol* 2013;49:255–65.
- [21] Lane BR, Aydin H, Danforth TL, et al. Clinical correlates of renal angiomyolipoma subtypes in 209 patients: classic, fat poor, tuberous sclerosis associated and epithelioid. *J Urol* 2008;180:836–43.
- [22] Aydin H, Magi-Galluzzi C, Lane BR, et al. Renal angiomyolipoma: clinicopathologic study of 194 cases with emphasis on the epithelioid histology and tuberous sclerosis association. *Am J Surg Pathol* 2009;33:289–97.
- [23] Sooriakumaran P, Gibbs P, Coughlin G, et al. Angiomyolipomata: challenges, solutions, and future prospects based on over 100 cases treated. *BJU Int* 2010;105:101–6.
- [24] Ouzaid I, Autorino R, Fatica R, et al. Active surveillance for renal angiomyolipoma: outcomes and factors predictive of delayed intervention. *BJU Int* 2014;114:412–7.