

Anthony R. Mundy and Daniela E. Andrich

Institute of Urology, London, UK

Accepted for publication 17 June 2010

What's known on the subject? and What does the study add?

Urethral strictures are common and increasingly common in an ageing population. The treatment is controversial and particularly the relative roles of urethrotomy or urethral dilatation on the one hand and urethroplasty on the other. This review aims to provide a comprehensive overview of the subject including less commonly discussed issues such as the history and pathology of stricture disease.

We would hope that a comprehensive overview of the subject will give a sharper perspective to aid the investigation and management of patients with urethral strictures.

KEYWORDS anterior urethra, review, urethral strictures, urethroplasty

INTRODUCTION A urethral stricture is a scar of the subepithelial tissue of the corpus spongiosum that constricts the urethral lumen. As the constriction progresses, obstruction develops and leads to symptoms either directly related to the obstruction or as a secondary consequence. By consensus, the term stricture is applied only to constrictions of the anterior urethra, which is that part surrounded by the corpus spongiosum and that runs from its origin from the membranous urethra at the level of the perineal membrane to the external urinary meatus [1]. Elsewhere in the urethra the terms stenosis or contracture are preferred.

INCIDENCE

Urethral strictures are common and always have been. Dilatation was described by Shusruta >600 years BC [2]; 19th century expert opinion had it that 15–20% of adult men had a stricture [3]; and in the 21st century in the UK NHS >16 000 men require admission to hospital each year because of urethral stricture disease and >12 000 of them need an operation at an annual cost of ≈£10 million [4,5]. The estimated prevalence in the UK is ≈10/100 000 men in their youth rising to about 20/100 000 by the age of 55 years then to 40/100 000 by the age of 65 years and to over 100/100 000 thereafter [6] (Fig. 1). Still higher rates have been reported from the USA [7].

AETIOLOGY (Table 1)

Historically strictures were more or less associated with gonococcal urethritis excepting a few cases due to trauma [8]. But,

a stricture was rarely due to a single infection; it was much more commonly due to chronic or recurrent infection over many years, the average onset of symptoms of a stricture being >20 years after the initial attack of gonorrhoea [8]. An alternative explanation, of course, is that it takes 20 years for a stricture to develop after a single episode of untreated gonorrhoea. In the developed world, gonococcal strictures are rare and most strictures today are either iatrogenic or idiopathic [9,10]. Iatrogenic causes include urethral catheterization, cystoscopy, TURP and surgery for hypospadias. Idiopathic strictures include those occurring at any age and at any site where the cause is not known, and those short sharp strictures that occur in adolescents and young adults at the junction of the proximal and middle thirds of the bulbar urethra (Fig. 2), which some think are congenital [11,12] (possibly due to incomplete rupture of the urogenital membrane and related to what is called Cobb's collar [13] by some and Moorman's ring [14] by others).

FIG. 1. The incidence of strictures by age. Data taken from McMillan et al. (1994) [6].

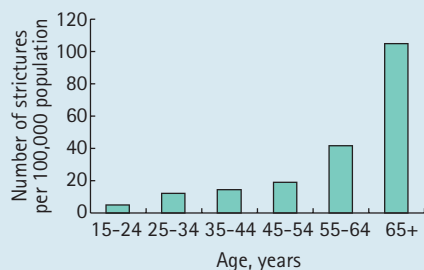


TABLE 1 Stricture aetiology and prevalence

Site	Cause	Incidence, %
Penile	Idiopathic	15
	Iatrogenic	40
	Inflammatory	40
	Traumatic	5
Bulbar	Idiopathic	40
	Iatrogenic	35
	Inflammatory	10
	Traumatic	15

The cause is linked to the patient's age and to the site of the stricture. Meatal strictures may be due to ammoniacal dermatitis in the very young, lichen sclerosus (LS) in the adolescent and young adult, and instrumentation or poor hygiene [15] at any age. Previous surgery for hypospadias is another cause. Hypospadias surgery is increasingly common and so are its complications, including a stricture at the site of surgery [16,17]. This may be apparent shortly after the surgery but may not present until adolescent or early adult life [18].

LS is also increasingly common. It was barely recognized 40 years ago [19] but is now the commonest identifiable cause of penile strictures in young and middle-aged adults. As a cause of stricture disease, it starts at the

FIG. 2. A typical idiopathic stricture of the bulbar urethra, short, sharp and at the junction of the proximal and middle thirds, putatively congenital.

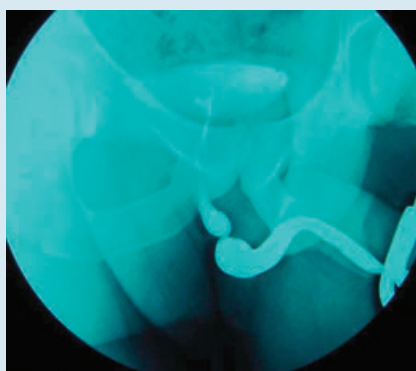
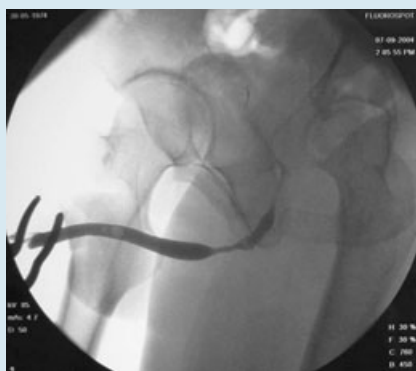

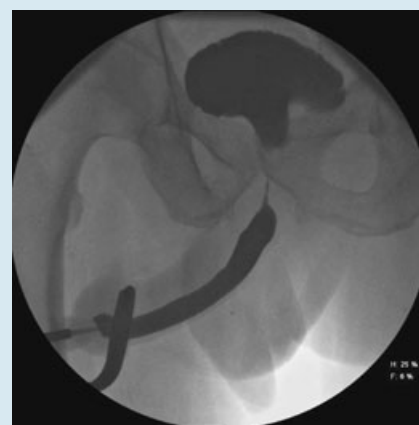
FIG. 3. A typical post-catheterization stricture of the distal bulbar and proximal penile urethra.



meatus and may then spread proximally up the penile (pendulous) urethra. Strictures in this segment are otherwise uncommon and tend to follow catheterization, affecting the bulbo-penile junction primarily, or are idiopathic affecting the mid-segment.

The bulbar urethra is that part of the urethra enclosed by the bulbospongiosus muscle and is the commonest site for a stricture. Idiopathic strictures tend to occur in

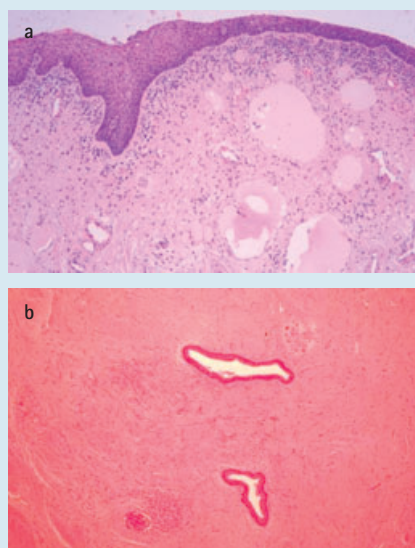
FIG. 4. A typical post-TURP 'sphincter stricture' of the proximal bulbar and membranous urethra. The bladder neck is wide open as a consequence of the TURP.



adolescent and young adults as discussed above. Iatrogenic strictures occur at any age and are typically found at the junction of the bulbar and penile urethra after catheterization (Fig. 3), as described in the last paragraph, or in the proximal bulbar urethra, commonly involving the membranous urethra and urethral sphincter mechanism, after TURP (so called 'sphincter strictures') [20] (Fig. 4). TURP is a less common cause of strictures than it was [21,22] because it is performed less frequently and with better instruments, but new technology also involves instrumentation and can also cause stricture disease. During the course of a TURP, it has been estimated that the instrument moves up and down within the urethra some 800 times [22]!

Ischaemia is a common underlying cause or predisposing factor in stricture disease but rarely referred to as such. Catheter strictures are a classic example. Occurring, as they commonly do, at the natural curve of the anterior urethra, they have been described as 'pressure sores' of the urethra [23], although

FIG. 5. A low power photomicrograph of a normal urethra and a strictured urethra. Haematoxylin and eosin stained, x60



the trauma of catheterization is another factor [24], as is leaching of toxic compounds from the catheter itself when latex has been used in its manufacture [25]. Anecdotally, strictures seem to be more common in smokers and smoking also seems to affect adversely the outcome of urethroplasty [26]. This ischaemia seems to be a consequence of microvascular disease, as in diabetes, rather than peripheral or central vascular disease [26].

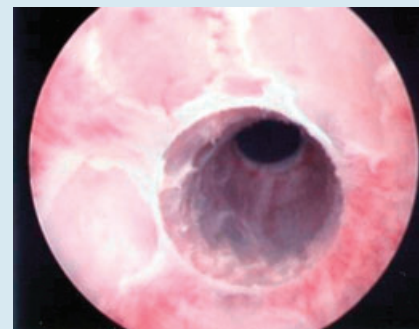
PATHOLOGY

Excepting trauma or otherwise when the urethral lumen is obliterated, the characteristic feature of a stricture is replacement of the corpus spongiosum deep to the urethral epithelium by dense fibrous tissue due to local thrombophlebitis. The

epithelium itself is usually intact, albeit abnormal [8,27] (Fig. 5). The pathogenesis of stricture disease has

not been widely studied and when it has been studied it has principally been with infection as the cause [28], although animal models do exist [29,30] particularly using electro-coagulation trauma to the rabbit urethra as a model of iatrogenic injury. The importance of urinary extravasation into the corpus

FIG. 6. An endoscopic photograph showing squamous metaplasia of the urethra and two developing strictures.



spongiosum is stressed by all and the worse the extravasation, the worse the fibrosis [30,31]. The location of the urethral glands coincides well with the site of incidence of infection-related strictures implicating these as a cause [31]. However, the only study of the pathogenesis of stricture disease that the authors are aware of shows that the primary change is metaplasia of the urethral epithelium from its normal pseudo-stratified columnar type to stratified squamous epithelium [32] (Fig. 6). This is a more fragile epithelium, which therefore tends to split when distended during voiding. These fissures or ulcers in the epithelium lead to focal extravasation of urine on voiding that leads in turn to subepithelial fibrosis. Microscopic foci of fibrosis form and coalesce over a period of years to form macroscopic plaques, which may then constrict the urethra if they coalesce around the circumference of the urethra to form a complete ring. In this model of stricture formation, bacterial infection may induce the squamous metaplasia, as may several other factors: chemical, physical or biological, but it is not necessary for the further development of the stricture (Fig. 7).

Metaplastic change also occurs proximal to a definitive stricture, due to chronic distension under pressure during voiding, giving the epithelium a so-called 'wash leather' appearance. This type of metaplasia may be reversible once the obstruction is relieved but reversibility or otherwise cannot be determined at the time of surgery.

More recent studies have investigated the pathology at a molecular level and it seems that the fibrosis in strictures is not the same as in wound healing elsewhere [33,34].

'fibrosis in strictures is not the same as in wound healing elsewhere'

FIG. 7. Flow chart of stricture pathology.

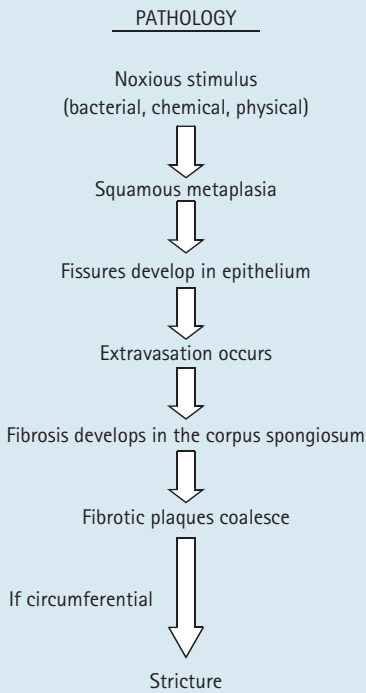


FIG. 8. The characteristic features of LS: hyperkeratosis of the epithelium with atrophy and loss of the rete pegs and degeneration of the basal cells; sclerosis of the subepithelial collagen and lymphocytic infiltration of the dermis. Initially the dermis is homogenized and oedematous; later in the course of the disease it is hyalinized and sclerotic; this is Haematoxylin and Eosin stain x60.

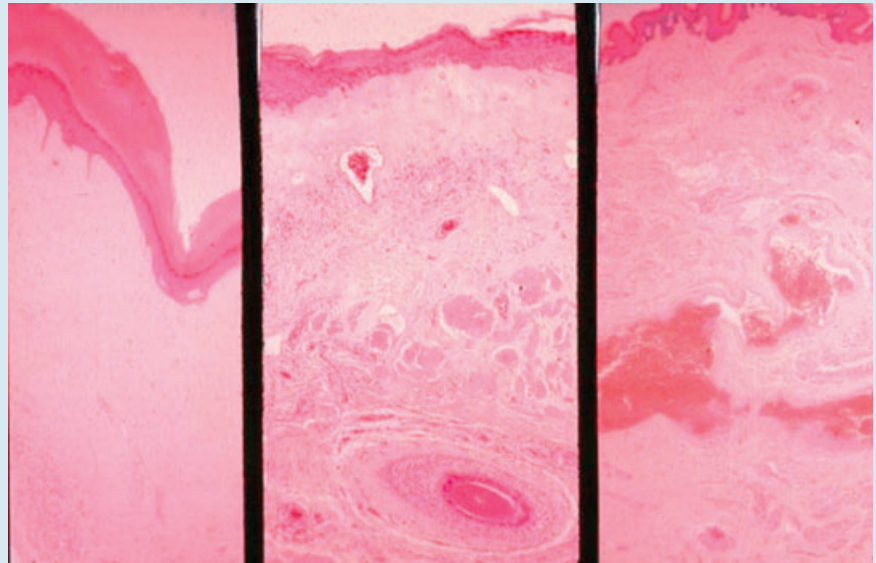


TABLE 2 Complications of untreated strictures

Complication	Incidence, %
Thick-walled, trabeculated bladder	85
Acute retention	60
Prostatitis	50
Epididymo-orchitis	25
Periurethral abscess	15
Stones (Bladder, urethra)	10
Hydronephrosis	20

Specifically, there is an unusually high proportion of type 1 collagen compared with type 3, which usually predominates in a scar [33]. Not surprisingly, this is more marked in the subepithelial part of a stricture than more peripherally. It is also more marked in traumatic strictures than non-traumatic strictures [34], in which there is often surprisingly high smooth muscle content [31]. It also seems possible that this process of spongiofibrosis might be induced by damage to neural nitric oxide synthase-carrying nerves [35] or by the over-expression of connective tissue growth factor, which has been identified as a cause of other fibrotic diseases [36].

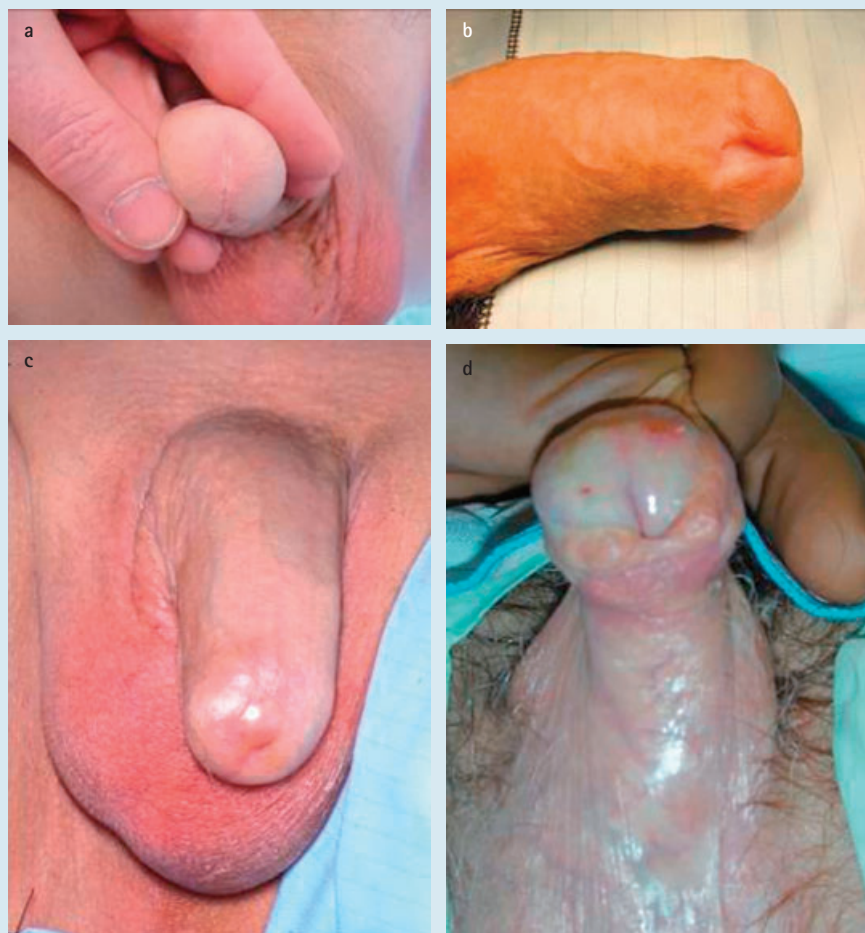The pathology of LS is different [37,38]. It used to be called balanitis xerotica obliterans and is still commonly known as this and especially by its initialism BXO. It is an atrophic rather than a proliferative fibrosis (Fig. 8) with features suggesting an autoimmune cause, although an infective aetiology has been proposed [39]. It typically starts as an itchy patch of white discoloration on the inner aspect of the foreskin or glans. Patches eventually coalesce and the affected skin becomes inelastic and brittle so that it splits and becomes sore rather than itchy. Scarring of the glans and the prepuce commonly causes dense adhesions between the two making circumcision difficult if not impossible. However, if the disease affects only the foreskin and the glans, circumcision is curative in >90% of patients [40]. In more severely affected patients, there is loss of the normal glans contour and of the coronal sulcus, meatal regression and penile oedema (Fig. 9). Scarring around the meatus causes meatal stenosis that can spread proximally to involve the fossa navicularis and then the penile urethra causing it to be strictured and palpably thickened (Fig. 10). It can affect the bulbar urethra as well but only rarely.

NATURAL HISTORY

Complications from high voiding pressure and chronic or recurrent infection will ultimately develop if the stricture remains untreated, initially in the lower urinary tract, causing a thick-walled, trabeculated, sacculated bladder with prostatitis, epididymo-orchitis and bladder stones (Fig. 11), and ultimately in the upper urinary tract and kidneys as well, leading to bilateral hydronephrosis [8,41] (Table 2).

The natural history of the untreated disease was described in detail in texts from the 18th and 19th centuries [e.g. [3,42]]. With progressive obstruction of the urethra there will eventually be periurethral abscess formation and urinary extravasation leading ultimately to fistulation through to the skin and, the so-called 'watering can perineum' (Fig. 12). Although acute retention is common, complete obstruction leading to rupture of the acutely retained bladder and death is not. Chronic fistulation through to the skin, recurrent sepsis and bladder stones associated with obstructive uropathy, and then obstructive nephropathy and renal failure are outcomes that are more common in the untreated patient.

FIG. 9. The clinical appearance of LS: (a) a white rim to the meatus (pathognomonic); (b) loss of the normal contour of the glans and the coronal sulcus and meatal regression in a circumcised patient; (c) fusion of the foreskin to the glans in an uncircumcised patient; and (d) as with (c) but with oedema and ulceration of the glans.

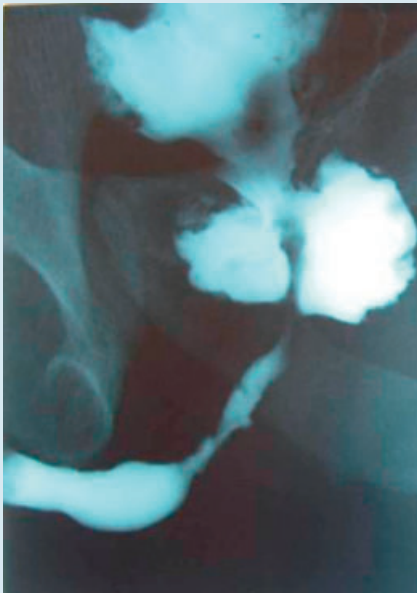


With traditional treatment by urethral dilatation, the urethral lumen may be maintained but at the expense of extending the stricture longitudinally along the length of the urethra with recurrent bleeding, recurrent sepsis and increasingly difficult dilatation with time [43]. Patients tended to become critically dependent on the particular surgeon/urologist who dilated their strictures and who 'knew his way through'. Septicaemia after dilatation was the main risk in treated patients and so the single greatest development in the 20th century for them was the development of antibiotics to reduce the incidence and mortality of these septic episodes.

FIG. 10. The typical appearance of a penile urethral stricture in a patient with LS, typical but not pathognomonic.

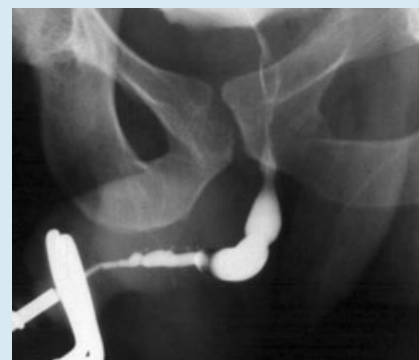

FIG. 11. Cavitation of the prostate with a thick-walled trabeculated bladder proximal to a long standing stricture.



Today, such an outcome is less common in the developed world than it was but is still seen more commonly than it should be and reflects an uncritical overuse of dilatation. It is more common where medical care is lacking, for more understandable reasons.

CLINICAL EVALUATION

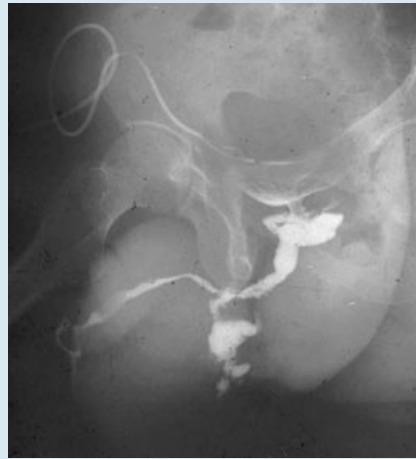Most patients present with progressive symptoms of lower urinary tract obstruction:

- hesitancy
- a poor stream
- terminal dribbling
- and a feeling of incomplete emptying.

The strongest association of any of these symptoms with stricture disease is a sensation of incomplete emptying. Occasionally, patients present with acute retention, more commonly with haematuria, and more commonly still with UTI. Even so 70% present with obstructive symptoms alone. Symptomatic assessment is best formalized using a questionnaire such as the AUA symptom index [44] or, better still, a specifically designed Patient Reported Outcome Measure (PROMs) which is in development in the UK at present.

Physical examination is usually unrewarding unless there is a history of disease or surgery

FIG. 12. A bulbar stricture with extravasation, cavitation and fistulation – the 'watering can perineum'.



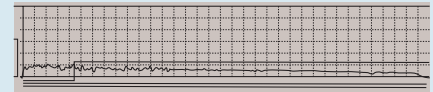
because only the meatus can be seen and because strictures are not usually palpable. Nonetheless, the penis should always be carefully examined for signs of LS, which may be very slight and confined just to whiteness around the margins of the urethral meatus (Fig. 9a).

A urinary flow rate study may be diagnostic. The long slow protracted flow pattern with a plateau appearance in a man aged <65 years is typical (Fig. 13). The combination of a flow rate study and the AUA symptom score in a man with a known urethral stricture can help to direct treatment in an untreated patient and to detect a recurrent stricture in a treated patient [45,46].

Ultrasonography is useful to identify a thick-walled bladder before voiding and residual urine afterwards, both indicating long-standing obstruction [8]. If either of these is present, hydronephrosis may be found. This tends to disappear after voiding and can be missed if the kidneys are only scanned after voiding.

If symptoms and a urinary flow rate study suggest a urethral stricture, a retrograde urethrogram is the next step to make the definitive diagnosis of a stricture, as distinct from any other cause of obstructed voiding. This should show the full length of the urethra up to the stricture and past it through the urethral sphincter, prostatic urethra and

FIG. 13. The typical 'plateau' appearance of the flow curve in a patient with a stricture.



bladder neck and into the bladder [47] (Figs 2–4,10,11). If a good quality image of the full length of the urethra in a patient tilted well laterally is not obtained then a voiding cystogram should be performed to show the urethra proximal to the stricture. The authors always ask for both to be sure of getting good images and to look for significant distension of the proximal urethra above the level of the stricture on voiding, indicating significant obstruction.

Many patients with LUTS have cystoscopy as the means of definitive diagnosis. This may confirm the diagnosis of a stricture; and

'Most patients present with progressive symptoms of lower urinary tract obstruction'

indeed flexible cystoscopy at the time of the initial consultation may speed up the process of diagnosis and treatment significantly. Unfortunately, endoscopy does not show the length of the stricture or the state of the urethra proximal to the stricture, unless it is opened up first. However, there are many urologists who think that a urethrogram is not necessary before deciding upon treatment, mainly because they are going to do a urethrotomy anyway. This is not the authors' view. Urethrography gives a more complete assessment.

Some urologists find ultrasonographic assessment of a stricture helpful [48] and few would argue that the images of a stricture in the distal bulbar and penile urethra are impressive. Unfortunately, most strictures are in the more proximal bulbar urethra where the urethra is curving upwards into the pelvis, away from the skin and so away from the ultrasound probe and where ultrasonography is therefore at the limit of its usefulness.

TREATMENT

In the absence of complications, treatment is for symptoms and if the symptoms are not particularly troublesome, treatment is

unnecessary. If urinary infection has been troublesome or the patient has presented with acute retention then treatment reduces the risk of further complications. The authors' (anecdotal) experience is that if the flow rate is >10 mL/s, symptoms are not usually very troublesome and complications are unusual; if it is 5–10 mL/s then urinary infection is more common but in the absence of infection, symptoms may still not be very troublesome; and it is only when the flow rate is <5 mL/s that symptoms are particularly troublesome and that urinary infection and acute retention are a real risk in otherwise unsusceptible individuals.

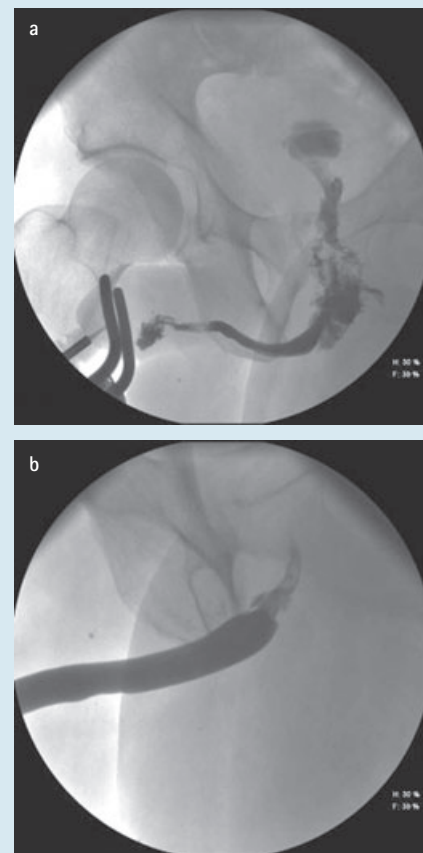
It has been known for centuries that in an acute inflammatory episode, 'resting' the urethra with suprapubic catheter drainage will allow the situation to improve, sometimes considerably (Fig. 14). For this reason, it is sensible to allow for this before definitive treatment by whatever means.

TREATMENT BY INSTRUMENTATION
(Table 3)

The traditional treatment for urethral stricture has been urethral dilatation for the last 3000 years and direct vision internal urethrotomy (DVIU) for the last 40 years. The advantage of endoscopic diagnosis with a rigid cystoscope is that the surgeon can proceed directly to DVIU immediately. This is perfectly reasonable in a patient presenting for the first time with a short stricture in the bulbar urethra, as about half of such patients will be cured in this way. However, if the stricture is at any other site or if there has been previous DVIU or dilatation and the stricture has recurred then instrumentation will almost certainly fail to cure the patient

[49–51]. Management by palliation is perfectly acceptable, of course, as long as the patient and the surgeon appreciate that it is palliation, but most patients want a cure. For this reason, patients should be counselled that it might be more 'cost effective' to go straight to primary urethroplasty [52] and so

FIG. 14. The effect of resting an acutely inflamed urethral stricture: urethrography (a) before and (b) after.



INDICATIONS FOR INSTRUMENTATION

Curative

First time treatment of a short bulbar stricture

Palliative

Further treatment of a short bulbar stricture

Treatment of any other stricture

Dilatation or DVIU?

Meatal/fossa navicularis strictures

Sphincter strictures

Easy strictures

Difficult strictures needing a guide-wire

Personal preference choice

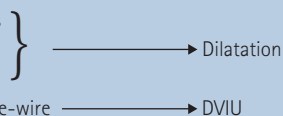


TABLE 3

Indications for Instrumentation

FIG. 15. Endoscopic photograph of a DVIU through a stricture (with an associated false passage) with a fine ureteric catheter (as an alternative to a guidewire) through the stricture to show the way.

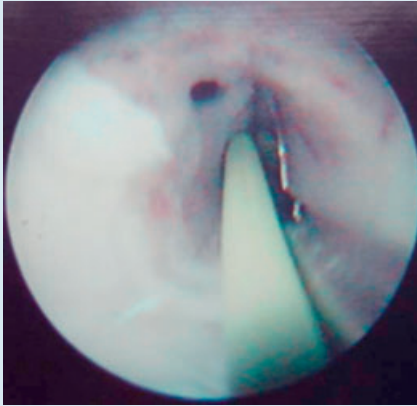
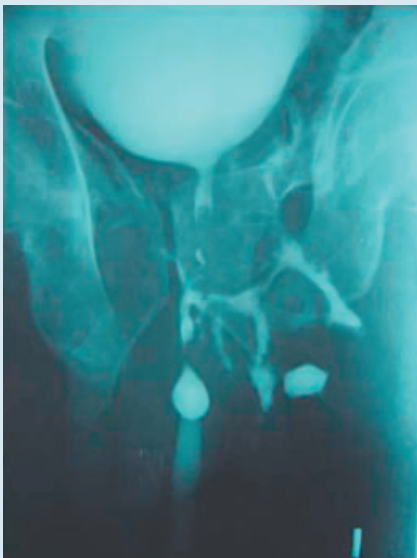

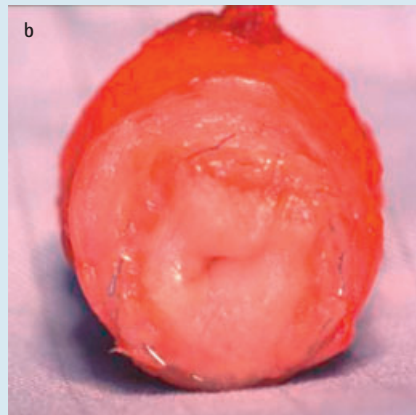
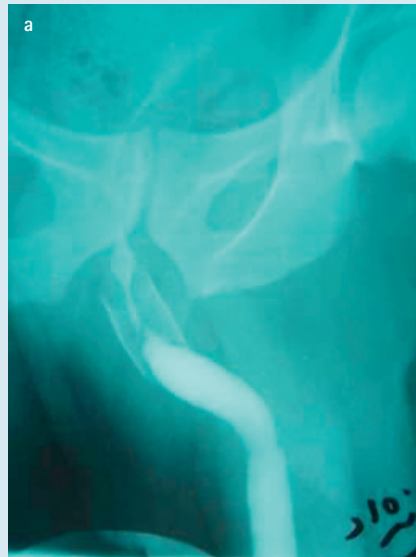
FIG. 16. Retrograde urethrogram 3 months after a single DVIU, when a guidewire was not used.



it is sensible to organize a urethrogram before planning treatment.

Nonetheless, many patients will opt for DVIU because it seems more minor, particularly if they are encouraged in that view by their medical advisor, and many might prefer palliation or might be more suited to palliation particularly if it is only required occasionally, no more frequently than once a year. There is no evidence that DVIU is any better than dilatation [50], although intuitively many surgeons feel it is. Equally, although there is no evidence to support it, it would seem sensible intuitively to dilate post-

FIG. 17. A failed UroLume stent in the bulbar urethra: (a) radiologically and (b) after excision at operation.



instrumentation meatal strictures and sphincter strictures after TURP, in the former because it is a quick office procedure and in the latter, because dilatation does not risk sphincter damage as DVIU does. Intuitively, long 'difficult' strictures of the urethra may fare better from having a guidewire passed endoscopically and then having a DVIU under direct vision (Fig. 15) but once again there is no evidence to support it. The Sachse urethrotome [53] is 20 F calibre and so most patients having a urethrotomy have their urethral calibre restored to 20 F or a little more unless the calibre is further enhanced by dilatation. Both DVIU and dilatation should be covered by prophylactic antibiotics [54], and what evidence there is

suggests that keeping a catheter for 3 days after urethrotomy reduces the risk of early postoperative extravasation and infective complications [55]. Clearly both of these complications are more likely when the procedure is more than usually traumatic, which is all too common. Today, in the UK, this usually occurs when DVIU is attempted without passing a guidewire first. It is frighteningly easy to lose sight of the lumen (Fig. 16).

If a stricture is going to recur, it is usually apparent symptomatically within 6 months or a year at most [56]. There is no data on the timing of detectable recurrence of a stricture by any objective means.

Self-catheterization has been popularized to reduce the risk of recurrent stricture disease after urethrotomy or dilatation. It is, of course, continuing dilatation by another name. There is some long-term follow-up data to support this contention [57,58], but there is also evidence that it does not significantly reduce the risk of hospitalization and the need for 'surgical' dilatation or urethrotomy to deal with recurrent strictures [59]. In any case, many patients simply stop using it because of the sheer inconvenience [60]. Nonetheless, there are patients with strictures who live in remote circumstances for whom the ability to self-catheterize may be essential because medical support is lacking.

The other treatment that has been used to supplement urethrotomy has been the placement of an intraurethral stent. There are two types:

- the Wallstent or UroLume® (Pfizer Inc., UK) [61] which is incorporated into the urethral wall;
- and the Memokath® (Engineers & Doctors A/S Ltd., Hornbaek, Denmark) [62] which is not.

‘Both DVIU and dilatation should be covered by prophylactic antibiotics’

Much the most reported experience is with the UroLume. After the initial flurry of enthusiasm [63,64], more sober assessment suggests that in 'easy' strictures of the bulbar urethra the results may be satisfactory but otherwise the results are poor [65] and recurrent stricturing (Fig. 17) often requires a

difficult urethroplasty to salvage the situation when a straightforward procedure would have given a perfectly satisfactory result if used initially [66,67]. If a suitable stent could be found that could treat 'easy' strictures in 'difficult' patients, those with serious comorbidities, then stenting may find a place in our armamentarium, particularly if the stents were biodegradable [68] to reduce the incidence of long-term side-effects.

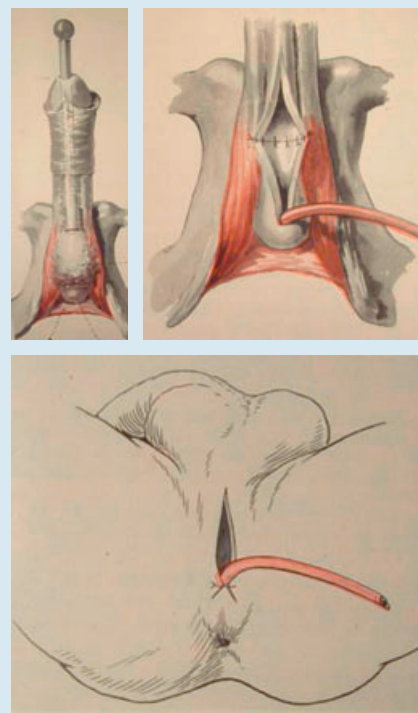
For most patients for whom urethrotomy or dilatation are inappropriate, or in whom it has failed, urethroplasty is usually the only curative option and most authors feel there is no point in performing more than one urethrotomy before recommending a urethroplasty [52,59,69,70]. However, some patients at the extreme end of the spectrum of stricture disease, typically patients who have had repeated failed surgery, particularly when complicated by comorbidity, might prefer a perineal urethrostomy or indeed would rather avoid further surgical intervention and opt a suprapubic catheter [71].

TREATMENT BY URETHROPLASTY

The development of urethroplasty

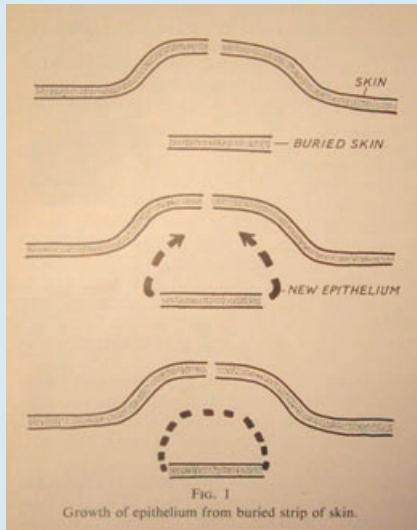
The earliest form of open stricture surgery was 'perineal section' [72]. This was in the days when peri-urethral abscess formation, extravasation and fistulation were common, indeed it might be the only way of passing urine *in extremis* and therefore a matter of life and death if dilatation proved impossible [73]. Otherwise, if acute retention developed, survival depended on a surgeon cutting down through the fistulous mass, trying to find the proximal urethra and so relieve the retention. This was often extremely difficult and often required several attempts. The French called this procedure *la boutonniere* [74]. Opening up the urethra distal to the obstruction was guided by cutting on to a dilator or 'staff' within the urethra. Once the urethra on either side of the obstruction was opened up widely, the wound was left open to discharge urine and infection. Then, gradually, urethral voiding would be re-established between the two cut ends of the urethra, in most if not all patients, and the perineal wound would heal [75]. The whole process was helped by the regular passage of a urethral dilator.

FIG. 18. The first attempt at excision and hemi-circumferential anastomosis but leaving the ventral aspect of the urethra and the wound open to heal by second intention. Note the 'stricture mass' as it used to be known, in the first illustration. Reproduced from Hamilton Russell (1915) [78].



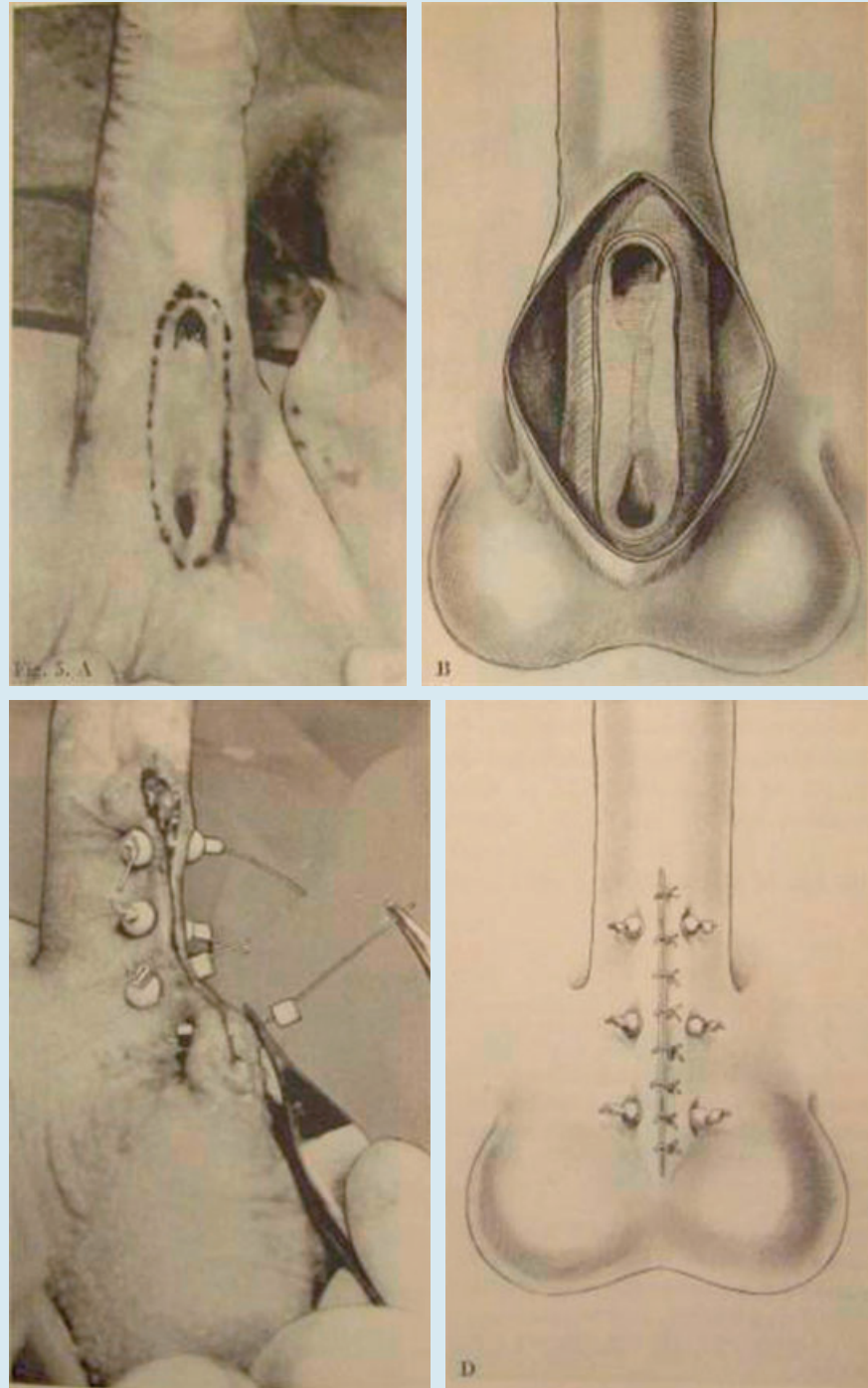
In the late 19th century and early 20th century, incision of the stricture and its associated peri-urethral fibrotic mass was made easier with the development of anaesthesia, and came eventually to be replaced by excision, but with no intention of bringing the two ends of the urethra together [76]. Again the wound was left open to heal by second intention but now a catheter was left in for a few days postoperatively, transurethrally or, more commonly, transperineally, to allow the perineal wound to heal more quickly. Interval dilatation would then follow after the catheter was removed; there was never any expectation that the excision was curative. By the turn of the 19th–20th century there were the first reports of excision of a stricture with suturing of the two ends of the urethra together dorsally and leaving the ventral hemi-circumference open [77,78] (Fig. 18). The patient was managed thereafter as previously. At this time, some surgeons were beginning to suggest that excision might be curative.

FIG. 19. The 'buried skin-strip' principle. Reproduced from Davis and Traut (1926) [79].



By the mid-20th century surgeons had learnt that a strip of buried epithelium would convert itself into a tube if it was open at both ends [79] (Fig. 19) and Johanson [80] devised a form of urethroplasty based on this principle (Fig. 20). Dennis Browne [81] used the same principle for hypospadias repair (Fig. 21). In both instances, the surgery was staged. In the first stage, the diseased urethra was marsupialized, leaving a wide-open urethrostomy proximally to void through during the interim. Then, at the second stage, a neo-urethral strip was created ≈ 1.5 cm wide, consisting of the residual native urethra together with the adjacent skin that had been sutured to it, which ran from the urethrostomy proximally to the healthy distal urethra or to the meatus, depending on the location and the length of the stricture. This would become the new urethra. The skin on either side of the strip was widely undermined to allow it to be brought together comfortably over the now buried skin strip and an indwelling catheter. After 2–3 weeks, the neo-urethra would be formed and the catheter was removed. Many patients did well, particularly when compared with how they would have fared otherwise, but fistulation and sacculation were common. In the 1960s and 1970s, the buried skin-strip principle was replaced by a second stage in which the neo-urethral strip was rolled up to form a tube instead with much more satisfactory results [82]. Similarly the practice of excision of the stricture and anastomosis of the two ends

FIG. 20. The Johanson procedure: the application of the buried skin-strip procedure to stricture disease. Marsupialization at the first stage and then burying the skin strip for it to form a tube at the second stage. Note the degree of eversion of the skin to minimize the risk of fistulation. Reproduced from Johanson (1953) [80].



dorsally but leaving the ventral aspect open was replaced by the use of a skin flap to close the ventral defect primarily [83]. It was then a short step to perform either excision of

the stricture and hemi-circumferential anastomosis, for shorter strictures; or stricturotomy, instead of marsupialization, for longer strictures and then to go on to close

FIG. 21. The Denis Browne procedure: the application of the buried skin-strip principle to hypospadias. Reproduced from Browne (1949) [81].

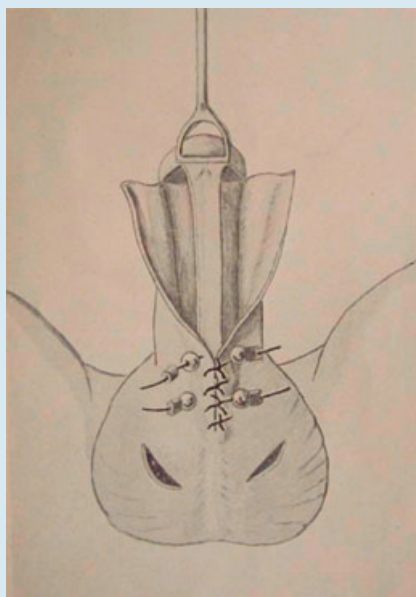
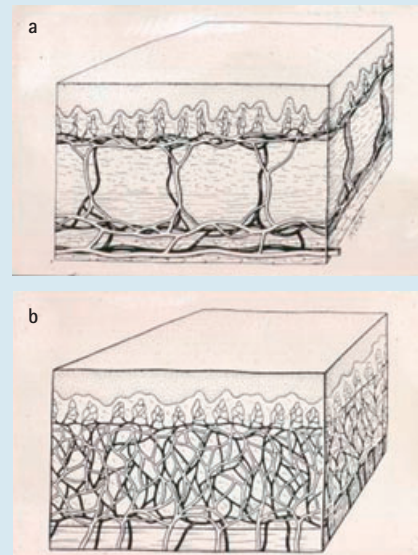


FIG. 22. Diagrammatic cross-section of (a) skin to show the intradermal and subdermal vascular plexuses and (b) buccal mucosa to show the pandermal plexus. Courtesy of Dr G. H. Jordan, Norfolk, Virginia, USA.



the urethra with a skin flap primarily and so complete all urethroplasties in one stage [84]. By such a series of historical steps we come to the present day in which staging is used as a last resort; marsupialization as a salvage procedure; and the buried skin-strip procedure not all.

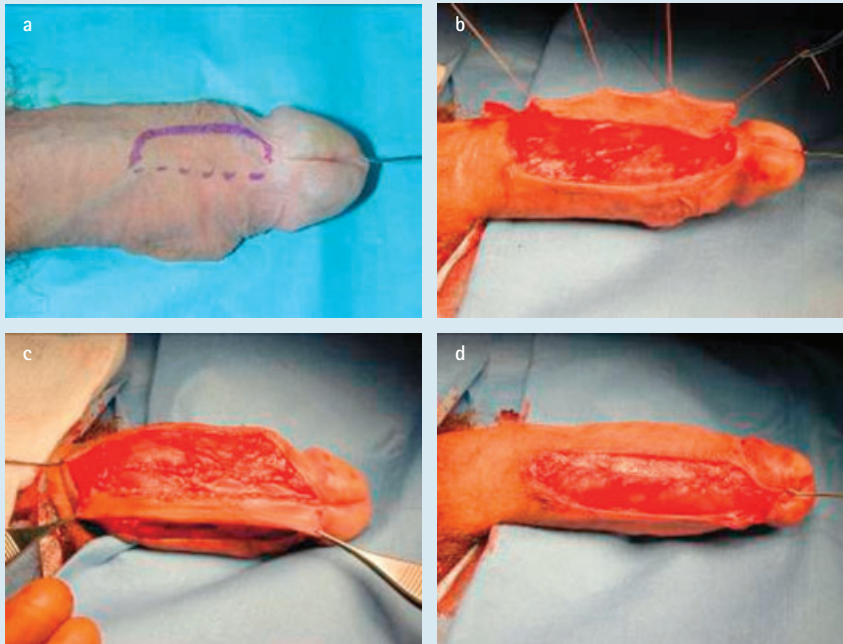
Contemporary urethroplasty

All modern surgery is either based on excision of the stricture and then restoration of continuity by a spatulated, overlapping end-to-end anastomosis when this is possible or reconstruction of the urethra by the use of grafts or flaps when it is not. Until recently, most graft repairs of urethral strictures used penile shaft skin [85]. This developed from the use of full-thickness grafts of foreskin for hypospadias repair [86]. Split-thickness grafts 'take' well but contract, which make them unsuitable for urethroplasty. Full-thickness grafts do not contract because of the presence of a critical volume of dermal collagen, and if the skin is thin and the subdermal plexus is dense then 'take' is good as long as the graft is kept still and free of haemolytic streptococcal infection during healing, both of which would prevent revascularization by the normal processes of imbibition and inosculation [87]. The problem is that they are fastidious and have to be

prepared carefully, which takes time. The re-discovery of the buccal mucosal graft (BMG) in 1992 [88,89] was a big step forwards because buccal mucosa has a pan-dermal plexus [90] (Fig. 22), as well as other attributes [91], which makes it less fastidious and therefore much quicker to harvest and prepare and just as good in everyday use.

Intuitively it used to be thought that skin flaps must be better than skin grafts because flaps carry their own blood supply with them whereas grafts have to be transferred without a blood supply and then must re-establish a blood supply at the recipient site. Again, hypospadias surgery was the driver for the development and use of penile skin flap surgery for urethral strictures [92-95]. However, meta-analysis showed that there is no difference between a graft and a flap in the cure rate of the stricture [96] and so considerations of donor-site morbidity, local genital skin scarring and the time taken to perform a procedure all become relevant. There are still advantages in using a flap particularly where there is dense scarring or poor blood supply to the local tissues, typically after previous surgery or radiotherapy [69]. For all other purposes grafts, and specifically BMGs, have replaced flaps for bulbar urethral surgery. In the penile urethra the penile skin

FIG. 23. The Orandi procedure for a simple penile urethral stricture; the original flap repair: (a) the skin incision through skin and dartos (solid line) and through skin alone (dotted line); (b) the dartos vascular pedicle developed; (c) the leading edge of the skin paddle sutured to the urethra; and (d) the following edge of the urethra sutured to the other side of the urethra to close it.



flap attributed to Orandi [84] (Fig. 23) is still useful for uncomplicated strictures but these are relatively uncommon. Grafts are more commonly used for salvage hypospadias surgery to avoid further scarring of the penile skin, which is in any case often deficient. LS is a disease of genital skin and so BMGs give much better results [40,97].

Thus for bulbar strictures that are too long for an excision and end-to-end anastomosis a BMG will generally be used in a 'stricturotomy and patch' procedure, and a flap repair is reserved for revisional surgery. Even then, some surgeons would simply re-graft. Flap repairs of the bulbar urethra are rare today [98]. For penile urethral surgery, an Orandi skin flap might well be used, except in LS, but some would now prefer a dorsal stricturotomy and BMG or a trans-ventral dorsal inlay of a BMG [99]. For LS and hypospadias salvage a one-stage repair with a BMG would be best for more limited or straightforward problems of the glanular urethra and a two-stage repair with a BMG reserved for more extensive problems involving the penile shaft and more proximally.

General considerations

There are several different types of urethroplasty but essentially the type that is used for any particular stricture depends on its length, the nature of the underlying problem and whether or not there has been previous surgery. The length is the main consideration [69]. Previous surgery may reduce the type of tissue that is available for a repair and the nature of the disease may suggest that only certain types of tissue are suitable for a repair. Specifically urethroplasty using local skin flaps may not be possible after repeated surgery for hypospadias, and LS is a disease of genital skin and so genital skin should not be used for urethroplasty in such patients [40,97].

Length is important because most strictures arise in the bulbar urethra and the bulbar urethra can stretch (up to a point) perhaps to as much as 150% of its natural length. Thus a short stricture can be excised and the urethra

reconstructed by a spatulated, overlapping end-to-end anastomosis (Fig. 24), spatulated and overlapping to give an anastomosis of sufficiently large calibre so that even with the expected degree of contraction with healing the calibre of the urethral lumen remains satisfactory. A longer stricture may not allow this without tension but may allow a semi-circumferential anastomosis and patching of the other half of the circumference of the repair with a graft or flap (Fig. 25). Longer still and the limit of 'stretchability' is exceeded and an excision is not possible without a complete circumferential reconstruction to replace that segment. Most bulbar strictures do not require such a radical approach that, in any case, needs usually to be staged. Long bulbar strictures are usually best treated by a stricturotomy to open up the narrowed urethra and then patching with a graft or flap to restore both the integrity of the urethra and its calibre (Fig. 26), which gives better results than an excision and circumferential repair, and in a single stage [69,100].

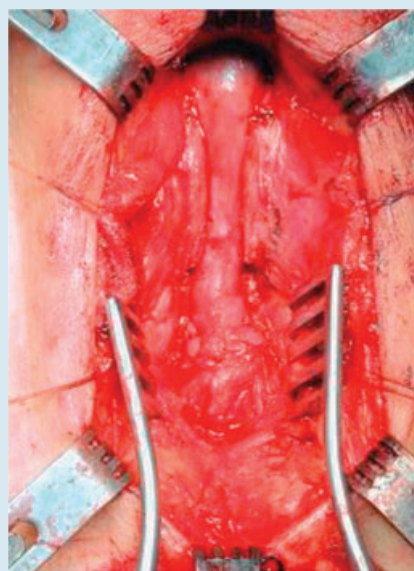
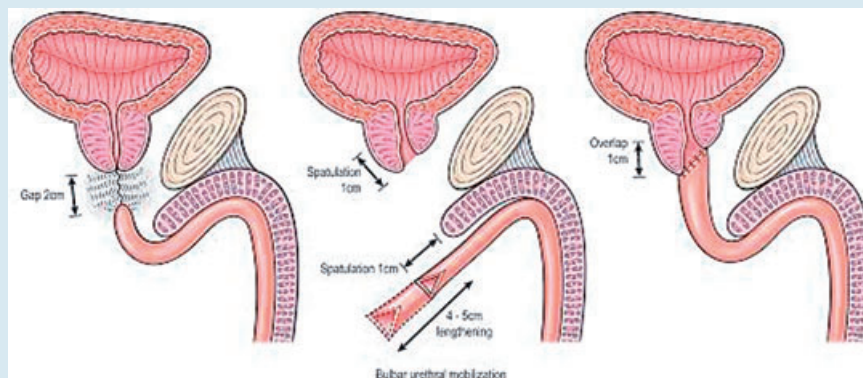
In the penile urethra, excision and end-to-end anastomosis is not possible without causing significant buckling of the penis at rest, let alone on erection, so this is not an option. The two alternatives are a 'stricturotomy and patch' in less severe circumstances or an excision and circumferential reconstruction when the fibrosis is severe. This is usually only necessary for LS or, less frequently, in hypospadias-related strictures or rare other conditions.

'LS is a disease of genital skin and so genital skin should not be used for urethroplasty in such patients'

BULBAR URETHROPLASTY (Fig. 27)

The most common urethroplasty is for a bulbar stricture [4,7,9,10,69,98] and there is now good evidence that if a patient has failed to respond to one urethrotomy or dilatation the most cost-effective way forwards and the only good chance of a cure is by urethroplasty [52,59]. Today, most commonly, that means a 'stricturotomy and patch' using a BMG (Fig. 26), as the average length of a stricture in those patients who come to surgery is (reported to be) 5 cm [98], although the authors believe this to be an exaggeration, 2 cm is probably more accurate

FIG. 24. The principle of a bulbar anastomotic urethroplasty and the postoperative appearance.



[8]. Intuitively excision and end-to-end anastomosis (Fig. 24) should be best for patients with shorter strictures in whom this is possible because the diseased segment is excised and two healthy ends are joined together. Indeed, current evidence suggests that in the short- to medium-term it is true that anastomotic repairs do better than 'stricturotomy and patch' repairs, although this is debatable [98], but the data are not strictly comparable [101]. Furthermore there is a growing feeling that transecting the urethra, inevitable in anastomotic

urethroplasty as currently performed, may interfere with the blood supply of the corpus

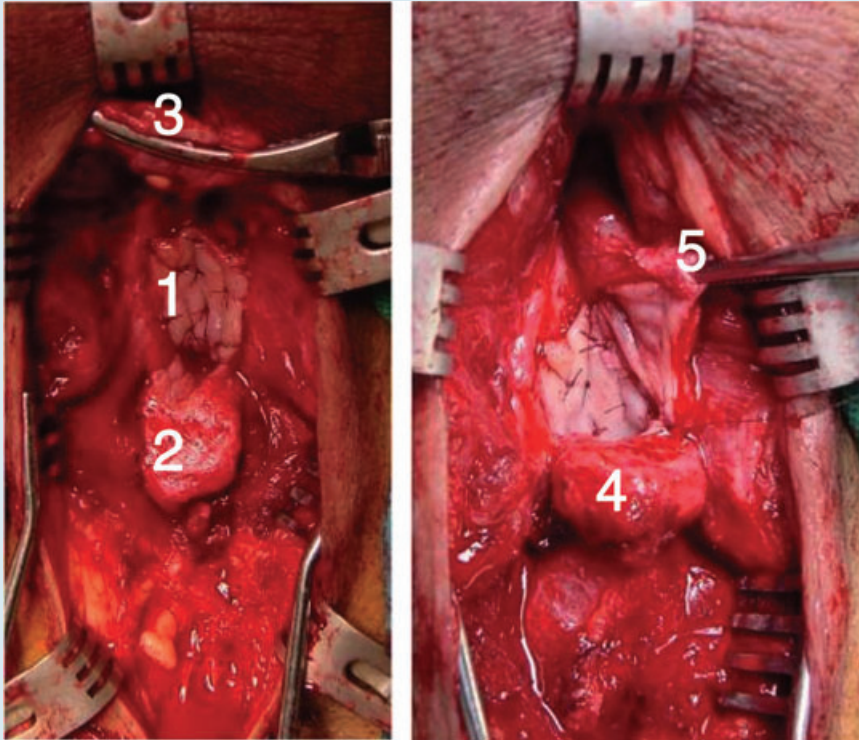
spongiosum such that a non-transecting approach like a 'stricturotomy and patch' or some novel approach to anastomotic repair may be better in the long term [102].

Historical data is important to determine the long-term outcome of urethroplasty but may be misleading because, e.g. strictures tended to be much worse than they are now when a more limited approach is possible in many cases [101]. Further debate today surrounds points of detail such as whether buccal mucosa is any better than labial mucosa or lingual mucosa [103]; or whether dorsal patching is any better than ventral patching [104,105], or indeed, lateral patching [106]. Concentration on these levels of detail attests to the widespread acceptance of the principle of 'stricturotomy and patch' urethroplasty of the bulbar urethra with oral mucosa of one sort or another.

The success rate of bulbar urethroplasty is high. Overall, it is generally reported to be ≈85% [98], although with some contemporary series this is rather better at 95% [107]. But, this is the urologist's view

‘The success rate of bulbar urethroplasty is high’

FIG. 25. The augmented anastomotic repair. The stricture has been excised and both ends spatulated dorsally. A BMG has been harvested and quilted to the tunica albuginea of the penis (1). The proximal spatulated end of the urethra is beginning to be sutured to the proximal end of the BMG (2). The distal spatulated end of the urethra is retracted with a bulldog clamp (3). When the proximal part of the anastomosis is complete (4), the distal half is sutured, shown here half-finished (5).



and not necessarily the patients view. Unfortunately, there is little or no correlation between the criteria used by the urologist and those used by the patient. The urologist concentrates on voiding efficiency. The patient is much more concerned with cosmetic effects and adverse effects on sexual performance [108]. Equally, the criteria that urologists use vary greatly. In general, however sophisticated the diagnostic assessment preoperatively, postoperative success or failure in most publications is based simply on whether or not the patient requires further intervention and even then 'one dilatation' is regarded as perfectly acceptable [98]. However, where studied, the evidence suggests that urethroplasty has no adverse effect on sex drive, erection and ejaculation in the long term although these may take up to a year to recover [109].

PENILE URETHROPLASTY (Fig. 28)

Penile urethral strictures are different. The principles have been outlined above. The

Orandi patch (Fig. 23) for an uncomplicated penile stricture does well. Unfortunately, strictures as a consequence of hypospadias surgery and LS are more common. Each has its problems. LS varies from being a highly aggressive and extensive inflammatory disease of the penis and anterior urethra to being a burnt out condition affecting just the meatus and surrounding glans [40]. Hypospadias-related strictures may also be a simple stenosis of a recessed meatus in an otherwise relatively normal penis. On the other hand, there can be extensive fibrosis after multiple previous procedures, a shallow glans cleft, a small ventrally tilted glans, chordee, an underdeveloped corpus spongiosum and thin ventral shaft skin poorly supported by the subcutaneous tissue and an attenuated dartos layer beneath it, together with the effects of overt trauma from previous surgery [110,111] (Fig. 29). Hypospadias and LS are two separate conditions in their own right;

nonetheless, most hypospadias-related strictures are distal with at least some dartos to support a repair and most LS-related strictures are also distal and the disease 'burnt out', or relatively quiescent. Such patients do well with excision of the fibrotic area, development of an adequate glans cleft, a BMG to recreate the glanular urethra and then a carefully layered closure to minimize the risk of postoperative fistula formation, all in a one-stage procedure. The results in these circumstances are nearly the same as for bulbar urethroplasty. However, for those at the other end of the spectrum a staged procedure will be necessary (Fig. 30) to ensure graft take because one-stage tube grafts do not 'take' well [100]. Even with staged procedures the results are significantly worse than with bulbar urethroplasty and about half of patients having a planned two-stage procedure end up having an interval revision making it a three-stage procedure, albeit with an 85% chance of a durable repair [112]. Indeed, for those at the very far end of the spectrum with extensive, aggressive and active LS it might be better still to leave the stricture altogether alone and do a perineal urethrostomy [71,113], at least as a temporizing measure in the hope that the disease itself will settle down.

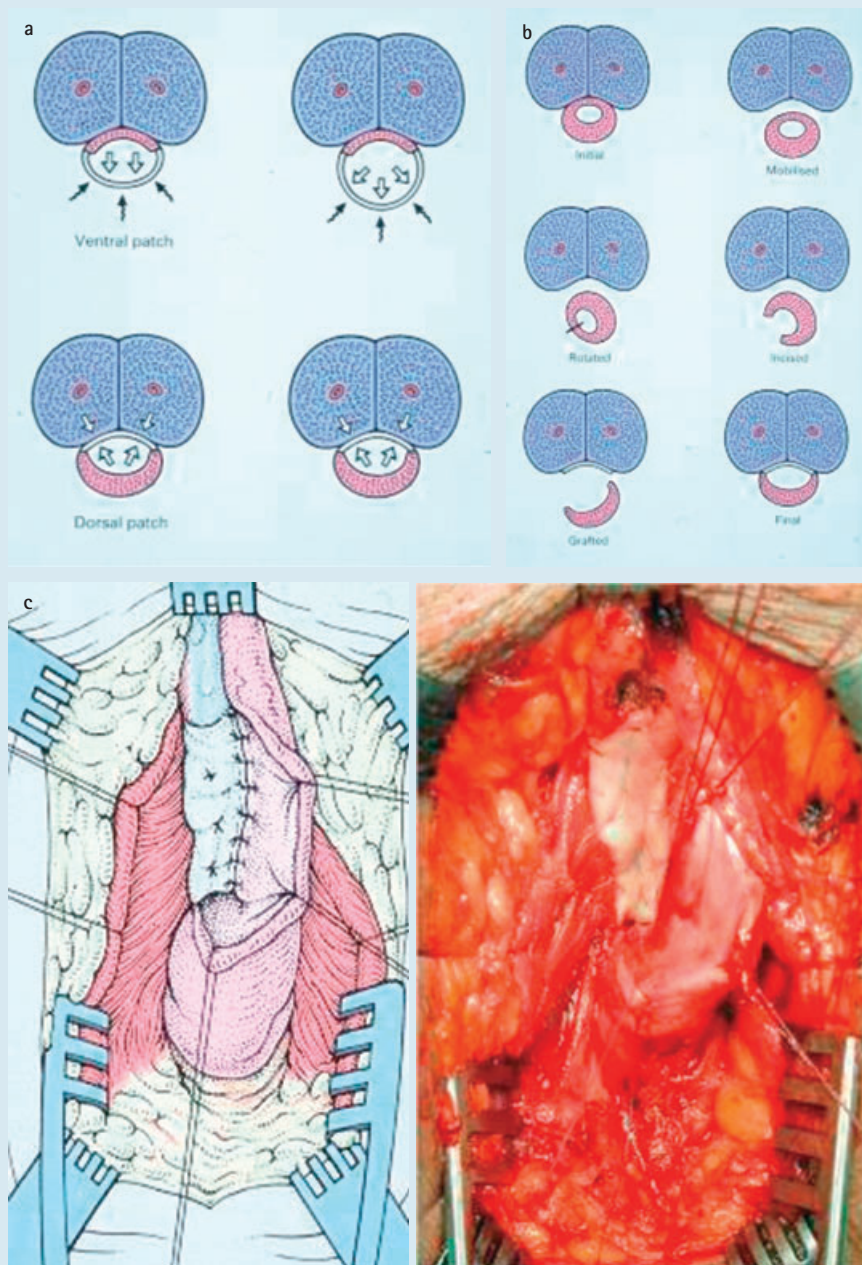
DIFFICULT SITUATIONS

Almost all available data is based on observational studies of patients with a patent urethral lumen, however tight it may be. But some patients have more or less completely obliterative strictures or full-length strictures with more or less obliterative segments, often having had repeated urethrotomies and urethroplasties. Other than 'expert opinion' there is nothing to guide

‘Obliterative strictures do not do well with a
“stricturotomy and patch”’

the surgeon on how to approach these problems [69]. Obliterative strictures do not do well with a 'stricturotomy and patch', in our view, and alternative approaches must be considered. Staged reconstructions come into their own with full-length strictures and with salvage surgery [114] (Fig. 31). Generally speaking, the 'art' of surgery creeps in when the science is lacking, and science is distinctly lacking in revisional stricture surgery.

FIG. 26. The principles of the dorsal 'stricturotomy and patch' procedure: (a) dorsal so that diverticularization of the patch on voiding does not occur; (b) diagrammatic representation of the procedure; and (c) operative appearance and accompanying diagram of the BMG quilted in place before stitching the margins of the urethra to the margins of the graft.



FUTURE PROSPECTS

The results of excision and end-to-end anastomosis for short sharp strictures of the bulbar urethra are better than 95% in expert hands [115]. So good, in fact, that it seems unlikely that they could be bettered by any

other technique. Nonetheless, reference has already been made to the minimalist non-transsecting approach that some surgeons are adopting to these strictures. This seems likely to develop further in the future, together with other ways of minimizing the trauma of surgery [116].

FIG. 27. Flow chart of surgical steps in bulbar urethroplasty for short and long strictures.

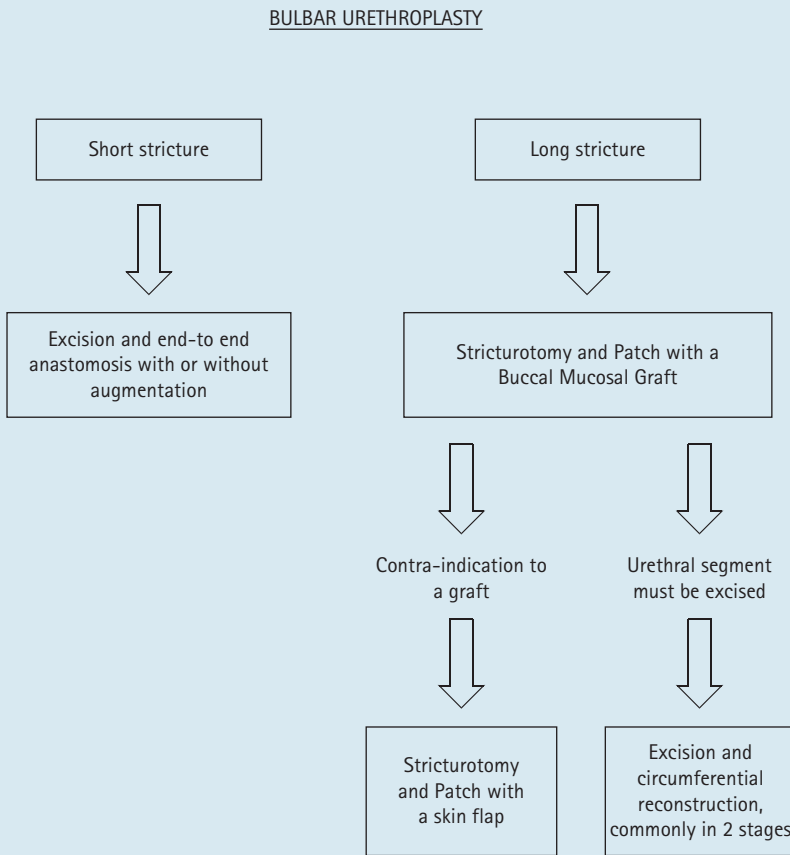
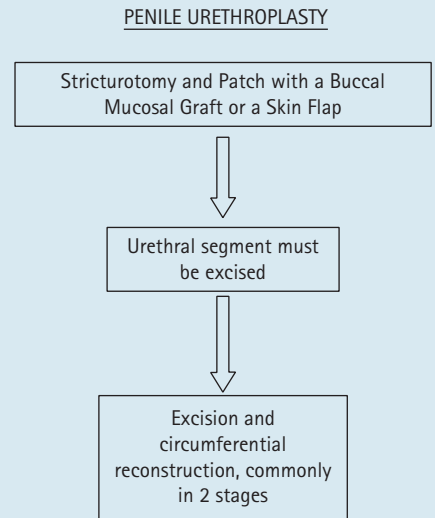


FIG. 29. Hypospadias cripples as a consequence of the trauma of previous surgery.

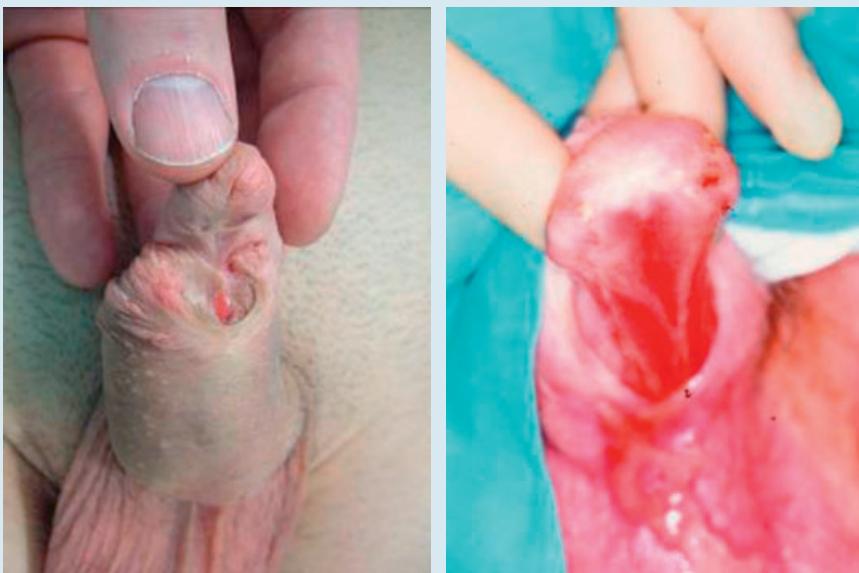

FIG. 28. Flow chart of surgical steps in penile urethroplasty.



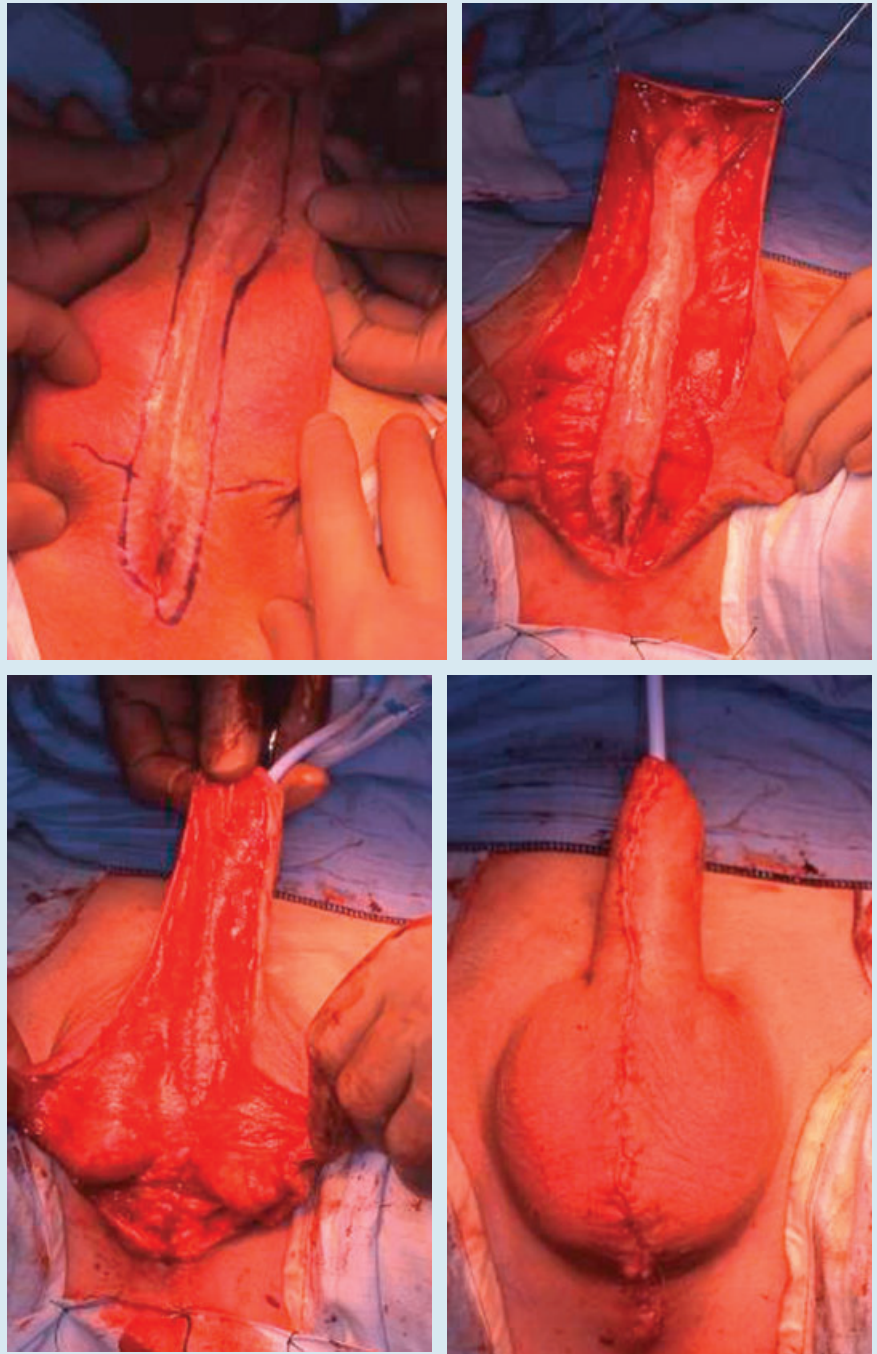
The problem is really with the 'stricturotomy and patch' procedure, the one-stage distal penile urethroplasty for hypospadias and LS-related strictures, and the staged procedures, all of which require a graft. Endourethral grafting after urethrotomy has been tried in the past [117,118] but never did very well in the long term (anecdotally), probably because of the then impossibility of excising the scar tissue rather than incising it. This may become possible in the future. In the meantime, 'off the shelf' BMGs have become a possibility, at least in a laboratory setting, creating the likelihood of manufactured grafts in the future [119,120]. At the moment, these are buccal mucosal constructs and not without their problems, but reliable pseudo-stratified columnar epithelial constructs of urethral origin may become available as technology develops in the future.

What might be better than anything else, at least while these future prospects are being developed, would be some high quality clinical trials of what we are doing currently to make the evidence base stronger. Some stricture problems defy this approach but there are plenty of studies that could be done of the more common surgical procedures and the more common stricture problems. Equally, it is time for occasional urethral surgeons to

FIG. 30. The first stage of a staged repair: the diseased urethra has been excised, a glans cleft created and a BMG quilted in place. At 3 months later, the graft is ready to be rolled up and closed.

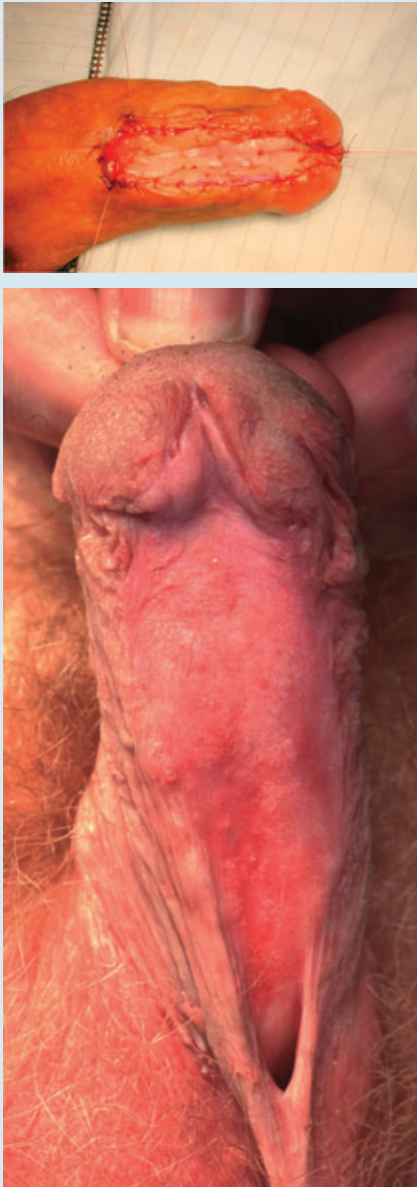

FIG. 31. When all else fails a salvage procedure can be attempted. The remaining native urethra was marsupialized at the first stage. Here a 3-cm wide strip is created and rolled up in layers to form a neo-urethra.



stop 'having a go' and doing urethroplasty just because they like to do it. Urethral surgery is a specialist activity that should be done in specialist centres by surgeons working together in teams to develop further our understanding of these problems and their treatment and therefore achieving better outcomes for our patients [121,122].

GUIDELINES FOR THE MANAGEMENT OF URETHRAL STRICTURES

Diagnosis

1. Consider a stricture as a cause of obstructive lower urinary tract symptoms in a man aged less than 65
2. Get a symptom score completed and a flow rate study at the first visit – ideally with an ultrasound assessment of bladder wall thickness and residual urine
3. If a retrograde urethrogram or a flexible cystoscopy can be done at that same consultation then do so, in that order of preference
4. If the definitive investigation has to be arranged subsequently then arrange a retrograde urethrogram with a voiding cystogram
5. If the bladder ultrasound was abnormal the upper urinary tract structure and renal function should be assessed

Treatment by Instrumentation

6. In the absence of complications treatment is for symptoms not for the results of the flow rate study or imaging
7. DVIU or dilatation are potentially curative in the first time treatment of a short sharp bulbar stricture <1 cm
8. The procedure should be carried out under antibiotic cover and a catheter should be left in for 3 days afterwards
9. A guide-wire should be used for DVIU
10. In the presence of co-morbidities or in a patient who is happy to be palliated, occasional dilatation or DVIU are acceptable. Dilatation is preferable for meatal strictures and sphincter strictures and 'easy' strictures which can be treated in an office setting
11. Self-catheterisation/dilatation may have a role in palliation but is not curative
12. There is no role for stents in cure or palliation

Treatment by Urethroplasty

13. Urethroplasty is the only curative option currently available for the treatment of recurrent bulbar strictures and for all other anterior urethral strictures whether or not they have been treated previously

14. Short strictures of the bulbar urethra may be amenable to excision and end-to-end anastomosis, with or without augmentation
15. Longer strictures of the bulbar urethra are best treated by a stricturotomy and patch procedure, using a buccal mucosal graft in most circumstances
16. Penile strictures of any length require a substitution urethroplasty in one or two stages depending on the length and the nature and severity of the underlying problem and the effects of previous surgery
17. Critical factors in (potentially) staged penile urethroplasty are: an adequate glans cleft; a (buccal mucosal) graft of adequate length and breadth; a layered closure including an adequate dartos layer; and careful haemostasis and infection control
18. Genital skin should not be used for the repair of strictures due to lichen sclerosus
19. Urethroplasty should be carried out in specialist centres

There has recently been an international consultation on urethral stricture disease (in Marrakech) and it is quite likely that a definitive set of guidelines will be produced from this.

CONFLICT OF INTEREST

None declared.

REFERENCES

- 1 **Chapple C, Barbagli G, Jordan G *et al.*** Consensus statement on urethral trauma. *BJU Int* 2004; **93**: 1195–202
- 2 **Das S.** Shusruta of India, the pioneer in the treatment of urethral stricture. *Surg Gynecol Obstet* 1983; **157**: 581–2
- 3 **Arnott J.** *A Treatise on Stricture of the Urethra*. London: Burgess and Hill, 1819
- 4 **UK NHS Reference Costs.** Available at: http://www.dh.gov.uk/en/Publicationsandstatistics/Publications/PublicationsPolicyAndGuidance/DH_111591. Accessed September 2010
- 5 **UK NHS Hospital Episode Statistics.** Available at: <http://www.hesonline.nhs.uk>. Accessed September 2010
- 6 **McMillan A, Pakianathan M, Mao NH, Macintyre CC.** Urethral stricture and urethritis in men in Scotland. *Genitourin Med* 1994; **70**: 403–5
- 7 **Santucci RA, Joyce GF, Wise M.** Male urethral stricture disease. *J Urol* 2007; **177**: 1667–74
- 8 **Beard DE, Goodyear WE.** Urethral stricture; a pathological study. *J Urol* 1948; **59**: 619–26
- 9 **Fenton AS, Morey AF, Aviles R, Garcia CR.** Anterior urethral strictures: etiology and characteristics. *Urology* 2005; **65**: 1055–8
- 10 **Lumen N, Hoebeke P, Willemsen P, De Troyer B, Pieters R, Oosterlink W.** Etiology of urethral stricture disease in the 21st century. *J Urol* 2009; **182**: 983–7
- 11 **Netto NR Jr, Martucci RC, Goncalves ES, Freire JG.** Congenital stricture of male urethra. *Intl Urol Nephrol* 1976; **1**: 55–61
- 12 **Donnellan SM, Costello AJ.** Congenital bulbar strictures occurring in three brothers. *Aust NZ J Surg* 1996; **66**: 423–4
- 13 **Cobb BG, Wolf JA Jr, Ansell JS.** Congenital stricture of the proximal urethral bulb. *J Urol* 1968; **99**: 629–31
- 14 **Moorman JG.** Congenital anomalies of the urethra. *Br J Urol* 1968; **40**: 636–9
- 15 **Palaniswamy R, Bhandari M.** Point of focus: poor genital hygiene and terminal urethral strictures. *Trop Geogr Med* 1983; **35**: 139–43
- 16 **Barbagli G, Perovic S, Djinic R, Sansalone S, Lazzeri M.** Retrospective descriptive analysis of 1176 patients with failed hypospadias repair. *J Urol* 2010; **183**: 207–11
- 17 **Secret CL, Jordan GH, Winslow BH *et al.*** Repair of the complications of hypospadias surgery. *J Urol* 1993; **150**: 1415–8
- 18 **Tang SH, Hammer CC, Doumanian L, Santucci RA.** Adult urethral stricture disease after childhood hypospadias repair. *Adv Urol* 2008; 150315. Epub: Nov 4, 2008
- 19 **McKay DL Jr, Foster F, Weinberg AG.** Balantis xerotica obliterans in children. *J Urol* 1975; **114**: 773–5
- 20 **Mundy AR.** The treatment of sphincter strictures. *Br J Urol* 1989; **64**: 626–8
- 21 **Lentz HC, Mebust WK, Foret JD, Melchior J.** Urethral strictures following

- transurethral prostatectomy: review of 2223 resections. *J Urol* 1977; **117**: 194–6
- 22 **Roehrborn CG**. Standard surgical interventions. In Kirby RS, McConnell J, Fitzpatrick J, Roehrborn C, Boyle P eds, *Textbook of Benign Prostatic Hyperplasia*, Oxford: Isis Medical Media, 1996: 350–77
- 23 **Attwater HL**. Surgery of urethral strictures. *Lancet* 1948; **2**: 14–5
- 24 **Blandy JP**. Urethral stricture. *Postgrad Med J* 1980; **56**: 383–418
- 25 **Kashefi C, Messer K, Barden R, Sexton C, Parsons JK**. Incidence and prevention of iatrogenic urethral injuries. *J Urol* 2008; **179**: 2254–8
- 26 **Nacey JN**. Urinary catheter toxicity. *NZ Med J* 1991; **104**: 355–6
- 27 **Breyer BN, McAninch JW, Whitson JM et al**. Multivariate analysis of risk factors for long-term urethroplasty outcome. *J Urol* 2010; **183**: 613–7
- 28 **Wassermann M, Hakke N**. Urétrite chronique et rétrécissements, nouvelle contribution a l'anatomie pathologique des rétrécissements de l'urèthre. *Ann Des Maladies Des Organes Génito-Urinaires* 1884; **12**: 241–63
- 29 **Scott TM, Foote J**. Early events in stricture formation in the guinea pig urethra. *Urol Int* 1980; **35**: 334–9
- 30 **Meria P, Anidjar M, Brouland JP et al**. An experimental model of bulbar urethral stricture in rabbits using endoscopic radiofrequency coagulation. *Urology* 1999; **53**: 1054–7
- 31 **Singh M, Blandy JP**. The pathology of urethral stricture. *J Urol* 1976; **115**: 673–6
- 32 **Chambers RM, Baitera B**. The anatomy of the urethral stricture. *Br J Urol* 1977; **49**: 545–51
- 33 **Baskin LS, Constantinescu SC, Howard PS et al**. Biochemical characterisation and quantification of the collagenous components of urethral stricture tissue. *J Urol* 1993; **150**: 642–7
- 34 **Cavalcanti AG, Costa WS, Baskin LS, McAninch JA, Sampaio FJB**. A morphometric analysis of bulbar urethral strictures. *BJU Int* 2007; **100**: 397–402
- 35 **Cavalcanti AG, Yucel S, Deng DY, McAninch JW, Baskin LS**. The distribution of neuronal and inducible nitric oxide synthase in urethral stricture formation. *J Urol* 2004; **171**: 1943–7
- 36 **Zhang P, Shi M, Wei Q et al**. Increased expression of connective tissue growth factor in patients with urethral stricture. *Tohoku J Exp Med* 2008; **215**: 199–206
- 37 **Das S, Tunuguntla HS**. Balantis xerotica obliterans – a review. *World J Urol* 2000; **18**: 382–7
- 38 **Mefferts JJ, Davis BM, Grimwood RE**. Lichen sclerosus. *J Am Acad Dermatol* 1995; **32**: 393–416
- 39 **Kaya G, Berset M, Prins C, Chavaz P, Saurat JH**. Chronic borreliosis presenting with morphea and lichen sclerosus et atrophicus-like cutaneous lesions: a case report. *Dermatology* 2001; **202**: 373–5
- 40 **Depasquale I, Park AJ, Bracka A**. The treatment of balantis xerotica obliterans. *BJU Int* 2000; **86**: 459–65
- 41 **Romero Perez P, Mira Llinaries A**. [Complications of the lower urinary tract secondary to urethral stenosis]. *Actas Urol Esp* 1996; **20**: 786–93
- 42 **Thompson H**. *The Pathology and Treatment of Stricture of the Urethra Both in the Male and the Female*. London: John Churchill, 1865
- 43 **Devereux MH, Burfield GD**. Prolonged follow-up of urethral strictures treated by intermittent dilatation. *Br J Urol* 1970; **42**: 321–9
- 44 **Barry MJ, Fowler FJ, O'Leary MP, Bruskevitz RC, Holtgrewe HL, Mebust WK**. Correlation of the American Urological Association symptom index with self-administered versions of the Madsen-Iversen, Boyarsky and Maine Medical Assessment Program symptom indexes. Measurement Committee of the American Urological Association. *J Urol* 1992; **148**: 1558–64
- 45 **Morey AF, McAninch JW, Duckett CP, Rogers RS**. American Urological Association symptom index in the assessment of urethroplasty outcomes. *J Urol* 1998; **159**: 1192–4
- 46 **Heyns CF, Marais DC**. Prospective evaluation of the American Urological Association symptom index and peak urinary flow rate for the followup of men with known urethral stricture disease. *J Urol* 2002; **168**: 2051–4
- 47 **McCallum RW, Colapinto V**. The role of urethrography in urethral disease. Part I. Accurate radiological localization of the membranous urethra and distal sphincters in normal male subjects. *J Urol* 1979; **122**: 607–11
- 48 **Morey AF, McAninch JW**. Role of preoperative sonourethrography in bulbar urethral reconstruction. *J Urol* 1997; **158**: 1376–9
- 49 **Pansadoro V, Emiliozzi P**. Internal urethrotomy in the management of anterior urethral strictures: long term follow-up. *J Urol* 1996; **156**: 73–5
- 50 **Steenkamp JW, Heyns CF, De Kock ML**. Internal urethrotomy versus dilatation as treatment for male urethral strictures: a prospective, randomised comparison. *J Urol* 1997; **157**: 98–101
- 51 **Heyns CF, Steenkamp JW, De Kock ML, Whitaker P**. Treatment of male urethral strictures: is repeated dilation or internal urethrotomy useful? *J Urol* 1998; **160**: 356–8
- 52 **Rourke KF, Jordan GH**. Primary urethral reconstruction: the cost minimised approach to the bulbous urethral stricture. *J Urol* 2005; **173**: 1206–10
- 53 **Sachse H**. Die sichturethrotomie mit scharfem schnitt, indikation – technik – ergebnisse. *Urologie A* 1978; **17**: 177–81
- 54 **Pain JA, St. Collier DG**. Factors influencing recurrence of urethral strictures after endoscopic urethrotomy: the role of infection and peri-operative antibiotics. *Br J Urol* 1984; **56**: 217–9
- 55 **Desmond AD, Evans CM, Jameson RM, Woolfenden KA, Gibbon NO**. Critical evaluation of direct vision urethrotomy by urine flow measurement. *Br J Urol* 1981; **53**: 630–3
- 56 **Naudé AM, Heyns CF**. What is the place of internal urethrotomy in the treatment of urethral stricture disease? *Nat Clin Pract Urol* 2005; **2**: 538–45
- 57 **Lawrence WT, MacDonagh RP**. Treatment of urethral stricture disease by internal urethrotomy followed by 'low friction' self-catheterisation: preliminary report. *J R Soc Med* 1988; **81**: 136–9
- 58 **Harriss DR, Beckingham IJ, Lemberger RJ, Lawrence WT**. Long-term results of intermittent low-friction self-catheterisation in patients with recurrent urethral strictures. *Br J Urol* 1994; **74**: 790–2
- 59 **Greenwell TJ, Castle C, Andrich DE, MacDonald JT, Nicol DL, Mundy AR**. Repeat urethrotomy and dilatation for the treatment of urethral stricture are neither clinically effective nor cost-effective. *J Urol* 2004; **172**: 275–7
- 60 **Matanhelia SS, Slaman R, John A, Matthews PN**. A prospective

- randomised study of self dilatation in the management of urethral strictures. *J R Coll Surg Edinb* 1995; **40**: 295–7
- 61 **Milroy EJ, Chapple CR, Eldin A, Wallsten H.** A new stent for the treatment of urethral strictures. Preliminary report. *Br J Urol* 1989; **63**: 392–6
- 62 **Staios D, Shergill I, Thwani A, Junaid I, Buchholz NP.** The Memokath stent. *Expert Rev Med Devices* 2007; **4**: 99–101
- 63 **Milroy E, Allen A.** Long-term results of UroLume urethral stent for recurrent strictures. *J Urol* 1996; **155**: 904–8
- 64 **Badlani GH, Press SM, Defalco A, Oesterling JE, Smith AD.** UroLume endourethral prosthesis for the treatment of urethral stricture disease: long term results of the North American multicenter UroLume trial. *Urology* 1995; **45**: 846–56
- 65 **De Vocht TF, van Venrooij GE, Boon TA.** Self expanding stent insertion for urethral strictures: a 10-year follow up. *BJU Int* 2003; **91**: 627–30
- 66 **Hussain M, Greenwell TJ, Shah J, Mundy AR.** Long-term results of a self expanding Wallstent in the treatment of urethral stricture. *BJU Int* 2004; **94**: 1037–9
- 67 **Palminteri E.** Stents and urethral strictures: a lesson learned? *Eur Urol* 2008; **54**: 498–500
- 68 **Tammela TL, Talia M.** Biodegradable urethral stents. *BJU Int* 2003; **92**: 843–50
- 69 **Andrich DE, Mundy AR.** What is the best technique for urethroplasty? *Eur Urol* 2008; **54**: 1031–41
- 70 **Wright JL, Wessels H, Nathens AB, Hollingworth W.** What is the most cost-effective treatment for 1 to 2-cm bulbar urethral strictures: societal approach using decision analysis. *Urology* 2006; **67**: 889–93
- 71 **Peterson AC, Palminteri E, Lazzeri M, Guanzoni G, Barbagli G, Webster GD.** Heroic measures may not always be justified in extensive urethral stricture due to lichen sclerosus (balantix xerotica obliterans). *Urology* 2004; **64**: 565–8
- 72 **Wheelhouse CG.** Perineal section, as performed at Leeds. *BMJ* 1876; **1**: 779–80
- 73 **Home E.** *Practical Observations on the Treatment of Strictures in the Urethra.* London: George Nicol, 1795
- 74 **Chopart P.** *Traité des maladies des voies urinaires.* Chez Rémond et fils. Paris: J B Baillière, 1821
- 75 **Bryant T.** *Clinical Surgery on Stricture, Retention of Urine, Stone in the Bladder and Other Diseases of the Urinary Organs,* Part IV. London: John Churchill, 1862
- 76 **Huesner D.** Ueber resection der urethra bei stricturen. *Deutsch Med Wschr* 1883; **9**: 415–6
- 77 **Mayo Robson AW.** Traumatic urethral stricture cured by excision. *BMJ* 1885; **1**: 481–2
- 78 **Hamilton Russell R.** The treatment of urethral stricture by excision. *Br J Surg* 1915; **2**: 375–83
- 79 **Davis JS, Traut HF.** The production of epithelial lined tubes and sacs: an experimental study. *JAMA* 1926; **86**: 339–41
- 80 **Johanson B.** Reconstruction of the male urethra in strictures: application of the buried intact epithelium technic. *Acta Chir Scand Suppl* 1953; **176**: 1–103
- 81 **Browne D.** Hypospadias. *Postgrad Med J* 1949; **25**: 367–72
- 82 **Leadbetter GW Jr.** A simplified urethroplasty for strictures of the bulbous urethra. *J Urol* 1960; **83**: 54–9
- 83 **Leadbetter GW Jr, Leadbetter WF.** Urethral strictures in male children. *J Urol* 1962; **57**: 409–15
- 84 **Orandi A.** One-stage urethroplasty. *Br J Urol* 1968; **40**: 717–9
- 85 **Devine PC, Sakati IA, Poutasse EF, Devine CJ Jr.** One stage urethroplasty: repair of urethral strictures with a free full thickness patch of skin. *J Urol* 1968; **99**: 191–3
- 86 **Devine CJ Jr, Horton CE.** A one stage hypospadias repair. *J Urol* 1961; **69**: 166–72
- 87 **Converse JM, Rapaport FT.** The vascularisation of skin autografts and homografts: an experimental study in man. *Ann Surg* 1956; **143**: 306–15
- 88 **Bürger RA, Müller SC, el-Damanhoury H, Tschakaloff A, Riedmiller H, Hohenfellner R.** The buccal mucosal graft for urethral reconstruction: a preliminary report. *J Urol* 1992; **147**: 662–4
- 89 **Humby G.** A one stage operation for hypospadias. *Br J Surg* 1941; **29**: 84–92
- 90 **Baskin LS, Duckett JW.** Buccal mucosa grafts in hypospadias surgery. *Br J Urol* 1995; **76** (Suppl. 3): 23–30
- 91 **Markiewicz MR, Margarone JE, Barbagli G, Scannapieco FA.** Oral mucosa harvest: an overview of anatomic and biologic considerations. *EAU-EBU Update Series* 2007; **5**: 179–87
- 92 **Hollowell J, Keating MA, Snyder HM III, Duckett JW.** Preservation of the urethral plate in hypospadias repair: extended applications and further experience with the onlay island flap urethroplasty. *J Urol* 1990; **143**: 98–101
- 93 **Quartey JK.** One-stage penile/preputial cutaneous island flap urethroplasty for urethral stricture: a preliminary report. *J Urol* 1983; **129**: 284–7
- 94 **Turner-Warick R.** Urethral stricture surgery. In Mundy AR ed., *Current Operative Surgery – Urology,* London: Bailliere Tindall, 1988: 160–218
- 95 **Mundy AR, Stephenson TP.** Pedicled preputial patch urethroplasty. *Br J Urol* 1988; **61**: 48–52
- 96 **Wessells H, McAninch JW.** Current controversies in anterior urethral stricture repair: free-graft versus pedicled skin-flap reconstruction. *World J Urol* 1998; **16**: 175–80
- 97 **Venn SN, Mundy AR.** Urethroplasty for balantix xerotica obliterans. *Br J Urol* 1998; **81**: 735–7
- 98 **Meeks JJ, Erickson BA, Granieri MA, Gonzalez CM.** Stricture recurrence after urethroplasty: a systematic review. *J Urol* 2009; **182**: 1266–70
- 99 **Asopa HS, Garg M, Singhai GG, Singh L, Asopa J, Nischal A.** Dorsal free graft urethroplasty for urethral stricture by ventral sagittal urethrotomy approach. *Urology* 2001; **58**: 657–9
- 100 **Greenwell TJ, Venn SN, Mundy AR.** Changing practice in anterior urethroplasty. *BJU Int* 1999; **83**: 631–5
- 101 **Andrich DE, Dungleison N, Greenwell TJ, Mundy AR.** The long-term results of urethroplasty. *J Urol* 2003; **170**: 90–2
- 102 **Jordan GH, Eltahawy EA, Virasoro R.** The technique of vessel sparing excision and primary anastomosis for proximal bulbous urethral reconstruction. *J Urol* 2007; **177**: 1799–802
- 103 **Andrich DE, Mundy AR.** Substitution urethroplasty with buccal mucosal-free grafts. *J Urol* 2001; **165**: 1131–4
- 104 **Song LJ, Xu YM, Lazzeri M, Barbagli G.** Lingual mucosal grafts for anterior urethroplasty: a review. *BJU Int* 2009; **104**: 1052–6

- 105 **Dubey D, Vijjan V, Kapoor R et al.** Dorsal onlay buccal mucosa versus penile skin flap urethroplasty for anterior urethral strictures: results from a randomised prospective trial. *J Urol* 2007; **178**: 2466–9
- 106 **Barbagli G, Palminteri E, Guazzoni G, Montorsi F, Turini D, Lazzeri M.** Bulbar urethroplasty using buccal mucosal grafts placed on the ventral, dorsal or lateral surface of the urethra: are results affected by the surgical technique. *J Urol* 2005; **174**: 955–8
- 107 **Andrich DE, Leach CJ, Mundy AR.** The Barbagli procedure gives the best results for patch urethroplasty of the bulbar urethra. *BJU Int* 2001; **88**: 385–9
- 108 **Kessler TM, Fisch M, Heitz M, Ollanas R, Schreiter F.** Patient satisfaction with the outcome of surgery for urethral stricture. *J Urol* 2002; **167**: 2507–11
- 109 **Erickson BA, Wysock JS, McVary KT, Gonzalez CM.** Erectile function, sexual drive, and ejaculatory function after reconstructive surgery for anterior urethral stricture disease. *BJU Int* 2006; **99**: 607–11
- 110 **Barbagli G, De Angelis M, Palminteri E, Lazzeri M.** Failed hypospadias repair presenting in adults. *Eur Urol* 2006; **49**: 887–95
- 111 **Mundy AR.** Failed hypospadias repair presenting in adults. *Eur Urol* 2006; **49**: 774–6
- 112 **Andrich DE, Greenwell TJ, Mundy AR.** The problems of penile urethroplasty with particular reference to 2-stage reconstructions. *J Urol* 2003; **170**: 87–9
- 113 **Barbagli G, De Angelis M, Romano G, Lazzeri M.** Clinical outcome and quality of life assessment in patients treated with perineal urethrostomy for anterior urethral stricture disease. *J Urol* 2009; **182**: 548–57
- 114 **Al-Ali M, Al-Hajaj R.** Johanson's staged urethroplasty revisited in the salvage treatment of 68 complex urethral stricture patients: presentation of total urethroplasty. *Eur Urol* 2001; **39**: 288–71
- 115 **Eltahawy EA, Virasoro R, Schlossberg SM, McCammon KA, Jordan GH.** Long-term followup for excision and primary anastomosis for anterior urethral strictures. *J Urol* 2007; **177**: 1803–6
- 116 **Barbagli G, De Stefan S, Annino F, De Carne C, Bianchi G.** Muscle- and nerve-sparing bulbar urethroplasty: a new technique. *Eur Urol* 2008; **54**: 335–43
- 117 **Pettersson S, Asklin B, Bratt CC.** Endourethral urethroplasty: a simple method for treatment of urethral strictures by internal urethrotomy and primary split skin grafting. *Br J Urol* 1978; **50**: 257–61
- 118 **Naudé JH.** Endoscopic skin-graft urethroplasty. *World J Urol* 1998; **16**: 171–4
- 119 **Bhargava S, Chapple CR, Bullock AJ, Layton C, MacNeil S.** Tissue-engineered buccal mucosa for substitution urethroplasty. *BJU Int* 2004; **93**: 807–11
- 120 **Sievert KD, Amend B, Stenzl A.** Tissue engineering for the lower urinary tract: a review of a state of the art approach. *Eur Urol* 2007; **52**: 1580–9
- 121 **Santucci RA.** Should we centralize referrals for repair of urethral strictures? *J Urol* 2009; **182**: 1259–60
- 122 **Andrich DE, Mundy ARA.** Fellowship programme in reconstructive urological surgery: what is it and what is it for? *BJU Int* 2010; **106**: 108–11

Correspondence: Anthony R. Mundy, Institute of Urology, UCLH – Urology, 2nd Floor Central 250 Euston Road Trust Headquarters, University College London Hospitals NHS Foundation Trust, London NW1 2PG, UK. e-mail: kelly.higgs@uclh.nhs.uk

Abbreviations: BMG, buccal mucosal graft; DVIU, direct vision internal urethrotomy; LS, lichen sclerosus.