

Hypogonadotropic Hypogonadism Revisited

Renato Fraietta,¹ Daniel Suslik Zylberstejn,¹ Sandro C. Esteves¹

¹Division of Urology, Department of Surgery, Federal University of São Paulo (UNIFESP), São Paulo/SP, Brazil. ¹¹ANDROFERT – Andrology & Human Reproduction Clinic, Campinas, São Paulo/SP, Brazil.

Impaired testicular function, i.e., hypogonadism, can result from a primary testicular disorder (hypergonadotropic) or occur secondary to hypothalamic-pituitary dysfunction (hypogonadotropic).

Hypogonadotropic hypogonadism can be congenital or acquired. Congenital hypogonadotropic hypogonadism is divided into anosmic hypogonadotropic hypogonadism (Kallmann syndrome) and congenital normosmic isolated hypogonadotropic hypogonadism (idiopathic hypogonadotropic hypogonadism). The incidence of congenital hypogonadotropic hypogonadism is approximately 1-10:100,000 live births, and approximately 2/3 and 1/3 of cases are caused by Kallmann syndrome (KS) and idiopathic hypogonadotropic hypogonadism, respectively.

Acquired hypogonadotropic hypogonadism can be caused by drugs, infiltrative or infectious pituitary lesions, hyperprolactinemia, encephalic trauma, pituitary/brain radiation, exhausting exercise, abusive alcohol or illicit drug intake, and systemic diseases such as hemochromatosis, sarcoidosis and histiocytosis X.

The clinical characteristics of hypogonadotropic hypogonadism are androgen deficiency and a lack/delay/stop of pubertal sexual maturation. Low blood testosterone levels and low pituitary hormone levels confirm the hypogonadotropic hypogonadism diagnosis. A prolonged stimulated intravenous GnRH test can be useful. In Kallmann syndrome, cerebral MRI can show an anomalous morphology or even absence of the olfactory bulb. Therapy for hypogonadotropic hypogonadism depends on the patient's desire for future fertility. Hormone replacement with testosterone is the classic treatment for hypogonadism. Androgen replacement is indicated for men who already have children or have no desire to induce pregnancy, and testosterone therapy is used to reverse the symptoms and signs of hypogonadism. Conversely, GnRH or gonadotropin therapies are the best options for men wishing to have children. Hypogonadotropic hypogonadism is one of the rare conditions in which specific medical treatment can reverse infertility.

When an unassisted pregnancy is not achieved, assisted reproductive techniques ranging from intrauterine insemination to in vitro fertilization to the acquisition of viable sperm from the ejaculate or directly from the testes through testicular sperm extraction or testicular microdissection can also be used, depending on the woman's potential for pregnancy and the quality and quantity of the sperm.

KEYWORDS: Male Infertility; Hypogonadism; Endocrine System Abnormalities; Azoospermia; Review.

Fraietta R, Zylberstejn DS, Esteves SC. Hypogonadotropic Hypogonadism Revisited. Clinics. 2013;68(S1):81-88.

Received for publication on June 20, 2012; Accepted for publication on June 25, 2012

E-mail: fraietta@uol.com.br

Tel.: 55 11 55764488

INTRODUCTION

The hypothalamus, the pituitary, and the testes form an integrated system that is responsible for the adequate secretion of male hormones and normal spermatogenesis. The endocrine components of the male reproductive system are integrated in a classic endocrine feedback loop. The testes require stimulation by the pituitary gonadotropins, i.e., luteinizing hormone (LH) and follicle-stimulating hormone (FSH), which are secreted in response to hypothalamic

gonadotropin releasing hormone (GnRH). The effect of LH and FSH on germ cell development is mediated by the androgen and FSH receptors that are present on Leydig and Sertoli cells, respectively. Whereas FSH acts directly on the germinal epithelium, LH stimulates the secretion of testosterone by Leydig cells. Testosterone stimulates sperm production and virilization, in addition to providing feedback to the hypothalamus and pituitary to regulate GnRH secretion. FSH stimulates Sertoli cells to support spermatogenesis and secrete inhibin B, which negatively regulates FSH secretion. The GnRH pulse generator is the main regulator of puberty, and the production of GnRH starts early in fetal life. As a result, gonadotropin levels change drastically during fetal development, childhood, puberty and adulthood. Male infants exhibit what is called a "window period" during the first six months of life, during which gonadal function can be clinically detected in response to gonadotropin stimulation. After that period, serum gonadotropin levels drop and can only be detected again with the onset of puberty (1).

Copyright © 2013 CLINICS – This is an Open Access article distributed under the terms of the Creative Commons Attribution Non-Commercial License (<http://creativecommons.org/licenses/by-nc/3.0/>) which permits unrestricted non-commercial use, distribution, and reproduction in any medium, provided the original work is properly cited.

No potential conflict of interest was reported.

DOI: 10.6061/clinics/2013(Sup01)09

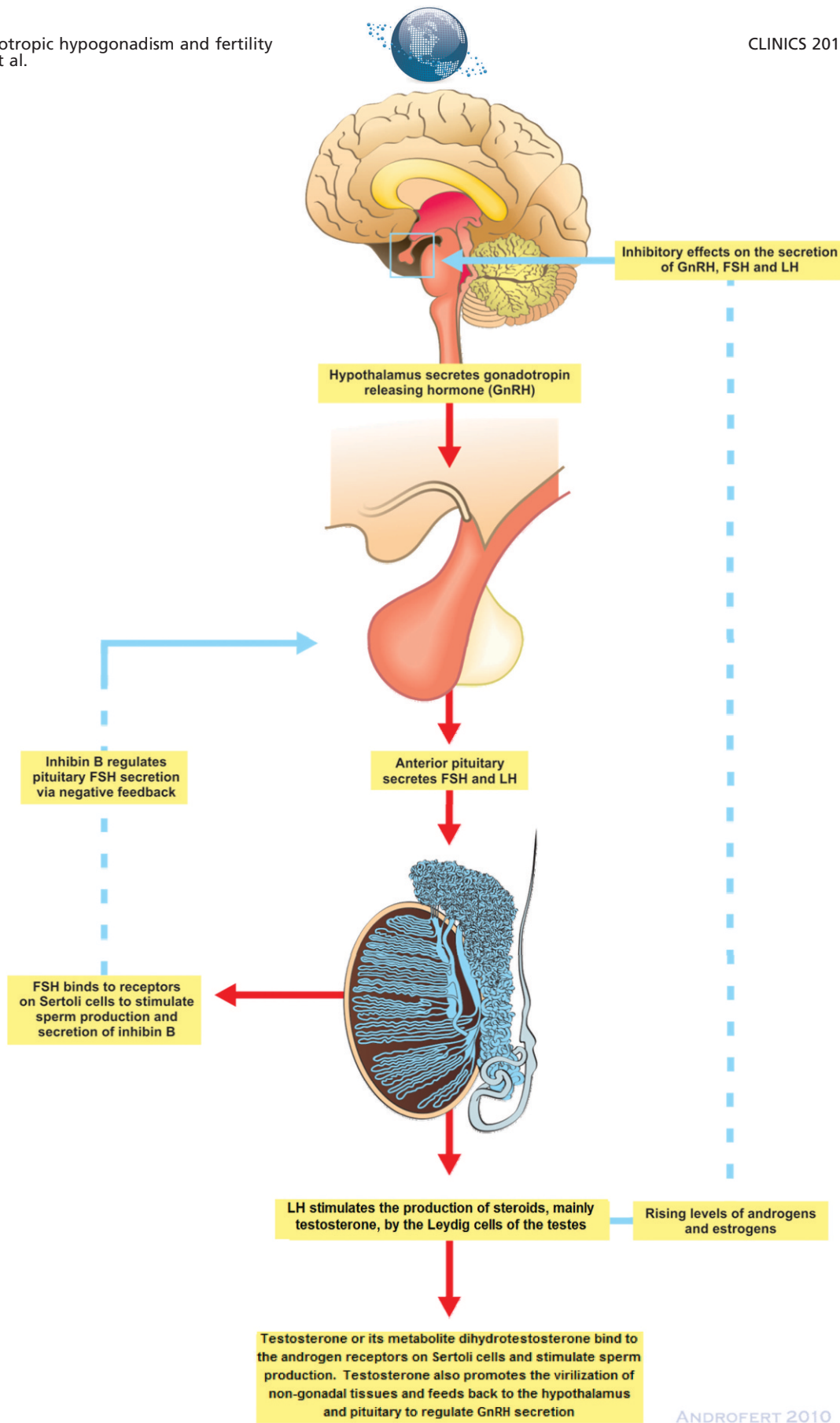


Figure 1 - A schematic representation of the components of the hypothalamic-pituitary-testicular axis and the endocrine regulation of spermatogenesis. Luteinizing hormone (LH) and follicle-stimulating hormone (FSH) are secreted by the pituitary in response to hypothalamic gonadotropin releasing hormone (GnRH). Whereas FSH acts directly on the germinal epithelium, LH stimulates the secretion of testosterone from Leydig cells. Testosterone stimulates sperm production and also feeds back to the hypothalamus and pituitary to regulate GnRH secretion. FSH stimulates Sertoli cells to support spermatogenesis and secrete inhibin B, which negatively regulates FSH secretion.



This paper aims to review the causes of hypogonadotropic hypogonadism, the implications of this condition depending on the period in which it occurs and the different types of treatment available.

■ DEFINITIONS AND PREVALENCE

Male hypogonadism is characterized by impaired testicular function, which can affect spermatogenesis and/or testosterone synthesis. Although it is a common endocrine disorder, the exact prevalence of this disease is unknown.

Male hypogonadism can result from a primary testicular disorder or occur secondary to hypothalamic-pituitary dysfunction.

Hypergonadotropic hypogonadism is also known as primary hypogonadism and is the most frequent form of hypogonadism found in adult men. The Massachusetts Male Aging Study (MMAS) reported a crude incidence rate of 12.3 cases per 1,000 individuals per year, leading to an estimated prevalence of 481,000 new cases of late-onset hypogonadism (LOH) per year in American men 40 to 69 years of age (2).

The symptoms of this disorder can include decreased libido, impaired erectile function, muscle weakness, increased adiposity, depressed mood, and decreased vitality. Primary hypogonadism is characterized by low testosterone production and elevated levels of follicle-stimulating hormone (FSH) and luteinizing hormone (LH) (3). Klinefelter's syndrome is the most common congenital manifestation of primary hypogonadism and affects approximately one in every 500 men. The acquired forms of hypergonadotropic hypogonadism include male aging, which affects approximately 4.1% of men between the ages of 40-49 years and 9.3% of men between the ages of 60-70 years, and exposure to gonadotoxic agents such as those used in chemotherapy and radiotherapy treatments. The latter agents cause gonadal failure by adversely impacting Leydig and Sertoli cell function (4).

In contrast to primary hypogonadism, male hypogonadotropic hypogonadism (HH) is a consequence of congenital or acquired diseases that affect the hypothalamus and/or the pituitary gland (3). In HH, secretion of gonadotropin releasing hormone (GnRH) is absent or inadequate. Isolated lack of production or inadequate biosynthesis of pituitary gonadotropins may also result in HH (5). The prevalence of this form of hypogonadism has been estimated to range from 1:10,000 to 1:86,000 individuals (6).

■ ETIOLOGY

HH can be congenital or acquired. Congenital HH is divided in two main subdivisions depending on the presence of an intact sense of smell: anosmic HH (Kallmann syndrome) and congenital normosmic isolated hypogonadotropic hypogonadism (idiopathic HH [IHH]). The incidence of congenital HH is approximately 1-10:100,000 live births, with approximately 2/3 and 1/3 of cases arising from Kallmann syndrome (KS) and idiopathic HH, respectively (7).

Congenital HH can have a genetic origin. The KAL1 gene has been linked to KS and is the best-characterized gene related to GnRH deficiency (6). This gene has been mapped to X-chromosome region Xp22.32 and consists of 14 exons. KAL1 encodes the protein anosmin-1, which has a length of 840 amino acids and is an extracellular adhesion protein

that plays a possible role in orchestrating GnRH neuron adhesion and axonal migration. Most KAL-1 mutations are nucleotide insertions or deletions that result in frame shift mutations or a premature stop codon. Mutations in this gene lead to a GnRH migration and olfactory neuron disorder (8). The failure of GnRH neurons to migrate from the olfactory placode to their destination in the hypothalamus and olfactory lobe represents the basic embryological defect of this syndrome. The KAL-1 gene accounts for the X-linked recessive mode of inheritance of familial KS and 10-20% of all KS cases. The FGR1, GNRHR, NELF, GPRS54, PROK-2, PROKR-2, CHD-7 and FGF-8 genes have also been linked to this syndrome. These genes can act alone or in combination, and mutations in all of these genes lead to impaired GnRH production (9). Some genetic diseases, such as Prader-Willi syndrome, Laurence-Moon-Biedl syndrome, and Moebius syndrome, are also related to HH (6).

IHH is characterized by low levels of gonadotropins and sex steroids in the absence of anatomical or functional abnormalities of the hypothalamic-pituitary-gonadal axis. The pathogenetic mechanism of IHH involves the failure of GnRH neurons in the hypothalamus to differentiate or develop, which results in a lack of GnRH secretion or pulsatile GnRH secretion.

Acquired hypogonadotropic hypogonadism can be caused by drugs (e.g., sex steroids and gonadotropin-releasing hormone analogues), infiltrative or infectious pituitary lesions, hyperprolactinemia, encephalic trauma, pituitary/brain radiation, exhausting exercise, and abusive alcohol or illicit drug intake (3). Systemic diseases such as hemochromatosis, sarcoidosis and histiocytosis X are also associated with HH (6). The major causes of HH are listed in Table 1 (3).

■ THE ROLE OF GONADOTROPIN RELEASING HORMONE (GNRH) IN THE PHYSIOLOGICAL REGULATION OF THE HYPOTHALAMIC-PITUITARY-GONADAL AXIS

GnRH is a decapeptide that is synthesized by a loose network of neurons located in the medial basal hypothalamus (MBH) and the arcuate nucleus of the hypothalamus. Some GnRH neurons are found outside the hypothalamus in the olfactory lobe, reflecting their common embryological origin. Developmentally, GnRH neurons originate from the olfactory placode/vomer nasal organ of the olfactory system and migrate along the vomeronasal nerves to the

Table 1 - Etiologies of Hypogonadotropic Hypogonadism (3).

Hyperprolactinemia
Pituitary lesions (tumor, granuloma, abscess)
Cushing syndrome
Drug use (opiates, alcohol abuse)
Anabolic steroids use
Severe or chronic illness
Pituitary irradiation, trauma or surgery
Iron overload
Kallmann syndrome
Idiopathic hypogonadotropic hypogonadism
Other genetic mutations
Prader Willi syndrome

Modified from Darby E, Anawalt BD. Male hypogonadism: an update on diagnosis and treatment. *Treat Endocrinol.* 2005;4(5):293-309.



hypothalamus, where they extend processes to the median eminence and pituitary gland. GnRH is synthesized as a precursor hormone that contains 92 amino acids and is then cleaved to a prohormone with a length of 69 amino acids. The prohormone is further cleaved in the nerve terminals to form the active decapeptide. GnRH activation is achieved when specific receptors (i.e., the KiSS1-derived peptide receptor, also known as GPR54 or the kisspeptin receptor) are occupied by kisspeptin protein, which is also produced in the hypothalamus.

Androgens (testosterone and dihydrotestosterone) and estrogens exert negative feedback by activating specific receptors that are located on the kisspeptin-secreting neurons of the arcuate nucleus. Other substances also influence GnRH secretion. Noradrenaline and leptin have stimulatory effects, whereas prolactin, dopamine, serotonin, gamma-aminobutyric acid (GABA) and interleukin-1 are inhibitory (10).

GnRH has a pulsatile secretion and a half-life of approximately 10 minutes, and it is secreted into the hypothalamic-hypophyseal portal blood system, which carries it to the pituitary gland (11). Once secreted, GnRH binds to specific pituitary cell membrane receptors, which results in the production of diacylglycerol and inositol triphosphate, intracellular calcium increase (by mobilization from intracellular stores and extracellular influx) and the activation of protein kinase C. As a consequence, gonadotropins (luteinizing hormone [LH] and follicle-stimulating hormone [FSH]) are released by exocytosis. The GnRH-receptor complex undergoes intracellular degradation; thus, the cell requires some time to replace the receptors, which is reflected by the 60-90 minute interval between GnRH pulses (12).

The essential function of GnRH is to stimulate the secretion of LH and FSH from the anterior pituitary gland (Figure 1). LH and FSH are glycoproteins consisting of alpha and beta polypeptide chains (α and β subunits). They have identical alpha subunits but differ in their beta subunit which determines receptor-binding specificity. Once synthesized, LH and FSH are stored in granules in the pituitary gland. GnRH induces exocytosis of the granules and the release of these hormones into the circulation. A low GnRH pulse frequency tends to preferentially release FSH, whereas higher frequencies are associated with preferential secretion of LH (13). Sialylation allows FSH to have a longer (2 hours) half-life than LH (20 minutes). FSH and LH target specific membrane receptors whose internalization produces cAMP and protein kinase A. LH initiates male pubertal development by binding to LH receptors on Leydig cells, thereby stimulating the release of testosterone. Sertoli cells have receptors for FSH and testosterone. It is therefore believed that both FSH and testosterone support the initiation of spermatogenesis and that both are necessary for the maintenance of quantitatively normal spermatogenesis. Testosterone or its metabolite dihydrotestosterone binds to androgen receptors on Sertoli cells and then modulates gene transcription. Functional Sertoli cell androgen receptors are required for normal spermatogenesis. Intratesticular testosterone levels are ~50 times higher than serum testosterone levels; therefore, it has been suggested that the androgen receptors in the normal testis are fully saturated (14). FSH, in contrast, binds to FSH receptors on Sertoli cells and initiates signal transduction events that ultimately lead to the production of inhibin B, which is a

marker of Sertoli cell activity. Inhibin B and testosterone in turn regulate pituitary FSH secretion (Figure 1). FSH receptors are expressed in the regions of the seminiferous tubules that are involved in the proliferation of spermatogonia. The dual hormonal dependence of normal spermatogenesis can be appreciated in males with hypogonadotropic hypogonadism. Sperm production is restored to approximately 50% of the normal level with either FSH or hCG (as a surrogate for LH) alone; only the combination of hCG plus FSH leads to full quantitative restoration (15).

It has been suggested that testicular function is also regulated by other factors. For instance, Sertoli cells are influenced by factors secreted by the germ cells. Estrogen receptors are found in the efferent ducts, Sertoli cells and most germ cell types. The testes are a major site of estrogen production; however, direct evidence for a role of estrogen in spermatogenesis has not yet been identified. The thyroid hormone receptor is important for Sertoli cell development (16).

■ DIAGNOSIS

Clinical

The clinical characteristics of HH are androgen deficiency and a lack/delay/stop in pubertal sexual maturation. Moreover, hypogonadotropic hypogonadism is considered idiopathic (IHH) when there is an isolated GnRH secretion deficiency in individuals over 18 years of age. Below that age, HH is more properly defined as pubertal delay (1,5). It is important to consider that the first endocrinological change to occur during puberty is an increase in LH, which initially occurs more in amplitude than in frequency and only at night; subsequently, both LH and FSH levels increase at night and during the day until adult levels are reached. It is difficult to differentiate between HH and delayed puberty, as low gonadotropin and testosterone levels are found in both conditions. Therefore, a definitive HH diagnosis must be confirmed only after the patient is 18 years of age (1,17). When the symptoms are associated with anosmia or hyposmia without findings such as harelip and cleft palate, neuro-sensorial deafness, cerebellar ataxia and renal agenesis, a diagnosis of Kallmann syndrome should be confirmed.

The appearance of clinical characteristics depends on when HH begins. When GnRH deficiency occurs in the late fetal or early neonatal periods and is caused by a lack of the first intrinsic GnRH peak, which lasts until six months of age, the incidence of cryptorchidism and/or micro penis is high (5). Men presenting with HH that started in the pre-pubertal phase and was triggered by the intrinsic second GnRH peak exhibit eunuchoid body proportions, a delay in the development of secondary sexual characteristics, a high-pitched voice, pre-pubertal testicles, and delayed bone maturation. Men with an initially delayed HH condition present with diminished libido, considerable weight gain, sexual impotence, hot flashes, and infertility. Infertility is one of the most frequent complaints among these patients and has a negative effect on their quality of life (3,6). Table 2 shows the most prevalent symptoms of pre- and post-pubertal hypogonadism (3).

Laboratory and Imaging

Every hypogonadism diagnosis must start with a confirmation of low blood testosterone levels, preferably the free testosterone level, which is based on the total

**Table 2 - Signs and symptoms of pre- and pos-pubertal hypogonadism (3).**

Pre-pubertal hypogonadism	Post-pubertal hypogonadism
Eunuchoidal stature	Normal stature
Small testes (usually <6cm ³)	Testes volume normal to slightly low (>10cm ³); soft
Small penis (<5cm)	Penis normal size
Lack of normal scrotal rugae and pigmentation	Normal scrotal rugae and pigmentation
Small prostate	Normal prostate
Scant facial, axillary and pubic hair	Thinning of facial, axillary and pubic hair
High pitched voice	Normal voice
Gynecomastia	Gynecomastia
Infertility	Infertility
Lack of libido	Loss of libido
Low bone mineral density	Low bone mineral density
Low muscle mass, high percentage of body fat	Low muscle mass, high percentage of body fat
Mild anemia	Mild anemia
	Hot flashes
	Lack of male pattern baldness
	Decrease sense of well-being
	Erectile dysfunction

Modified from Darby E, Anawalt BD. Male hypogonadism: an update on diagnosis and treatment. *Treat Endocrinol.* 2005;4(5):293-309.

testosterone level, albumin level and SHBG level (sexual hormone-binding globulin). The free and bioavailable testosterone level can be calculated from the total testosterone and SHBG levels (<http://www.issam.ch/freetesto.htm>). These laboratory tests should preferably be performed before 10 am to account for the circadian rhythm of male hormones. If testosterone levels are low, a new test must be performed because of high physiological variations. When low testosterone levels are found, the gonadotropin (FSH and LH) levels must be analyzed. A low pituitary hormone level confirms the HH diagnosis (3,5).

HH is characterized as an isolated secretion disorder. However, some of these releasing gonadotropin hormone characteristics make direct laboratory tests impossible, as GnRH is confined within the pituitary portal system and exhibits a short half-life of 2 to 4 minutes. Therefore, GnRH levels are better checked by indirect measures such as the total or partial absence of LH pulses, the regularization of pituitary and gonadal function, a response to exogenous GnRH replacement and hormonal reserve tests, which check the integrity of the hypothalamic-pituitary system's control mechanism.

A prolonged stimulated intravenous GnRH test (100 mcg followed by 500 mcg) can be useful: in hypothalamic GnRH deficiency, LH and FSH gradually appear, whereas hyporesponsiveness occurs in the pituitary cases (5). It is important to note that the diagnosis can only be concluded after magnetic resonance imaging (MRI) is used for pituitary, prolactinoma, and craniopharyngioma tumor exclusion tests (1,6). In Kallmann syndrome, cerebral MRI can show anomalous morphology or the absence of the olfactory bulb, and it therefore plays a pivotal role in presumptive diagnoses.

■ THERAPEUTIC MANAGEMENT

The therapy for HH depends on the patient's desire for future fertility. Normal androgen levels and the subsequent development of secondary sex characteristics (in cases where the onset of hypogonadism occurred before puberty) and a eugonadal state can be achieved by androgen replacement alone. Hormone replacement with testosterone is the classic treatment for hypogonadism. Androgen

replacement is indicated for men who already have children or have no desire for children, and testosterone therapy is used to reverse the symptoms and signs of hypogonadism. The presence of androgens has been linked to a good sexual life, with preserved libido and erections. The preservation of muscular strength and lean body mass are related to androgens, as is bone hemostasis, which prevents osteoporosis. Improvements in humor and well-being are generally the first clinical signs mentioned by patients who begin hormone replacement.

Conversely, GnRH or gonadotropin therapies are the best options for men who wish to have children. In such cases, the stimulation of sperm production requires treatment with human chorionic gonadotropin (hCG) alone or combined with recombinant FSH, urinary FSH or human menopausal gonadotropins (hMG). In the rare cases of 'fertile eunuchs', who produce sufficient FSH but not LH, treatment with hCG alone may be sufficient to stimulate sperm production and achieve normal testosterone levels (18).

Treatment for Infertility in Hypogonadotropic Hypogonadism

Most hypogonadal young men want to be fertile. Thus, it is important to remember that the fertility of men with hypogonadotropic hypogonadism is only reduced and that fertility may be restored through hormone therapy. Men who present with hypergonadotropic hypogonadism do not respond to hormone medication because the disorder is caused by primary testicular failure (3,4). In contrast, in secondary hypogonadism, the Sertoli cells are deprived of the stimulus necessary for spermatogenesis. Nevertheless, it is important to remember that high intra-testicular testosterone levels are necessary for spermatogenesis (4).

The fertility of patients with HH can be restored through the use of GnRH when cases have a hypothalamic origin or, more commonly, with the use of gonadotropins. Various gonadotropins, either urinary or recombinant, are presently available. The urinary gonadotropin forms are produced from the urine of menopausal women and include human menopause gonadotropin (hMG), which contains urinary FSH and LH. Another commonly used urinary gonadotropin is highly purified urinary FSH (3,4,6).



Regardless of the hormone used for treatment, the total number of sperm usually remains below the normal threshold. This finding does not eliminate the potential for these patients to become fathers, and impregnation rates can reach 50 to 80% with a sperm concentration of 5 million per mL (4,5). The predictors of treatment success are described as an increased baseline testicular volume, no history of cryptorchidism, a history of sexual maturation, and no previous testosterone replacement therapy (5). Even individuals with a testicular volume of 3 mL can benefit from treatment, although these patients may need two years of hormonal therapy before spermatogenesis is triggered (4,5).

Because a long period is necessary to restore spermatogenesis, it is advised that every man who aims to become a father start treatment 6 to 12 months before attempting to conceive (4,5).

GnRH pump treatment:

A portable infusion pump administers pulses of GnRH into the subcutaneous tissue of the abdominal wall every 2 hours, with doses ranging from 100 to 400 ng/kg. This treatment lasts approximately four months and is usually shorter than gonadotropin therapy. However, GnRH usage is restricted to specialized tertiary hospitals and has a high cost, in addition to interfering with the patient's everyday life (4,5).

Gonadotropin treatment:

This treatment can be administered in all cases of secondary hypogonadism and is compulsory in cases with pituitary lesions or a defective GnRH receptor. The β -chains of LH and hCG are very similar and exhibit similar properties, such as affinity for receptors on Leydig cells. Currently, urinary gonadotropins are highly purified and can be injected subcutaneously, which avoids the induction of antibodies against the medication (4,5).

Gonadotropic treatment starts with the administration of 1,000 to 2,500 international units (IU) of isolated hCG twice a week for 8 to 12 weeks. This initial phase is the induction phase, which is crucial for allowing testosterone levels to increase. In certain cases, hCG alone can induce spermatogenesis. In individuals who do not have sufficient endogenous FSH, treatment can continue with the co-administration of 75 to 150 IU hMG three times per week for up to 18 months, as the presence of FSH is crucial for stimulating spermatogenesis. Recombinant FSH can be used in place of hMG, with patients receiving 150 IU three times per week for the same period of time. This combined treatment provides considerable testicular growth in most patients, in addition to spermatogenesis in up to 90% of patients (4,5).

These treatments demand rigid discipline and perseverance because of their duration. Financial support is also necessary because the medication utilized is expensive.

Reproductive outcomes after treatment for infertility in HH

Treatment with gonadotropins has been shown to be effective in males affected by hypogonadotropic hypogonadism, but the final response to hormonal treatment varies widely from patient to patient (19,20). Spontaneous conception can be achieved within 6-9 months after beginning gonadotropin treatment but can require up to two years

(21). Therefore, if a spontaneous pregnancy does not occur after 20 months (or eight months after achieving a sperm concentration of 5×10^6 /mL) assisted reproductive technologies may be considered to achieve pregnancy (22).

Intrauterine insemination (IUI) is a good option for men who have achieved good spermatogenesis (a sperm concentration higher than 5×10^6 /mL) with hormone therapy but failed to impregnate their partner. In these cases, hysterosalpingography should be performed on the partner to confirm tubal patency. IUI is a less expensive and more natural way to conceive.

Intracytoplasmic sperm injection (ICSI) is the treatment of choice for patients who have completed at least one year of therapy and exhibit sperm concentrations of $< 1 \times 10^6$ /mL or patients who have sperm concentrations $> 5 \times 10^6$ /mL but have failed to achieve impregnation after 20 months. In addition to male infertility, the reproductive potential of the female partner should also be investigated. It is common to find concomitant female infertility in these cases (22). Bakircioglu et al. evaluated 22 ICSI attempts with a pregnancy rate of 54.5% (22). Zorn et al. reported four men with HH who underwent 10 ICSI cycles after hormone treatment. This group achieved a 67% fertilization rate and a 30% pregnancy rate per cycle (23).

Until recently, remaining childless, adoption or sperm donation were the only options for HH patients with persistent azoospermia despite long periods of hormone therapy. For these patients, testicular sperm extraction (TESE) could be an excellent option to achieve a pregnancy (19,22). Some authors have published results with TESE in azoospermic men with HH; for example, Fahmy et al. used TESE to successfully recover spermatozoa in 11 out of 15 patients (73%) and, more recently, Akarsu et al. found sufficient spermatozoa for ICSI and cryopreservation for future cycles in all cases (19,24).

Assisted reproductive techniques (ART) are an important tool for achieving pregnancy in couples where the male partner has HH. Even couples who achieve spermatogenesis with hormonal therapy may not achieve pregnancy or may require extended periods to achieve pregnancy. This situation can cause low compliance, anxiety, and discomfort in the patients and can increase the financial burden (19). Evaluation of the female partner's fertility can save time for the couple, as can using ART to achieve a pregnancy as soon as possible.

■ EXPERT COMMENTARY

Conventionally, gonadotropin therapy in the form of human chorionic gonadotropin (hCG) alone or combined with human menopausal gonadotropin (hMG) or follicle-stimulating hormone (FSH) is indicated to restore spermatogenesis in HH men wishing to father a child. The glycoprotein hormones FSH, LH, hCG are composed of two non-covalently linked protein subunits: the alpha and beta subunits. The alpha subunits of the hormones are identical, whereas the beta subunits are distinct and confer the unique biological and immunological properties and receptor specificity of each of these glycoproteins (25). The beta subunit of LH contains the same amino acid sequence as the beta subunit of hCG, but the hCG beta subunit contains an additional 23 amino acids. The two hormones differ in the composition of their carbohydrate moieties,



which affect bioactivity and half-life. The half-life of LH is 20 minutes, whereas the half-life of hCG is 24 hours (26).

The history underpinning the development of gonadotropin therapy spans close to 100 years and provides an example of how basic research and technological advances have progressed to clinical application. Originally, gonadotropins were derived from animal (pregnant mare serum) or human (post-mortem pituitary gland) sources, but these preparations were abandoned because of safety concerns. The modern gonadotropin era started in the 1940s with the extraction of hCG and hMG from urine. Improvements in purification methods led to the production of urinary gonadotropins containing FSH only in the 1980s and 1990s. Advances in DNA technology in the end of the last century enabled the development of recombinant gonadotropins. Recombinant human chorionic gonadotropin (rec-hCG), FSH (rec-hFSH) and LH (rec-hLH), which have the advantage of being devoid of other gonadotropin hormones and contaminants of human origin, have become available, and the use of recombinant FSH combined with recombinant LH preparations in anovulatory women suffering from hypogonadotropic hypogonadism has shown to be an effective way to promote follicular development (27). However, data are limited on the effectiveness of these preparations to treat HH males.

In a recent study, the clinical efficacy, safety, and tolerability of recombinant human chorionic gonadotropin (rec-hCG) in restoring spermatogenesis and androgen status were assessed in a group of men with hypogonadotropic hypogonadism seeking fertility (28). Eleven men with adult-onset HH were treated with a single weekly subcutaneous (SC) injection of 250 mcg of recombinant hCG for a minimum of 12 weeks. The patients self-administered the rec-hCG with a ready-to-inject, prefilled syringe. In this study, the causes of secondary HH were pituitary tumor, long-term exogenous steroid use that did not respond to discontinuation, and cranioccephalic trauma. All of the patients presented with clinical signs of hypoandrogenism and were azoospermic. The testis histopathology results (available for six patients) revealed peritubular fibrosis and maturation arrest. The mean \pm SD baseline (pretreatment) hormone levels were as follows: FSH = 0.46 ± 0.28 mUI/mL, LH = 0.39 ± 0.32 mUI/mL, and total testosterone = 41.3 ± 26.9 ng/dL. All but one of the patients (with a history of cryptorchidism) exhibited restored spermatogenesis after a mean treatment duration of 12 weeks. The average total motile sperm count was 39×10^6 (range $0.0\text{--}156.9 \times 10^6$) at the 12th treatment week. Two unassisted pregnancies and one assisted (via in vitro fertilization-ICSI) pregnancy were obtained during the follow-up period of five months. The mean \pm SD testosterone levels were 647.5 ± 219.0 ng/dL at the completion of treatment. Marked improvements in virilization, libido and erectile function were also observed after treatment, and the mean combined testis volume increased from 24 mL before treatment to 33 mL after treatment. Headache, gynecomastia, and increased estradiol levels were observed in one man who did not recover spermatogenesis. All of the patients reported subcutaneous hCG self-administration with minimal to no local side effects and/or discomfort. In this study, a single weekly injection of rec-hCG effectively restored spermatogenesis and androgen production in most adult-onset HH males. In light of the favorable efficacy, safety, and tolerability profile of rec-hCG, this treatment may be

considered an alternative to intramuscularly injected, urinary-derived hCG for HH men seeking fertility and normal androgenic status.

Because of the cost, gonadotropin treatment for fertility restoration should be used until pregnancy is achieved. Ideally, the medication should be continued until the beginning of the second trimester, after which the risk of miscarriage is low (5). It is also advisable to offer sperm cryopreservation to such patients as an option for preserving future fertility.

Classically, the duration of gonadotropin treatment for restoring spermatogenesis is greater than three months. Older studies estimated the duration of spermatogenesis (from the differentiation of pale spermatogonia to the ejaculation of mature spermatozoa) to be approximately 74 days (29). This concept was recently challenged by Misell et al. (2006), who showed that the appearance of new sperm in the semen occurred after a mean duration of 64 days. In their study, men with normal sperm concentrations ingested deuterated (heavy) water ($2\text{H}_2\text{O}$) daily and provided semen samples every two weeks for up to 90 days. The incorporation of the $2\text{H}_2\text{O}$ label into sperm DNA was quantified by gas chromatography/mass spectrometry, which allowed the percentage of new cells to be calculated. The mean overall time to the detection of labeled sperm in the ejaculate was 64 ± 8 days (range 42–76). Biological variability was also observed, which contradicts the current belief that the duration of spermatogenesis is fixed. All of the subjects exhibited more than 70% new sperm in the ejaculate by day 90, but plateau labeling was not attained in the majority of the subjects, which suggests the rapid washout of old sperm in the epididymal reservoir (30). These data also suggest that in normal men, the sperm released from the seminiferous epithelium enter the epididymis in a coordinated manner, with little mixing of old and new sperm before subsequent ejaculation. This information is useful as a counseling tool for doctors who rely on gonadotropin treatment for HH males, in the sense that monitoring using semen analysis can be tailored accordingly.

Assisted reproductive techniques can also be used for couples who are unable to attain an unassisted pregnancy. Intrauterine insemination (IUI) and in vitro fertilization (IVF) techniques are available, depending on the woman's potential for pregnancy and the quality and quantity of sperm. In cases where viable spermatozoa are not obtained by clinical treatment, they are likely to be obtained directly from the testes through testicular sperm extraction (TESE) or testicular microdissection as part of an in-vitro fertilization program with intracytoplasmic sperm injection (ICSI). These techniques should be applied before considering the use of donor sperm.

Contraception is advisable for cases where pregnancy is achieved, as spermatogenesis may continue after therapy stops (5). In up to 10% of cases, the patient exhibits a sustained sperm response and adequate serum testosterone levels even after the complete withdrawal of medication (9). This situation is called hypogonadotropic hypogonadism reversal. The mechanism underlying these cases has not been completely explained, but there appears to be neuronal plasticity in GnRH-producing cells. Sex steroid production is thought to be responsible for the net neuronal stimulus, which has been linked to the secretion of GnRH



to generate sustained reversal of hypogonadotropic hypogonadism (9).

■ KEY ISSUES

- Male hypogonadotropic hypogonadism (HH) is defined as the failure of the testes to produce androgens and sperm and is a consequence of congenital or acquired diseases that affect the hypothalamus and/or the pituitary gland.
- The signs and symptoms of HH vary according to age.
- Diagnosis requires the determination of serum follicle-stimulating hormone levels, luteinizing hormone levels and testosterone levels. MRI scans of the brain and sella should be considered.
- Androgen replacement therapy should not be used for the treatment of hypogonadotropic hypogonadal males desiring fertility.
- HH represents one of the rare conditions in which specific medical treatment can reverse infertility.
- The induction and maintenance of both spermatogenesis and androgen production are achieved by the exogenous administration of gonadotropins.

■ AUTHOR CONTRIBUTIONS

All the authors were involved in the drafting and revision of the manuscript.

■ REFERENCES

1. Layman LC. Hypogonadotropic hypogonadism. *Endocrinol Metab Clin North Am.* 2007;36(2):283-96, <http://dx.doi.org/10.1016/j.ecl.2007.03.010>.
2. Araujo AB, O'Donnell AB, Brambilla DJ, Simpson WB, Longcope C, Matsumoto AM, et al. Prevalence and incidence of androgen deficiency in middle-aged and older men: estimates from the Massachusetts Male Aging Study. *J Clin Endocrinol Metab.* 2004;89(12):5920-6, <http://dx.doi.org/10.1210/jc.2003-031719>.
3. Darby E, Anawalt BD. Male hypogonadism : an update on diagnosis and treatment. *Treat Endocrinol.* 2005;4(5):293-309, <http://dx.doi.org/10.2165/00024677-200504050-00003>.
4. Zitzmann M, Nieschlag E. Hormone substitution in male hypogonadism. *Mol Cell Endocrinol.* 2000;161(1-2):73-88, [http://dx.doi.org/10.1016/S0303-7207\(99\)00227-0](http://dx.doi.org/10.1016/S0303-7207(99)00227-0).
5. Han TS, Bouloux PM. What is the optimal therapy for young males with hypogonadotropic hypogonadism? *Clin Endocrinol (Oxf).* 2010;72(6):731-7.
6. Hayes FJ, Seminara SB, Crowley WF, Jr. Hypogonadotropic hypogonadism. *Endocrinol Metab Clin North Am.* 1998;27(4):739-63, vii, [http://dx.doi.org/10.1016/S0889-8529\(05\)70039-6](http://dx.doi.org/10.1016/S0889-8529(05)70039-6).
7. Bianco SD, Kaiser UB. The genetic and molecular basis of idiopathic hypogonadotropic hypogonadism. *Nat Rev Endocrinol.* 2009;5(10):569-76, <http://dx.doi.org/10.1038/nrendo.2009.177>.
8. Viswanathan V, Eugster EA. Etiology and treatment of hypogonadism in adolescents. *Pediatr Clin North Am.* 2011;58(5):1181-200, x, <http://dx.doi.org/10.1016/j.pcl.2011.07.009>.
9. Raivio T, Falardeau J, Dwyer A, Quinton R, Hayes FJ, Hughes VA, et al. Reversal of idiopathic hypogonadotropic hypogonadism. *N Engl J Med.* 2007;357(9):863-73.
10. Popa SM, Clifton DK, Steiner RA. The role of kisspeptins and GPR54 in the neuroendocrine regulation of reproduction. *Annu Rev Physiol.* 2008;70:213-38, <http://dx.doi.org/10.1146/annurev.physiol.70.113006.100540>.

11. Finkelstein JS, Whitcomb RW, O'Dea LS, Longcope C, Schoenfeld DA, Crowley WF, Jr. Sex steroid control of gonadotropin secretion in the human male. I. Effects of testosterone administration in normal and gonadotropin-releasing hormone-deficient men. *J Clin Endocrinol Metab.* 1991;73(3):609-20, <http://dx.doi.org/10.1210/jcem-73-3-609>.
12. Schwarting GA, Wierman ME, Tobet SA. Gonadotropin-releasing hormone neuronal migration. *Semin Reprod Med.* 2007;25(5):305-12, <http://dx.doi.org/10.1055/s-2007-984736>.
13. Ferris HA, Shupnik MA. Mechanisms for pulsatile regulation of the gonadotropin subunit genes by GnRH1. *Biol Reprod.* 2006;74(6):993-8, <http://dx.doi.org/10.1095/biolreprod.105.049049>.
14. Raivio T, Wikstrom AM, Dunkel L. Treatment of gonadotropin-deficient boys with recombinant human FSH: long-term observation and outcome. *Eur J Endocrinol.* 2007;156(1):105-11.
15. Matsumoto AM, Karpas AE, Bremner WJ. Chronic human chorionic gonadotropin administration in normal men: evidence that follicle-stimulating hormone is necessary for the maintenance of quantitatively normal spermatogenesis in man. *J Clin Endocrinol Metab.* 1986;62(6):1184-92, <http://dx.doi.org/10.1210/jcem-62-6-1184>.
16. Maffei L, Murata Y, Rochira V, Tubert G, Aranda C, Vazquez M, et al. Dysmetabolic syndrome in a man with a novel mutation of the aromatase gene: effects of testosterone, alendronate, and estradiol treatment. *J Clin Endocrinol Metab.* 2004;89(1):61-70, <http://dx.doi.org/10.1210/jc.2003-030313>.
17. Bouligand J, Ghervan C, Tello JA, Brailly-Tabard S, Salenave S, Chanson P, et al. Isolated familial hypogonadotropic hypogonadism and a GnRH1 mutation. *N Engl J Med.* 2009;360(26):2742-8.
18. Burriss AS, Rodbard HW, Winters SJ, Sherins RJ. Gonadotropin therapy in men with isolated hypogonadotropic hypogonadism: the response to human chorionic gonadotropin is predicted by initial testicular size. *J Clin Endocrinol Metab.* 1988;66(6):1144-51, <http://dx.doi.org/10.1210/jcem-66-6-1144>.
19. Akarsu C, Caglar G, Vicdan K, Isik AZ, Tuncay G. Pregnancies achieved by testicular sperm recovery in male hypogonadotropic hypogonadism with persistent azoospermia. *Reprod Biomed Online.* 2009;18(4):455-9, [http://dx.doi.org/10.1016/S1472-6483\(10\)60119-8](http://dx.doi.org/10.1016/S1472-6483(10)60119-8).
20. De Leo V, Musacchio MC, Di Sabatino A, Tosti C, Morgante G, Petraglia F. Present and future of recombinant gonadotropins in reproductive medicine. *Curr Pharm Biotechnol.* 2012;13(3):379-91, <http://dx.doi.org/10.2174/138920112799361918>.
21. Resorlu B, Abdulmajed MI, Kara C, Unsal A, Aydos K. Is intracytoplasmic sperm injection essential for the treatment of hypogonadotropic hypogonadism? A comparison between idiopathic and secondary hypogonadotropic hypogonadism. *Hum Fertil (Camb).* 2009;12(4):204-8, <http://dx.doi.org/10.3109/14647270903331139>.
22. Bakircioglu ME, Erden HF, Ciray HN, Bayazit N, Bahceci M. Gonadotropin therapy in combination with ICSI in men with hypogonadotropic hypogonadism. *Reprod Biomed Online.* 2007;15(2):156-60, [http://dx.doi.org/10.1016/S1472-6483\(10\)60703-1](http://dx.doi.org/10.1016/S1472-6483(10)60703-1).
23. Zorn B, Pfeifer M, Virant-Klun I, Meden-Vrtovc H. Intracytoplasmic sperm injection as a complement to gonadotrophin treatment in infertile men with hypogonadotropic hypogonadism. *Int J Androl.* 2005;28(4):202-7.
24. Fahmy I, Kamal A, Shamloul R, Mansour R, Serour G, Aboulghar M. ICSI using testicular sperm in male hypogonadotropic hypogonadism unresponsive to gonadotrophin therapy. *Hum Reprod.* 2004;19(7):1558-61, <http://dx.doi.org/10.1093/humrep/deh243>.
25. Vaitukaitis JL, Ross GT, Braunstein GD, Rayford PL. Gonadotropins and their subunits: basic and clinical studies. *Recent Prog Horm Res.* 1976;32:289-331.
26. Gonadotropin preparations: past, present, and future perspectives. *Fertil Steril.* 2008;90(5 Suppl):S13-20.
27. Bosch E. Recombinant human follicular stimulating hormone and recombinant human luteinizing hormone in a 2:1 ratio combination. Pharmacological characteristics and clinical applications. *Expert Opin Biol Ther.* 2010;10(6):1001-9, <http://dx.doi.org/10.1517/14712598.2010.485607>.
28. Esteves S, Papanikolaou V. Clinical Efficacy, Safety and Tolerability of Recombinant hCG to Restore Spermatogenesis and Androgenic Status of Hypogonadotropic Hypogonadism Males. *Fertil Steril.* 2011;96(3):S230, <http://dx.doi.org/10.1016/j.fertnstert.2011.07.884>.
29. Amann RP. The cycle of the seminiferous epithelium in humans: a need to revisit? *J Androl.* 2008;29(5):469-87.
30. Misell LM, Holochwost D, Boban D, Santi N, Shefi S, Hellerstein MK, et al. A stable isotope-mass spectrometric method for measuring human spermatogenesis kinetics in vivo. *J Urol.* 2006;175(1):242-6; discussion 6.